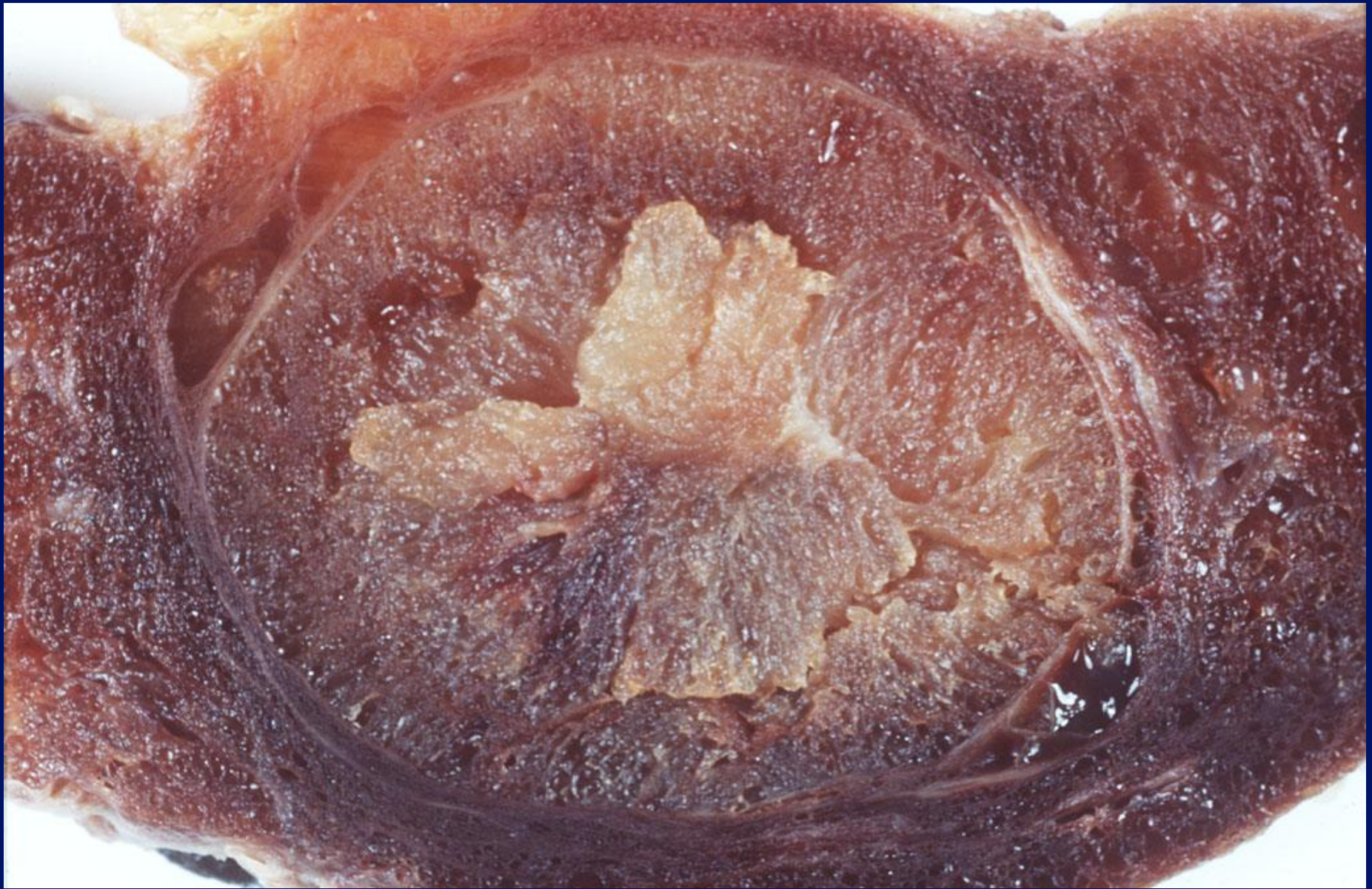


# Thyroid & Salivary glands.

[www.headandneckultrasound.co.uk](http://www.headandneckultrasound.co.uk)

Rhodri M Evans



# Incidence of nodules.

- 3 – 7% have palpable nodule
- 30 –70% have nodules detected on Ultrasound

x 10 Increase in incidence of nodules with Ultrasound .

Incidence

# Thyroid Nodules

70

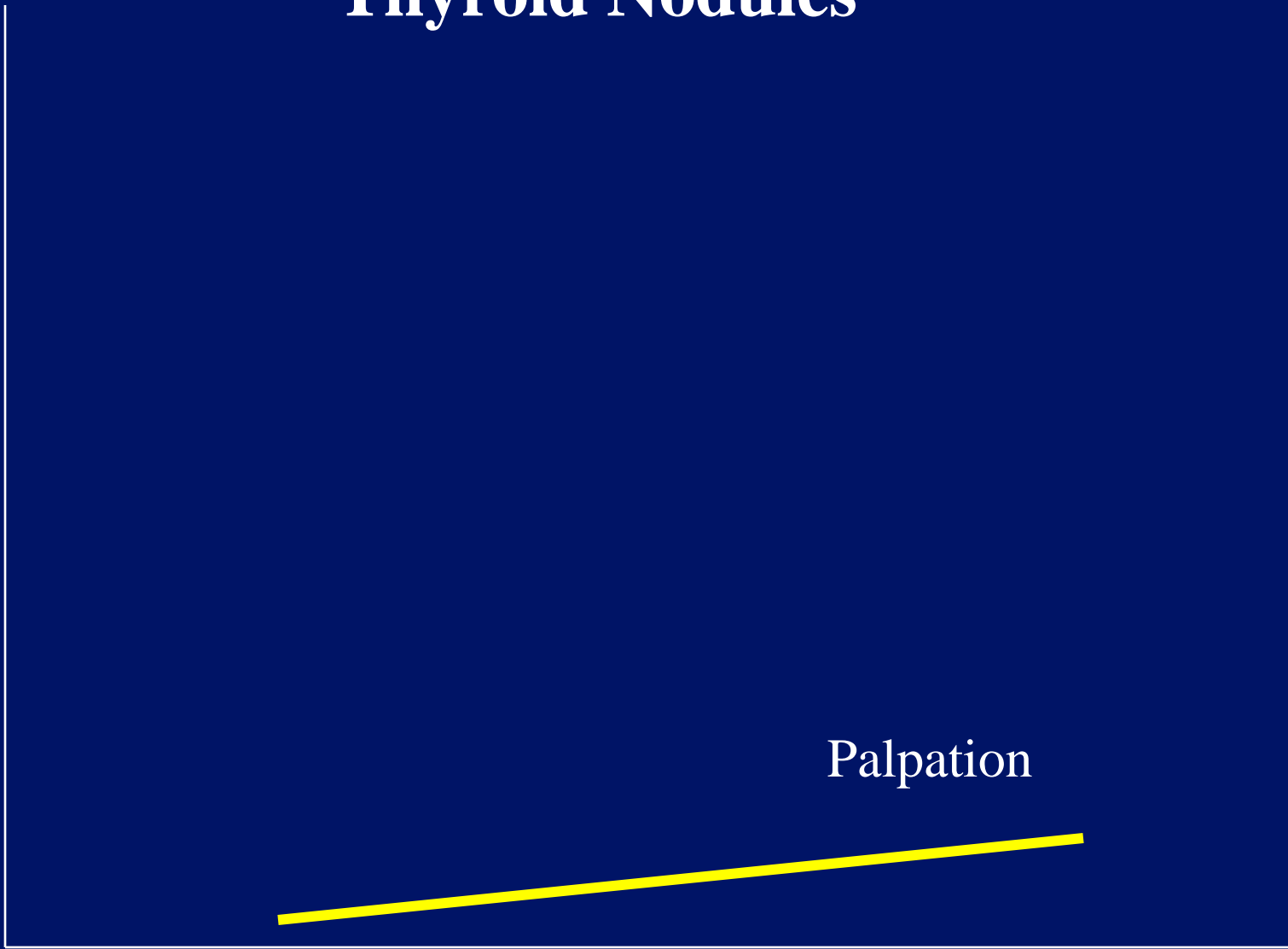
30

Palpation

50

Age

100



Incidence

# Thyroid Nodules

70

30

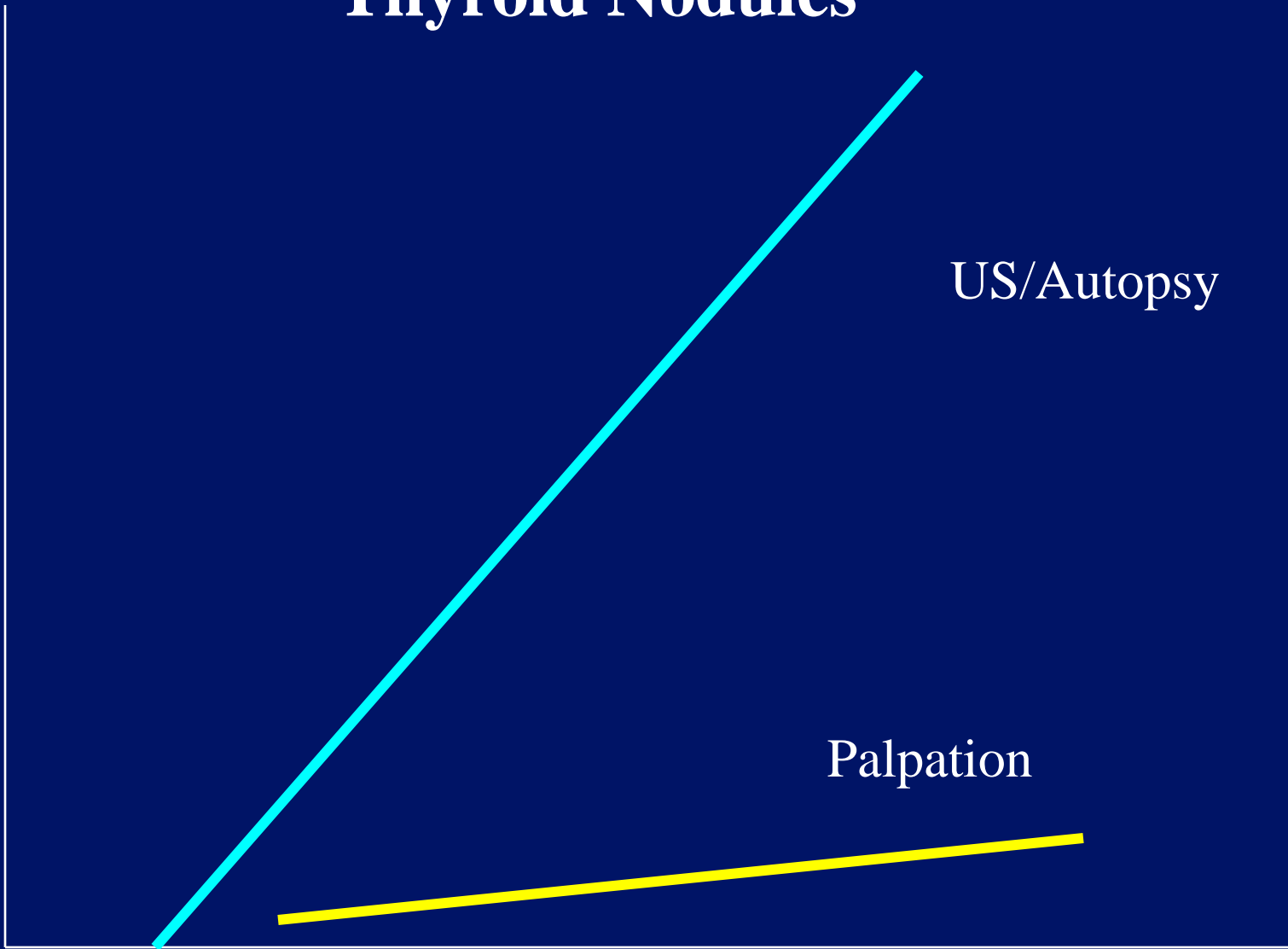
US/Autopsy

Palpation

50

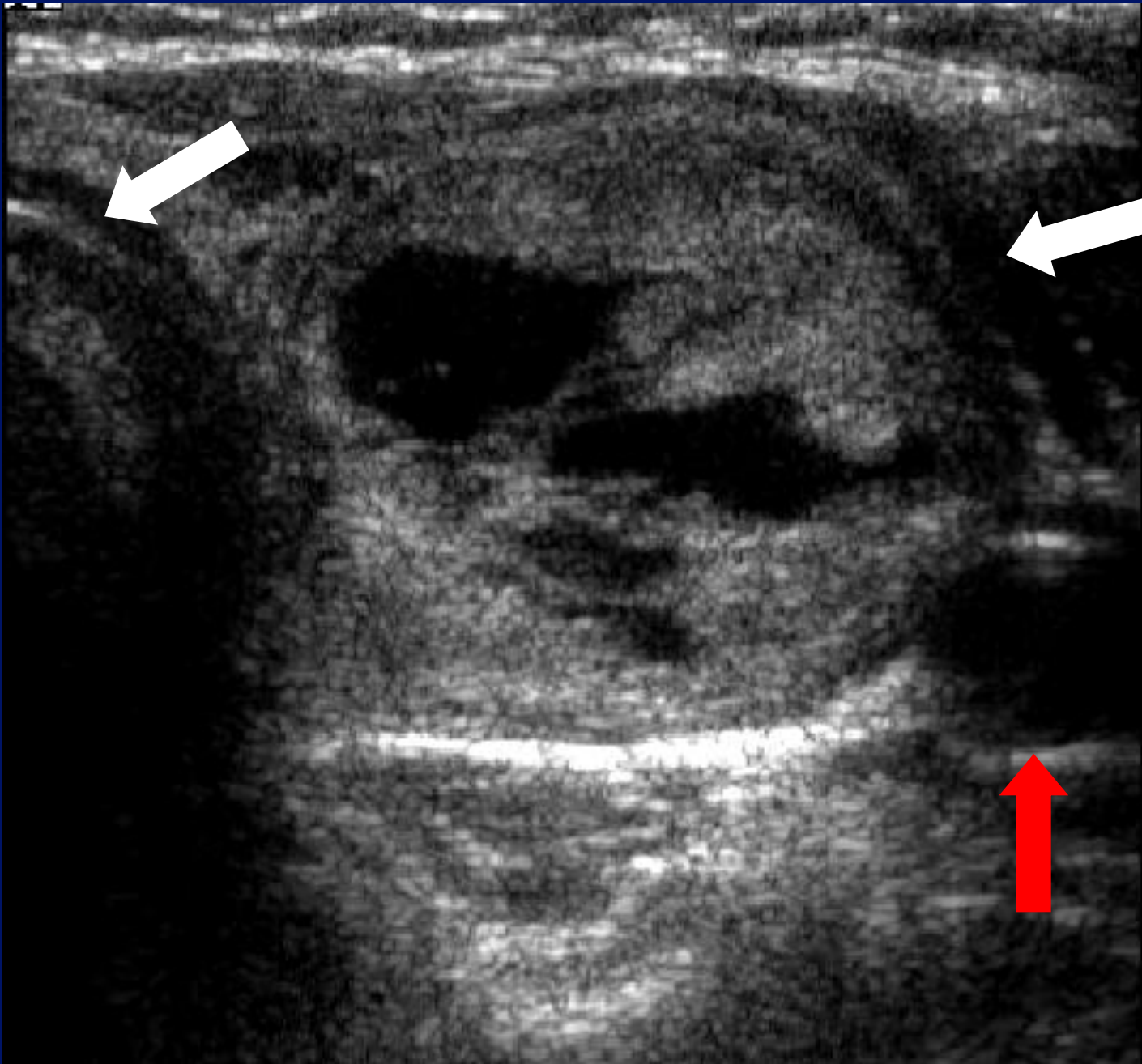
Age

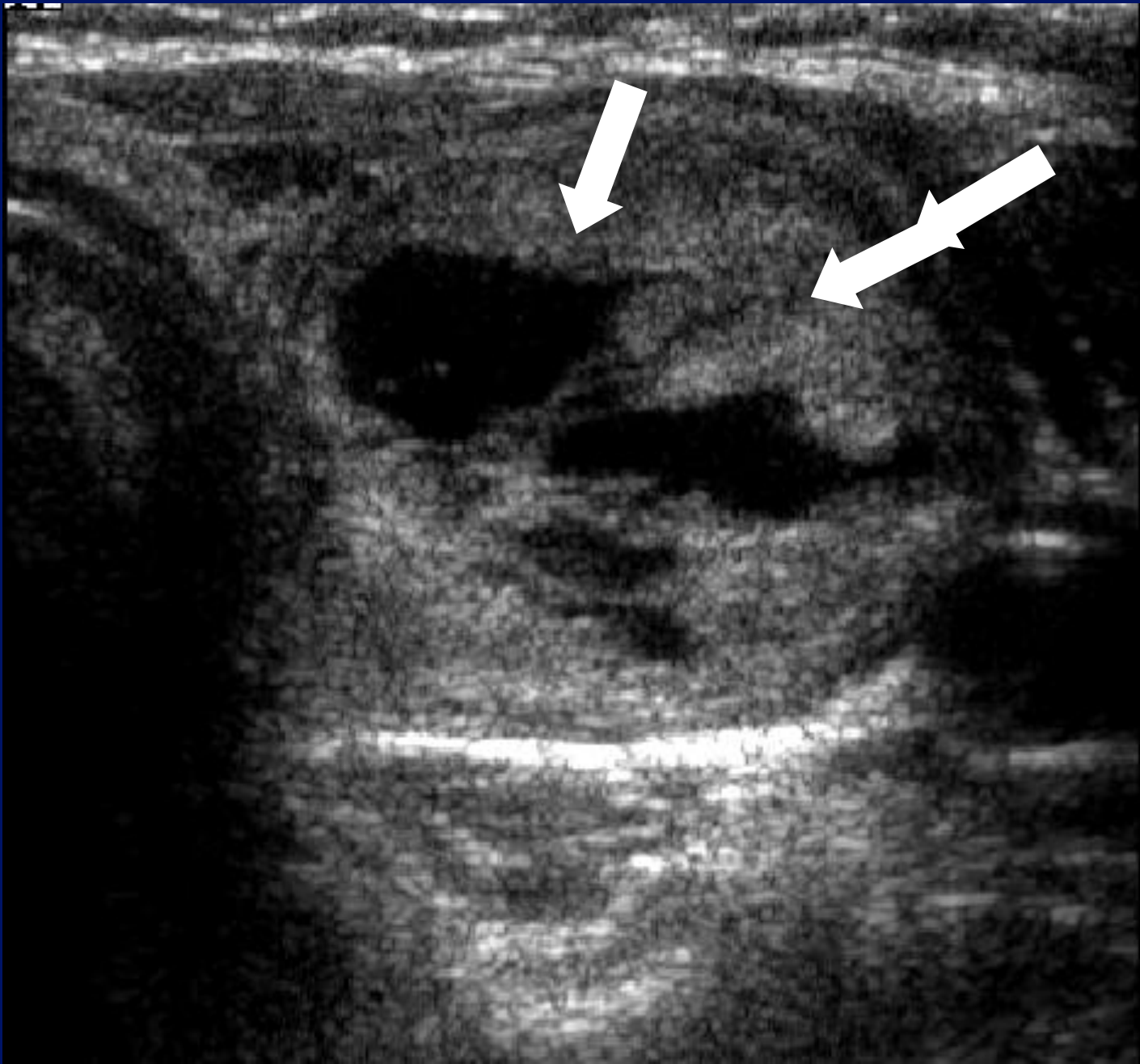
100



# Incidence of malignancy?

- 1000 new cases per annum in England and Wales ( 0.002%)
- 1 new case per 50,000 , per year.
- 250,000 population = 5 new cases/year
- 500,000 population=10 new cases/year.

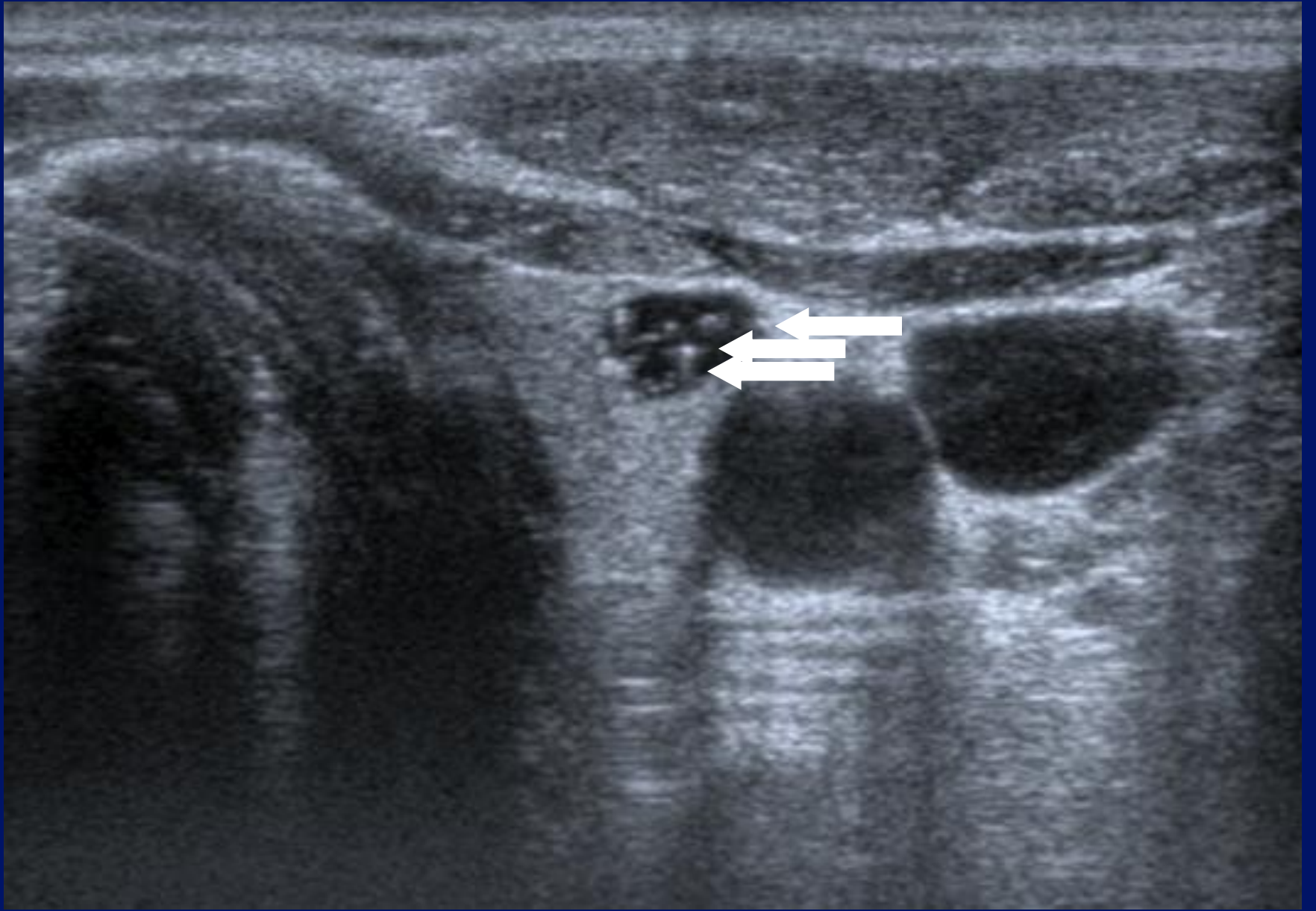




# Signs?

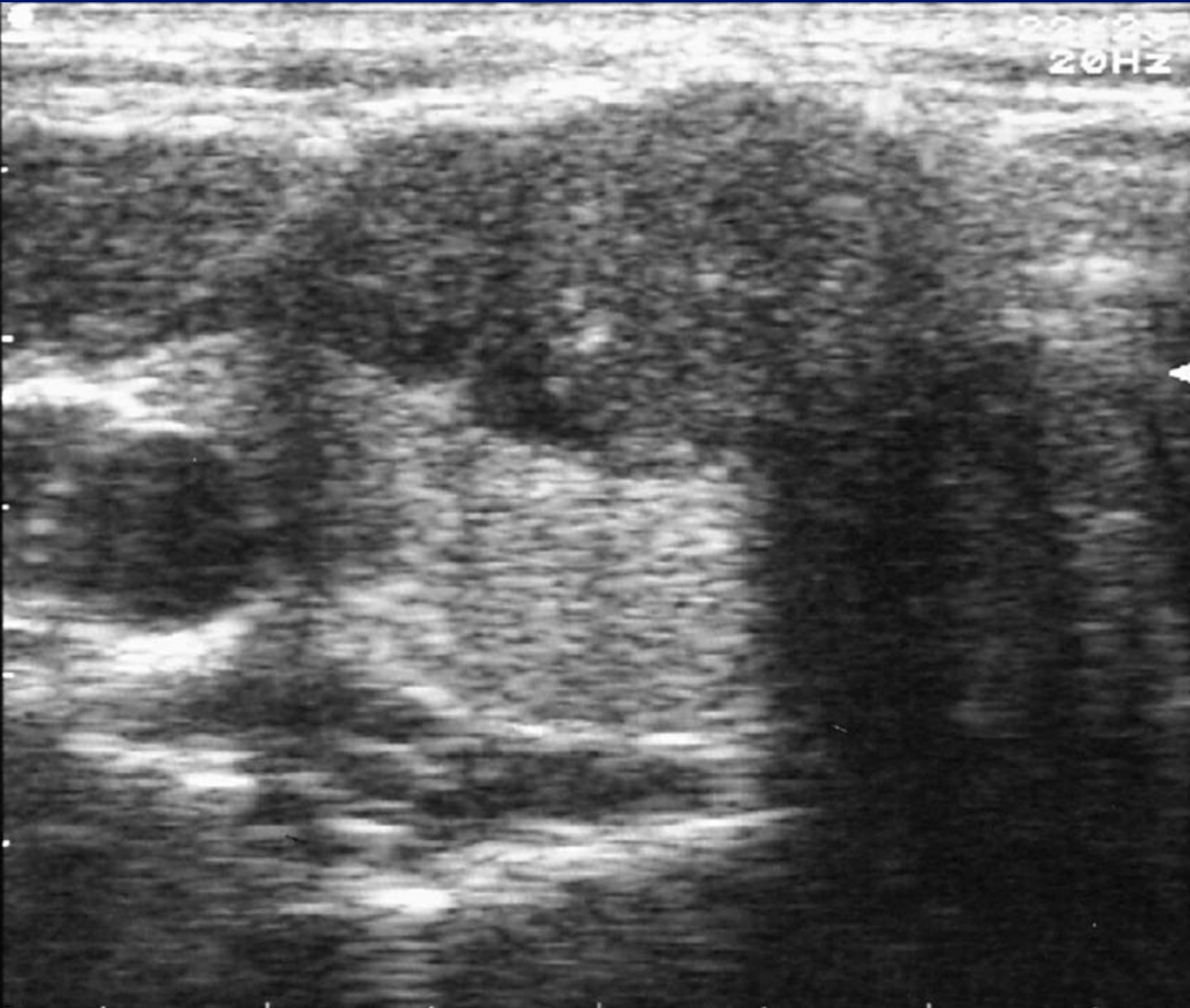
- 426 resected nodules, surgical correlation
- Benign nodules :iso/hyper-echoic and contain cystic degenerative change with a perinodular hypoechoic rim

Brkljacic et al, J Clin US;22:71-76.1995.



2012  
20HZ

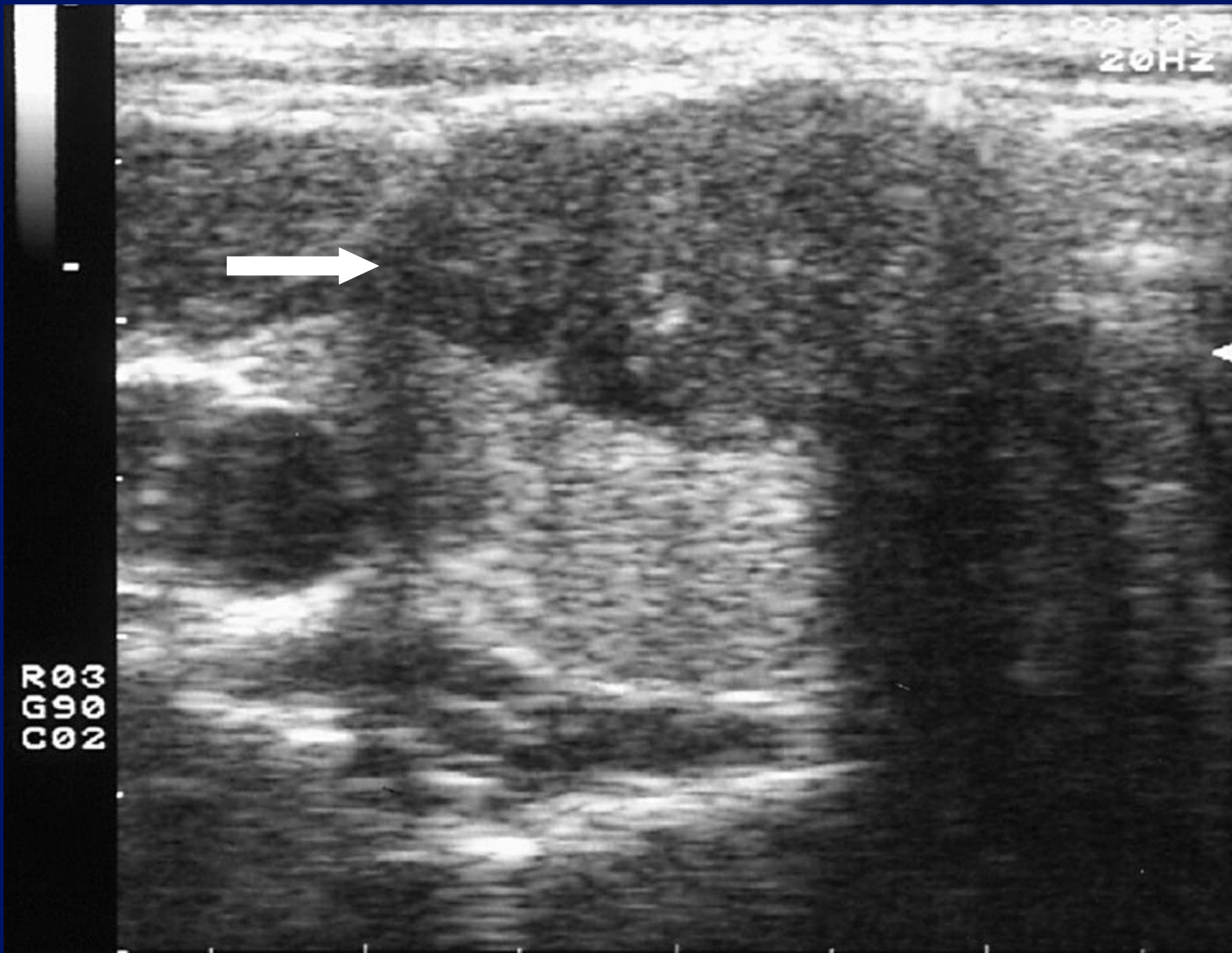
CGR  
03  
09  
02



20123  
20HZ



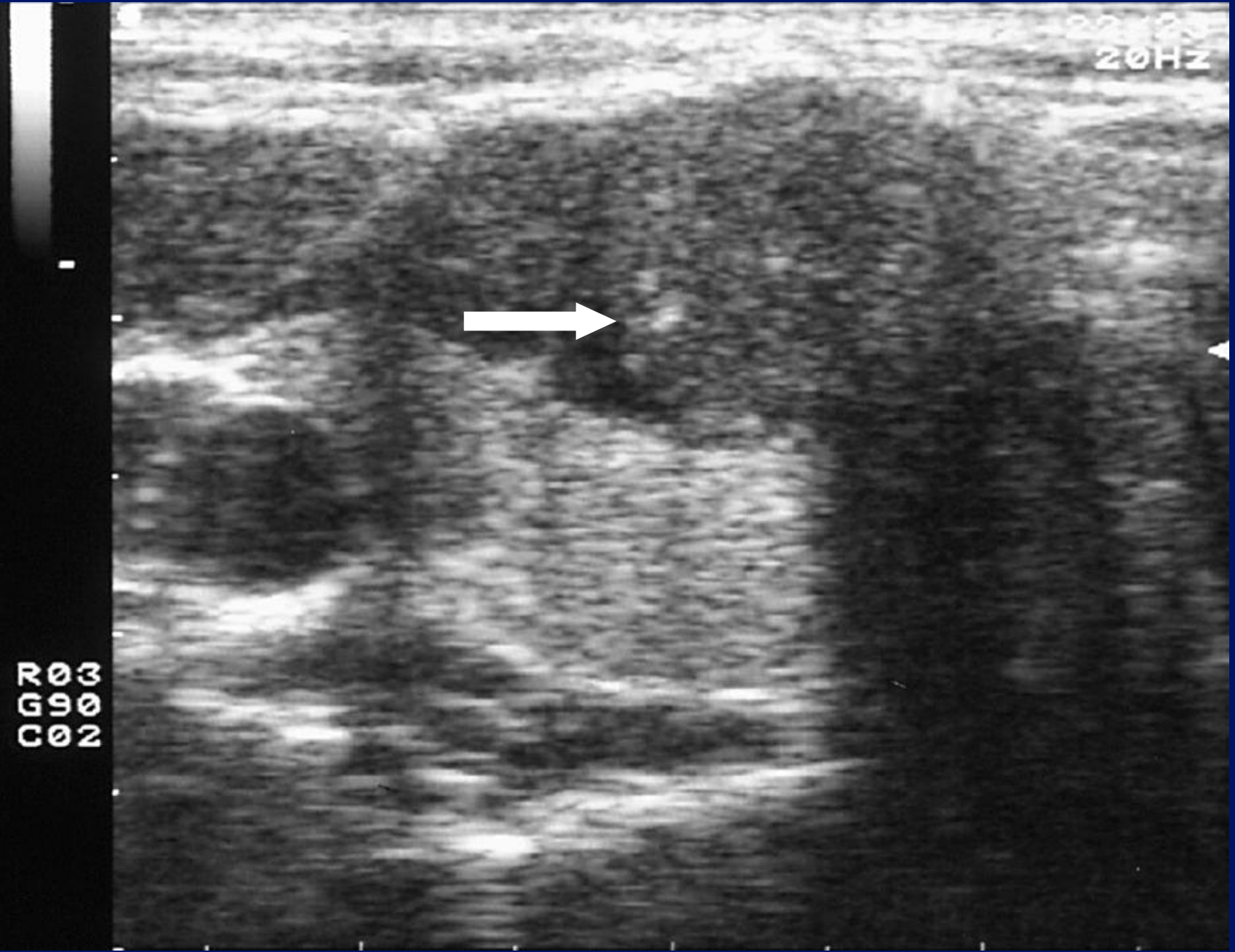
CGR03  
C990  
C02

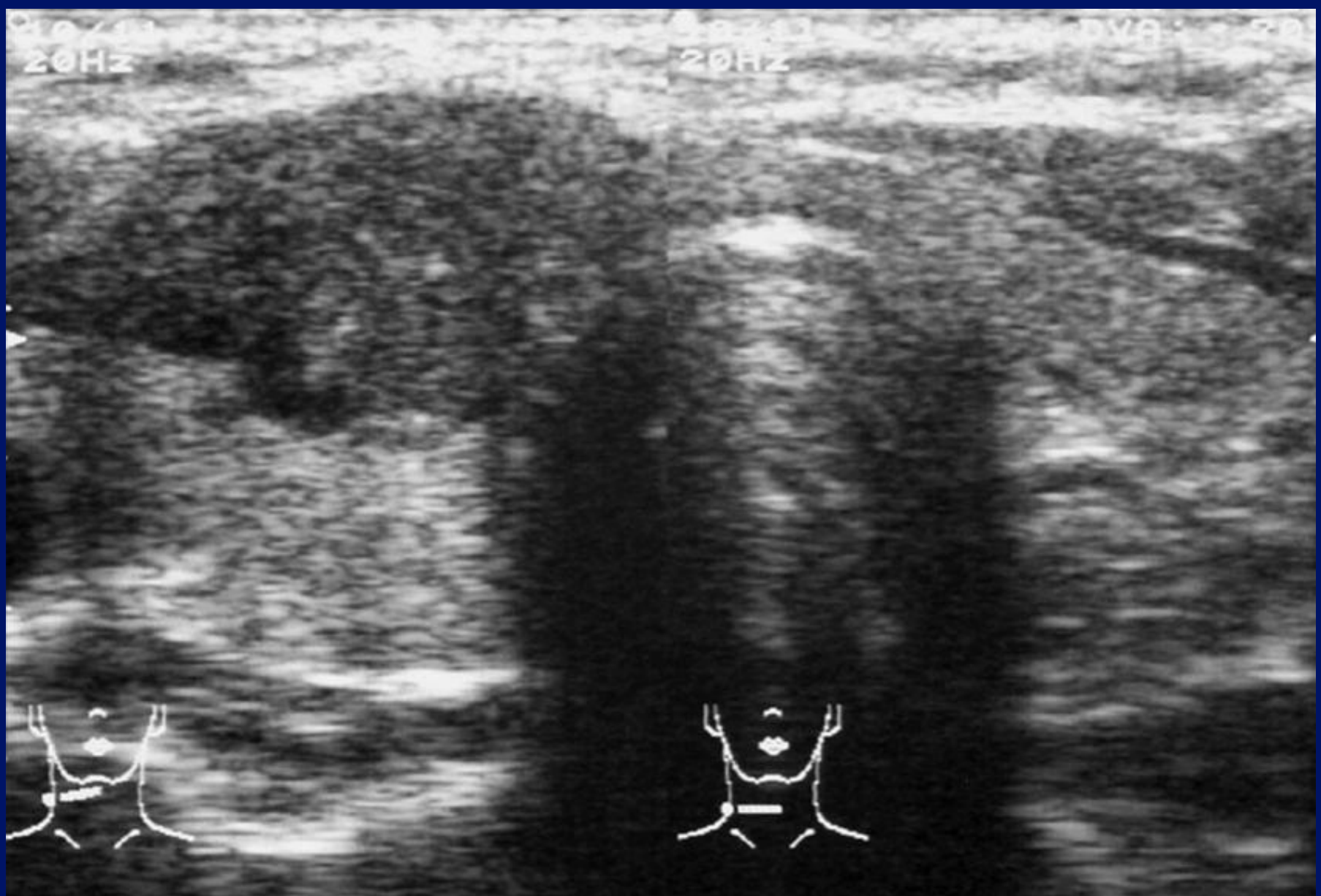

20123  
20HZ



CGR  
03  
090  
02

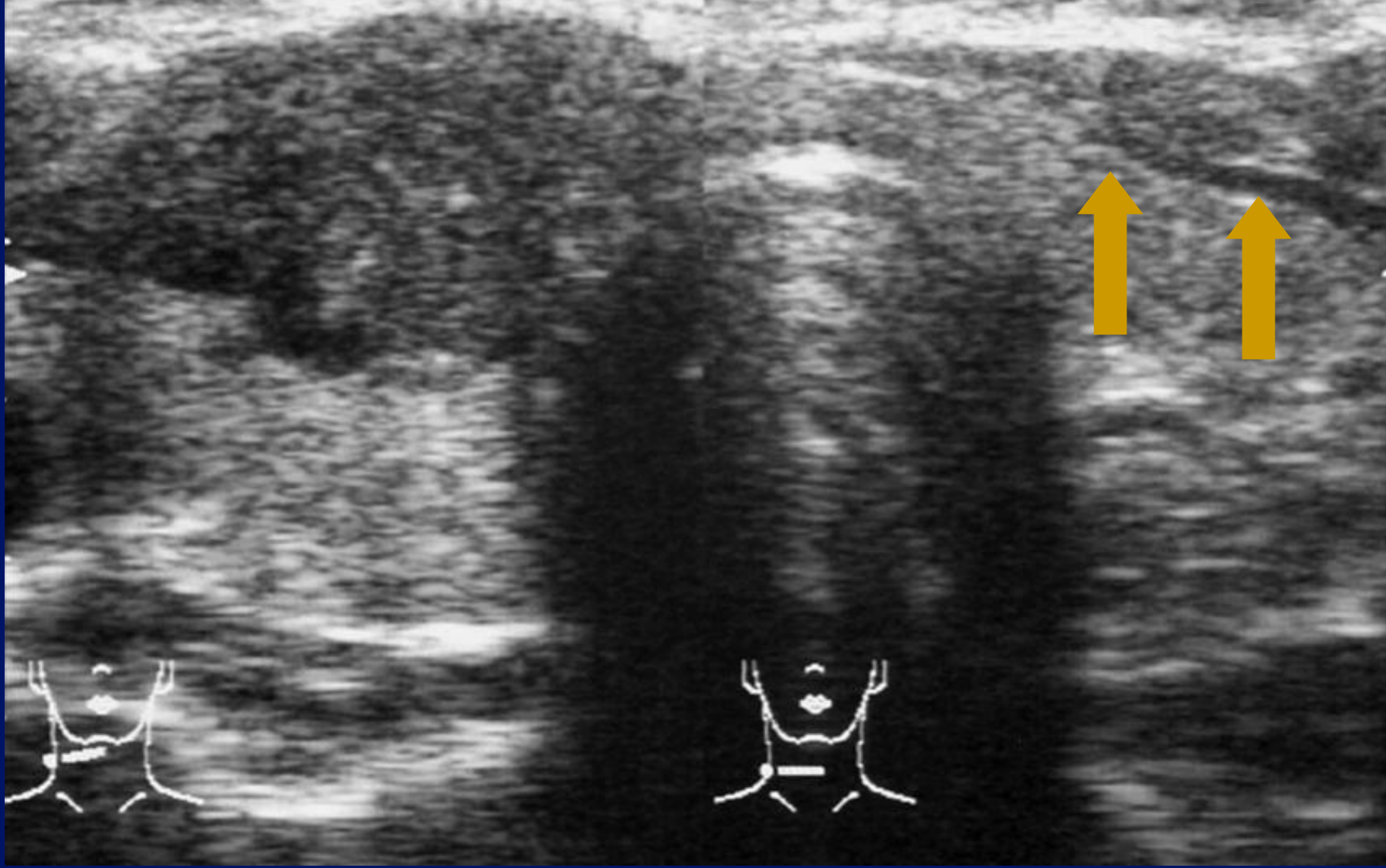


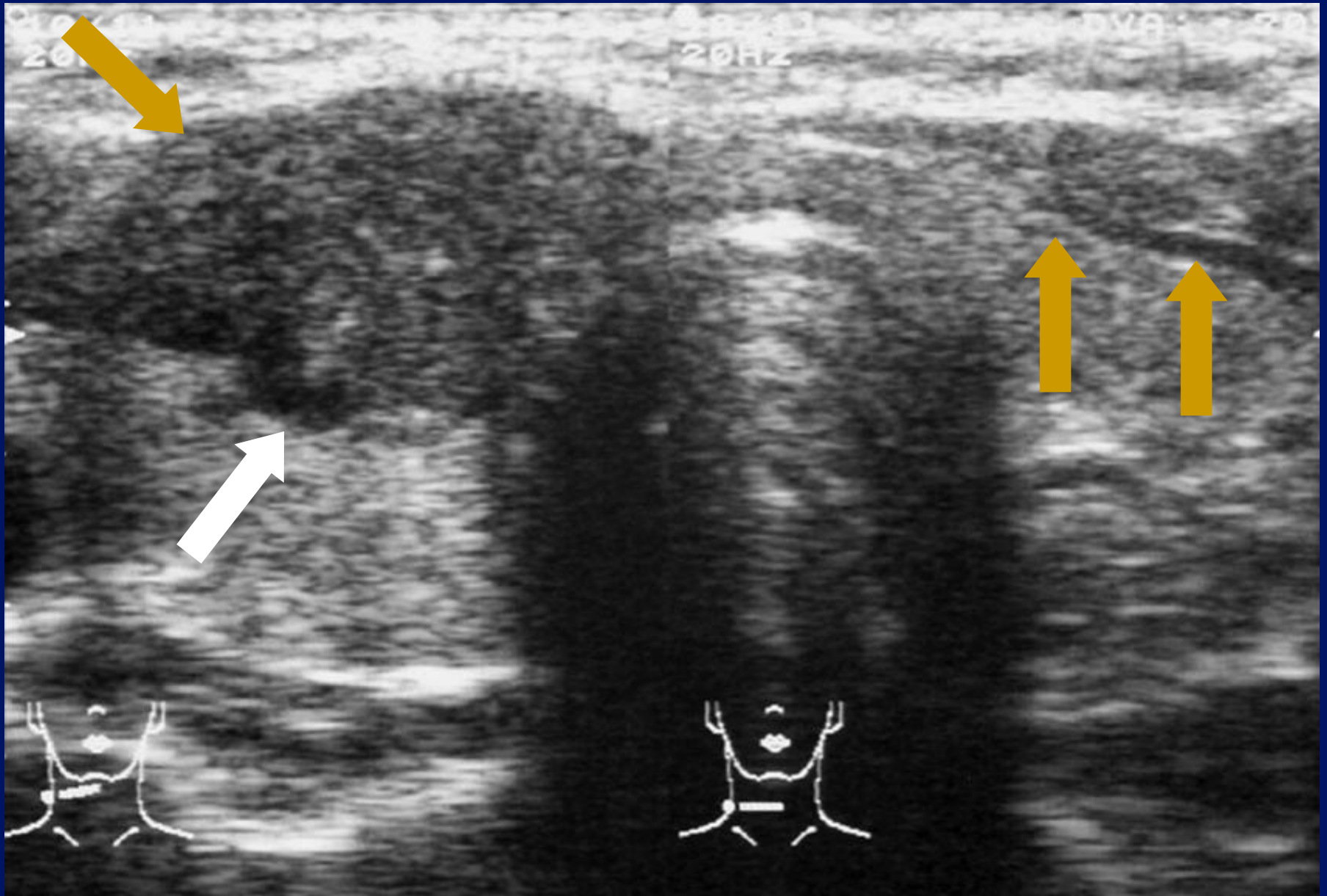
30/4/13  
20Hz

30/4/13  
20Hz

DVA 20





# Incidence of Papillary carcinoma?

- 6,499 patients:US and FNAC
- 164 cases( incidence : 2.52%) of malignancy :

116 Papillary Ca

23 Follicular Ca

6 Medullary Ca

7 Anaplastic Ca

8 Hurthle Cell Ca

4 Lymphomas

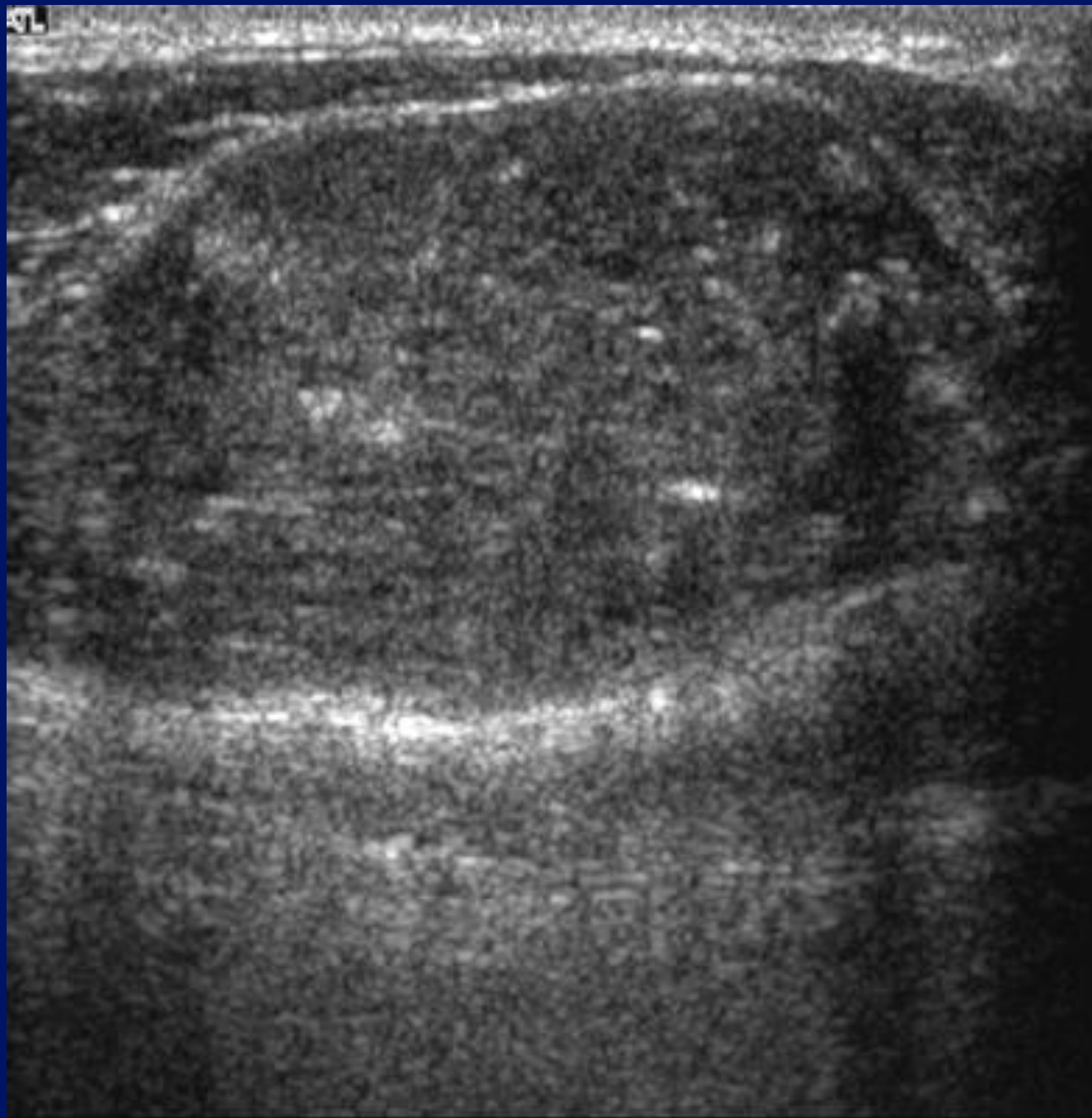
Lin et al,Acta

Cytol,1997;41:687-691.

# Occult Incidence.

- Autopsy series.
- Small (less than 1cm) papillary tumours :  
“micro-carcinomas”.
- Reported incidence : 10-30%.

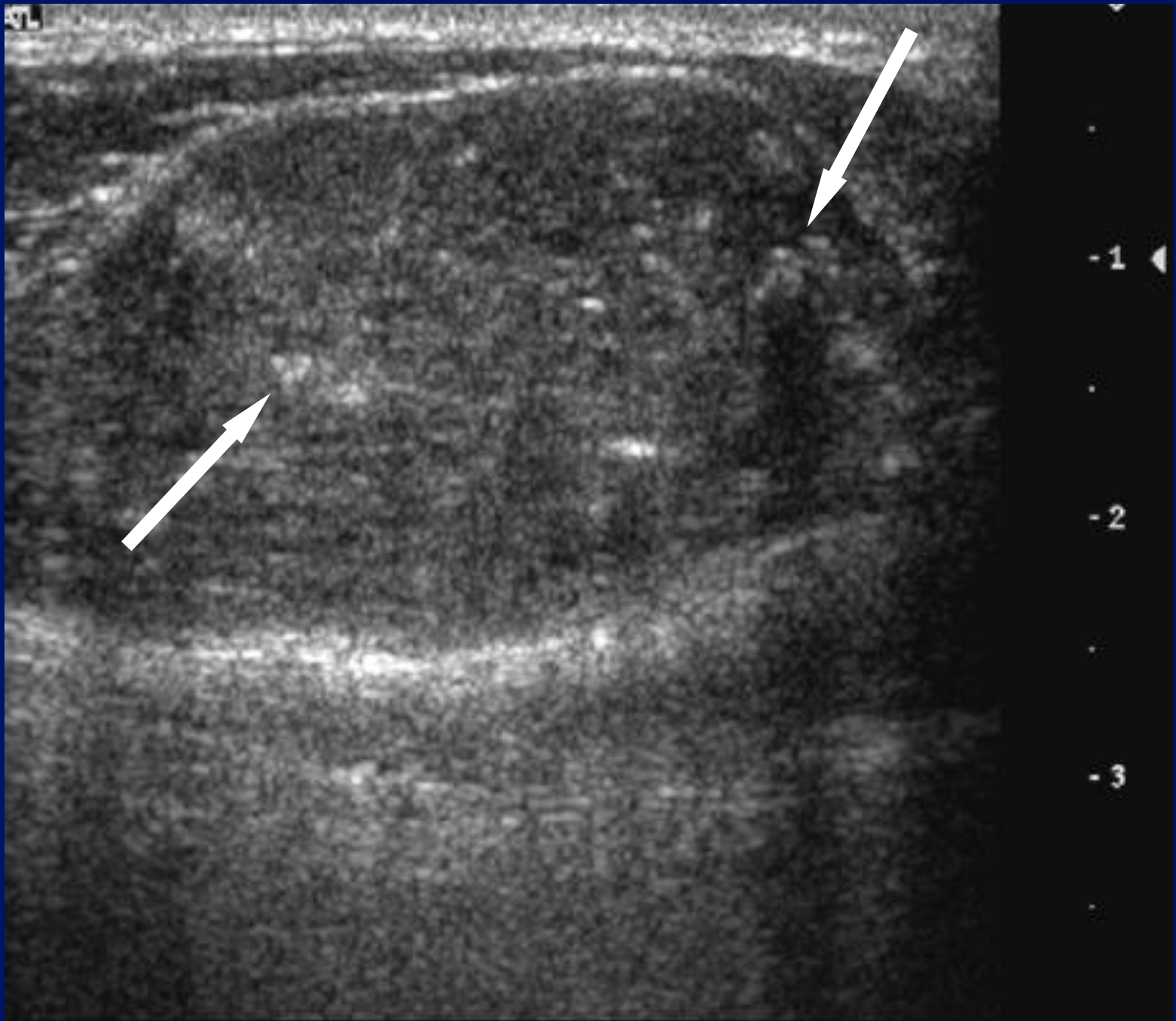
5L



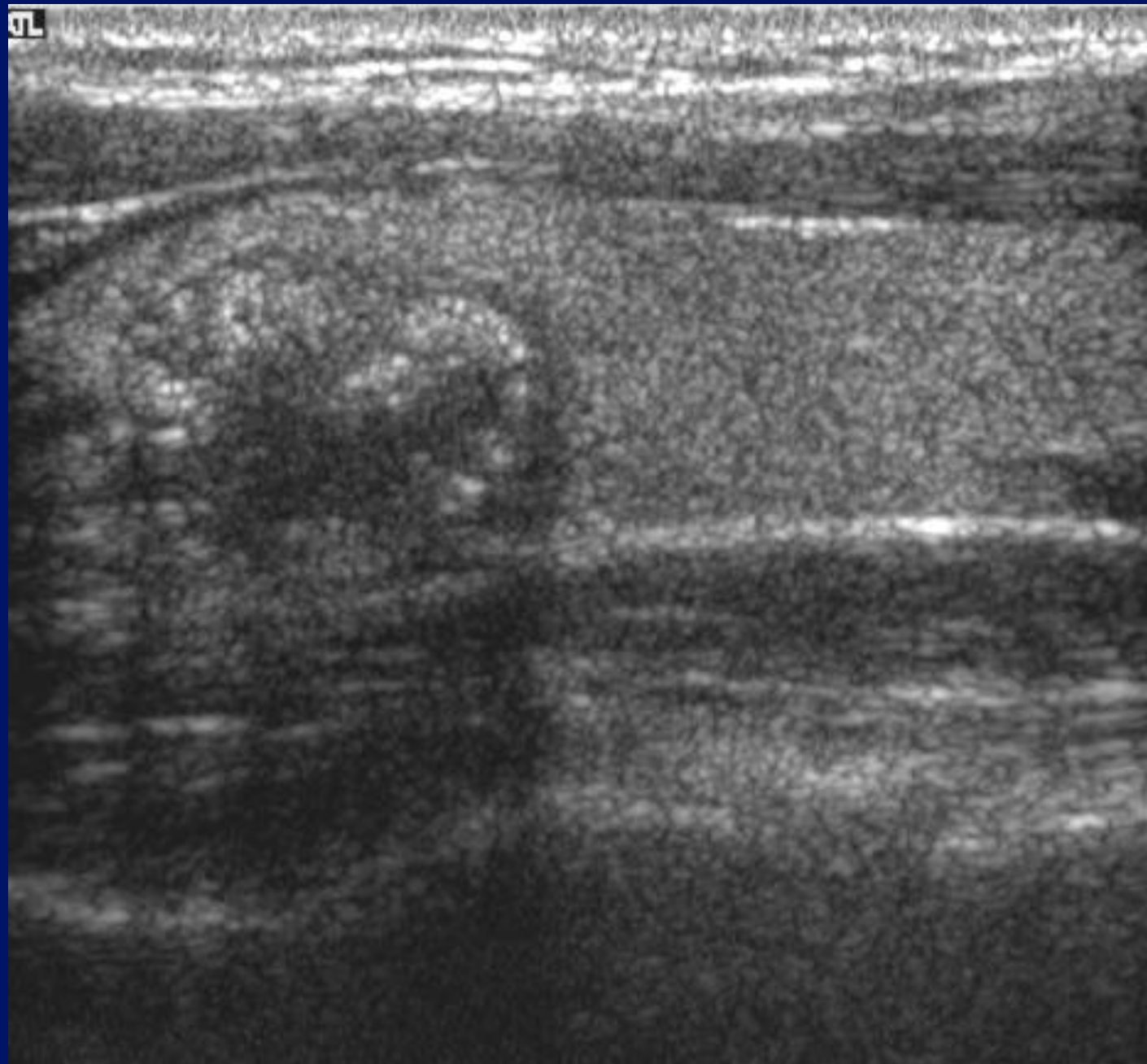
-1

-2

-3



5

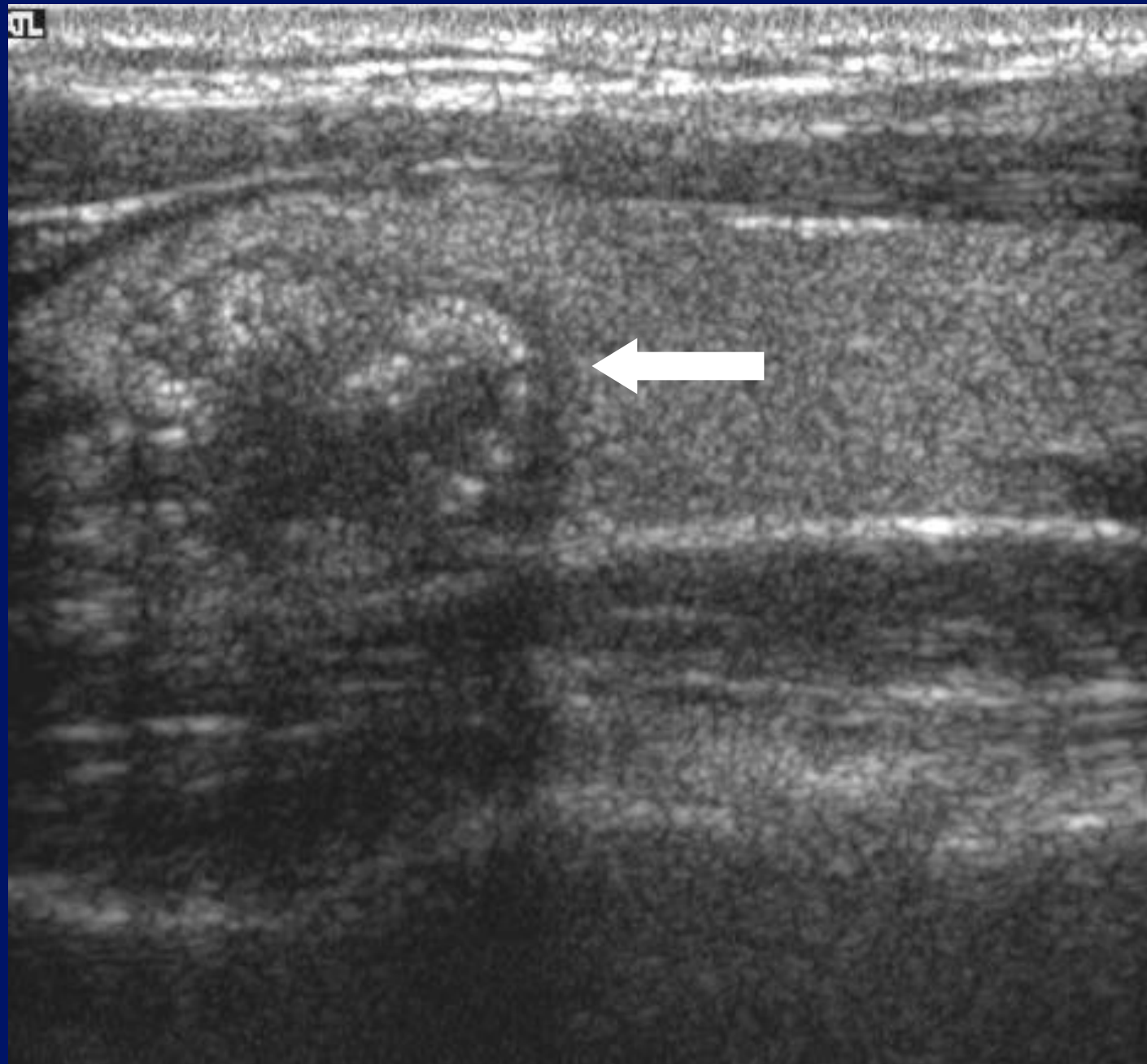


-1 ◀

-2

-3

5



-1 ◀

-2

-3

# Signs: papillary carcinoma?

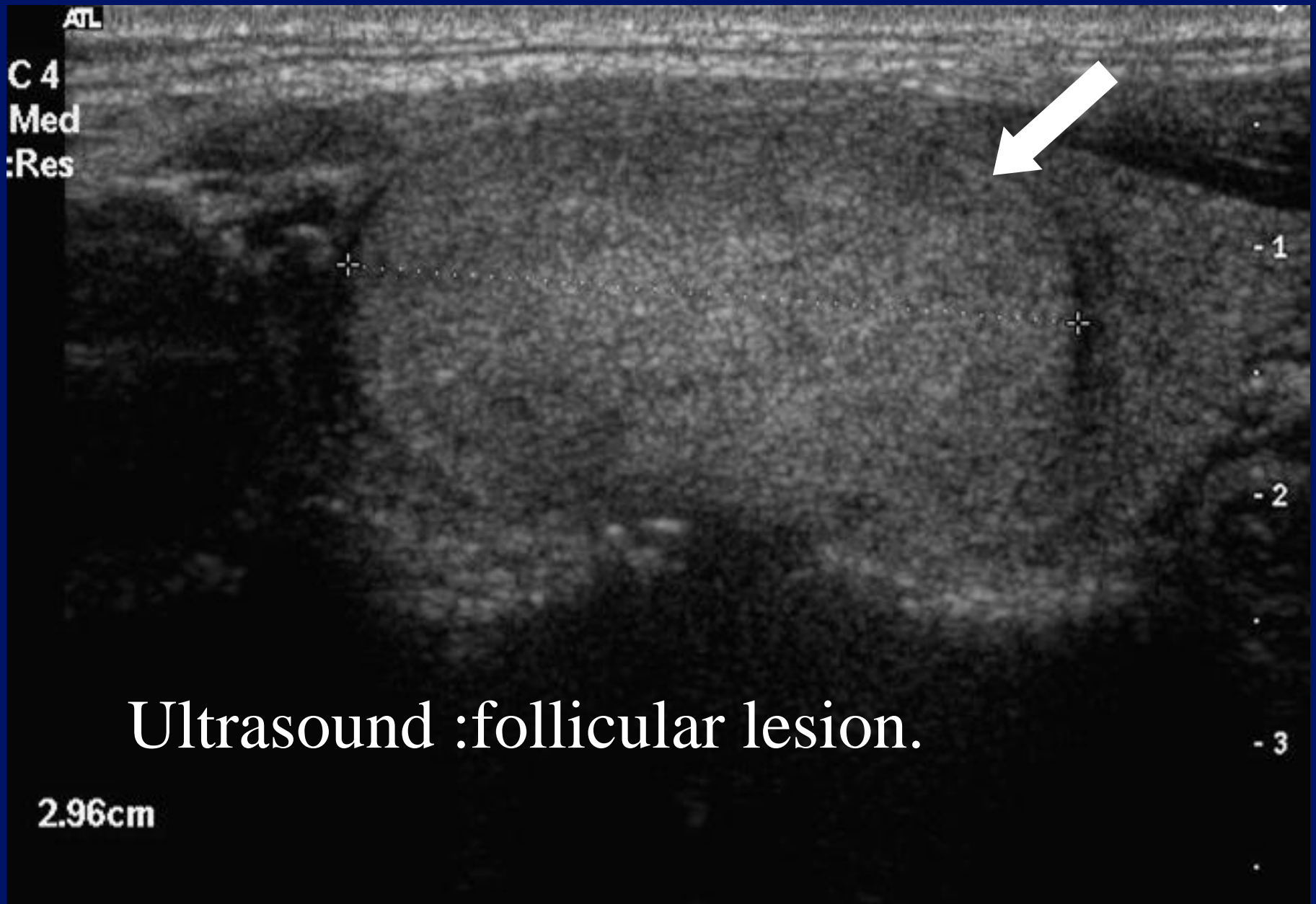- Combination of absent halo, microcalcification and type III (marked intranodular flow) most specific
- Specificity: 97.2%
- Sensitivity: 16.6%

Rago et al, Eur J  
Endocrinol., 1998; 138, 41-46

Follicular carcinoma.

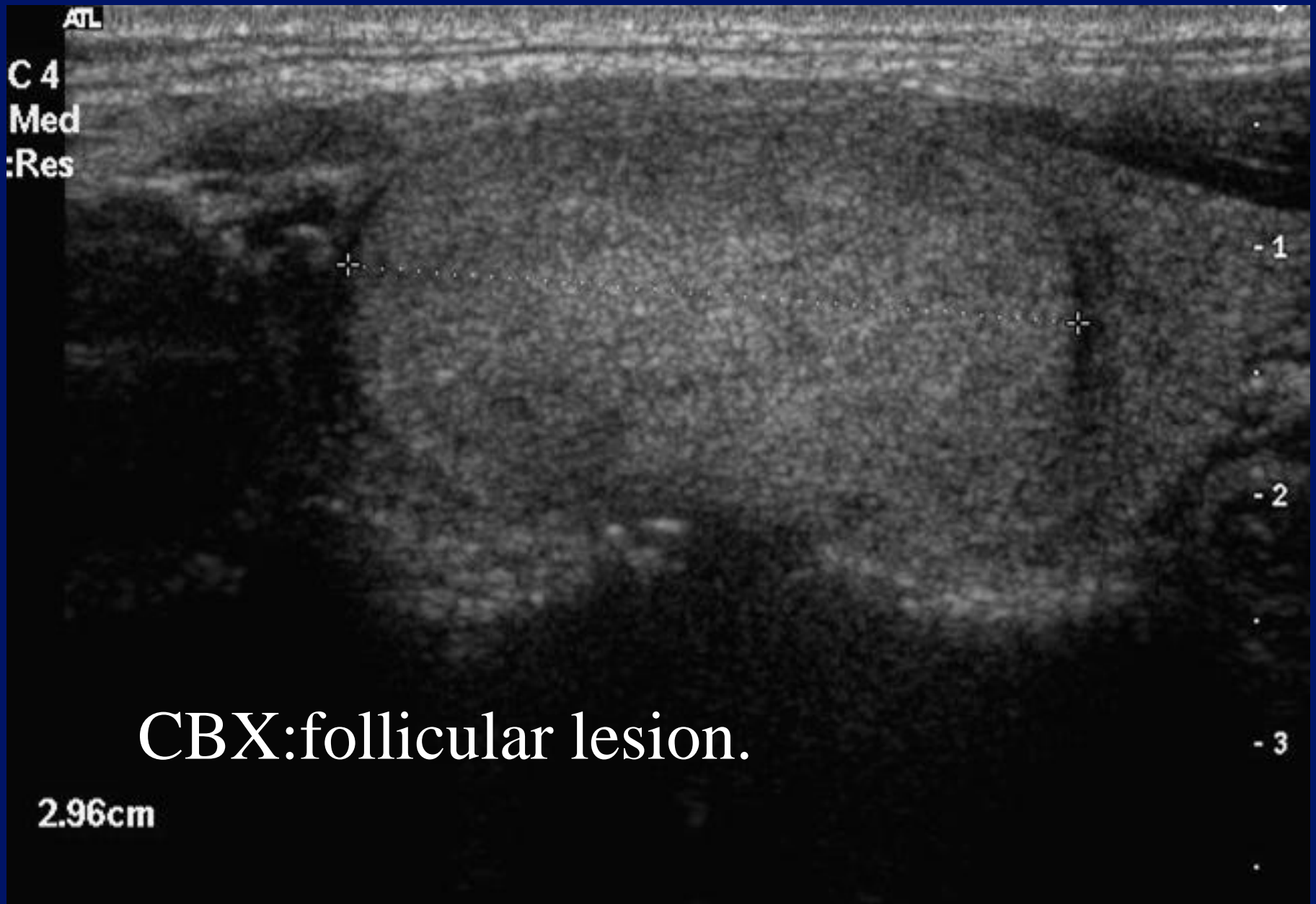
# Follicular lesions.

- Spectrum from adenoma to carcinoma.
- 80% will be benign
- Follicular carcinoma – 10-15% of all thyroid Ca.
- Cytology of no use.
- Histology of no use in differentiation.
- Surgical specimen : vascular and capsular invasion – follicular carcinoma.



Ultrasound :follicular lesion.

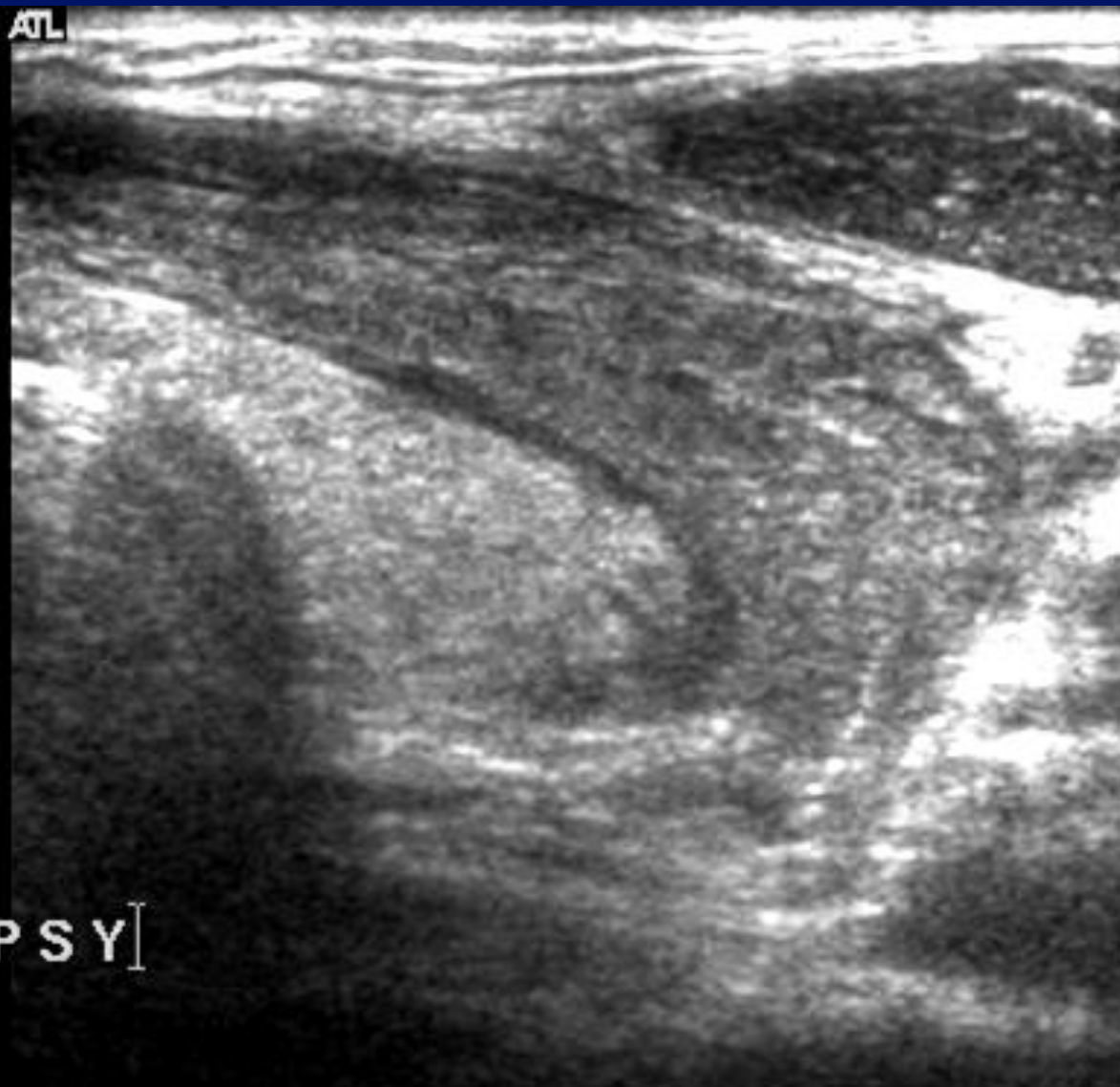2.96cm



CBX:follicular lesion.

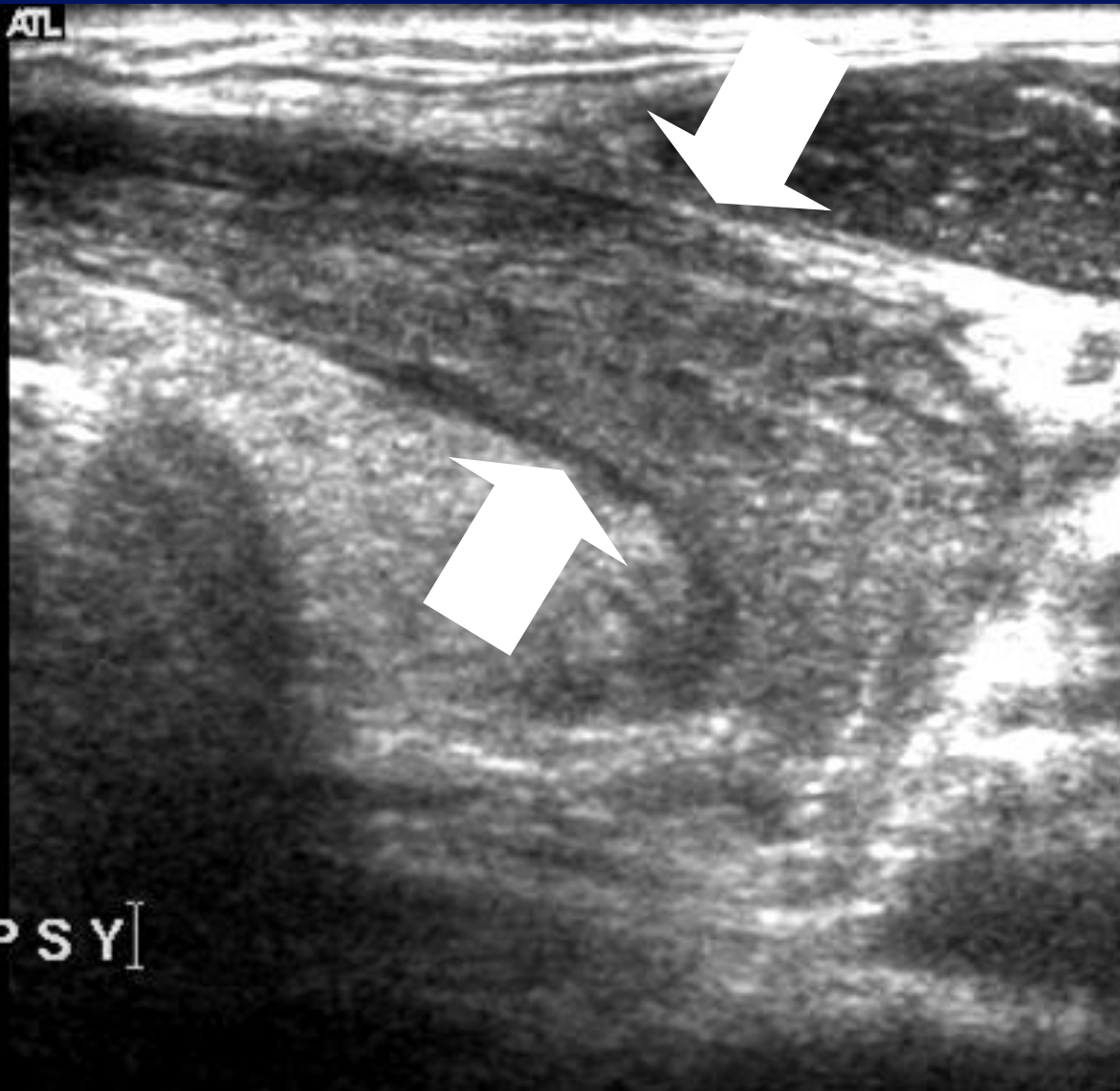
2.96cm

Map 3  
170dB/C 2  
Persist Off  
2D Opt:FSCT  
Fr Rate:Surv  
SonoCT™



POST BIOPSY

Map 3  
170dB/C 2  
Persist Off  
2D Opt:FSCT  
Fr Rate:Surv  
SonoCT™



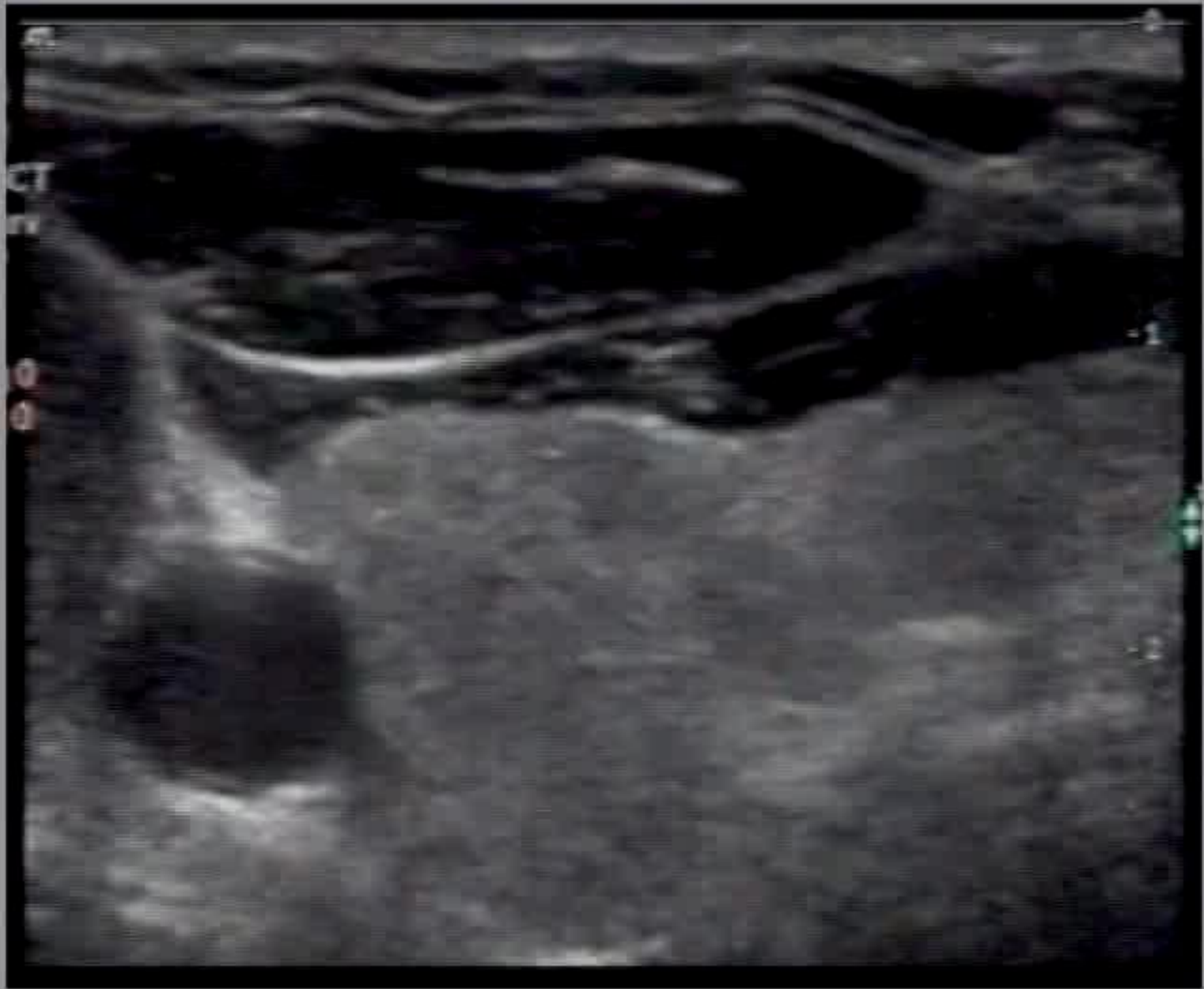
# Follicular lesions.

- Adenomas : solid, homogenous, iso/hyper-echoic.
- Well defined halo.
- Carcinoma : solid ,hypo-echoic areas within.

Medullary carcinoma.



# Medullary Carcinoma Thyroid



- Typically hypo-echoic.
- Contains calcification.
- Calcification more “globular”.
- “Calcification” may be amyloid.




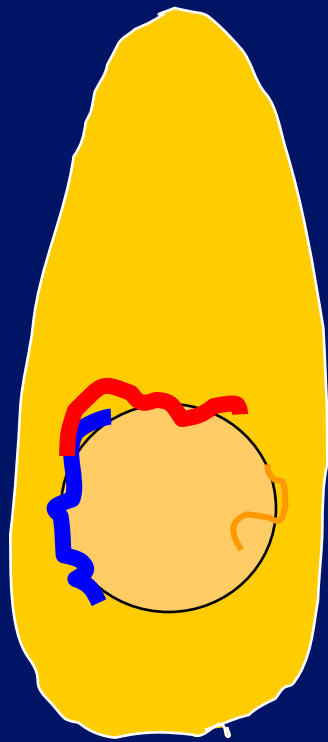
Signs?




























# Predictors of Cancer.

	Sensitivity	Specificity
• Micro-calcifications	40%	90%
• Absence of halo	66%	46%
• Irregular margins	64%	84%
• Hypo-echoic	83%	49%
• Intra-nodular flow	70%	65%
• MicroCa. & irreg m.	30%	95%
• MicroCa. & hypoechoic	28%	95%
• Solid & hypoechoic	73%	69%

# Predictors of Cancer.




Sensitivity



Specificity

• Micro-calcifications	40%	90%
• Absence of halo	66%	46%
• Irregular margins	64%	84%
• Hypo-echoic	83%	49%
• Intra-nodular flow	70%	65%
• MicroCa. & irreg m.	30%	95%
• MicroCa. & hypoechoic	28%	95%
• Solid & hypoechoic	73%	69%




# Predictors of Cancer.

	Sensitivity	Specificity
• Micro-calcifications	40%	90%
• Absence of halo	66%	46%
• Irregular margins	64%	84%
 • Hypo-echoic	83%	49%
• Intra-nodular flow	70%	65%
• MicroCa. & irreg m.	30%	95%
• MicroCa. & hypoechoic	28%	95%
• Solid & hypoechoic	73%	69%

# Predictors of Cancer.

	Sensitivity	Specificity
• Micro-calcifications	40%	90%
• Absence of halo	66%	46%
• Irregular margins	64%	84%
 • Hypo-echoic	83%	49%
• Intra-nodular flow	70%	65%
• MicroCa. & irreg m.	30%	95%
• MicroCa. & hypoechoic	28%	95%
 • Solid & hypoechoic	73%	69%

# Predictors of Cancer.



	Sensitivity	Specificity
• Micro-calcifications	40%	90%
• Absence of halo	66%	46%
• Irregular margins	64%	84%
 • Hypo-echoic	83%	49%
 • Intra-nodular flow	70%	65%
• MicroCa. & irreg m.	30%	95%
• MicroCa. & hypoechoic	28%	95%
 • Solid & hypoechoic	73%	69%

# Predictors of Cancer.




Sensitivity  Specificity

• Micro-calcifications	40%	90%
• Absence of halo	66%	46%
• Irregular margins	64%	84%
• Hypo-echoic	83%	49%
• Intra-nodular flow	70%	65%
• MicroCa. & irreg m.	30%	95%
• MicroCa. & hypoechoic	28%	95%
• Solid & hypoechoic	73%	69%

# Predictors of Cancer.

	Sensitivity	Specificity
• Micro-calcifications	40%	90%
• Absence of halo	66%	46%
• Irregular margins	64%	84%
• Hypo-echoic	83%	49%
• Intra-nodular flow	70%	65%
 MicroCa. & irreg m.	30%	95%
 MicroCa. & hypoechoic	28%	95%
• Solid & hypoechoic	73%	69%

# Predictors of Cancer.

	Sensitivity	Specificity
 Micro-calcifications	40%	90%
• Absence of halo	66%	46%
• Irregular margins	64%	84%
• Hypo-echoic	83%	49%
• Intra-nodular flow	70%	65%
 MicroCa. & irreg m.	30%	95%
 MicroCa. & hypoechoic	28%	95%
• Solid & hypoechoic	73%	69%

# Thyroid nodules.

- Sorting out nodules.
- Learn from others – Breast Radiologists.
- R Classification.
- Cytological classification(1 -5)
- Clinical scenario.
- Correctly manage patient.

# Breast nodules – R classification..

**R**

- 1 : Normal.
- 2 : Probably benign.
- 3 : Indeterminate.
- 4 : Suspicious.
- 5 : Malignant


# Nodules – R classification.....thyroid?



**R**

- 1 : Normal.
- 2 : Probably benign.
- 3 : Indeterminate.
- 4 : Suspicious.
- 5 : Malignant






R 1



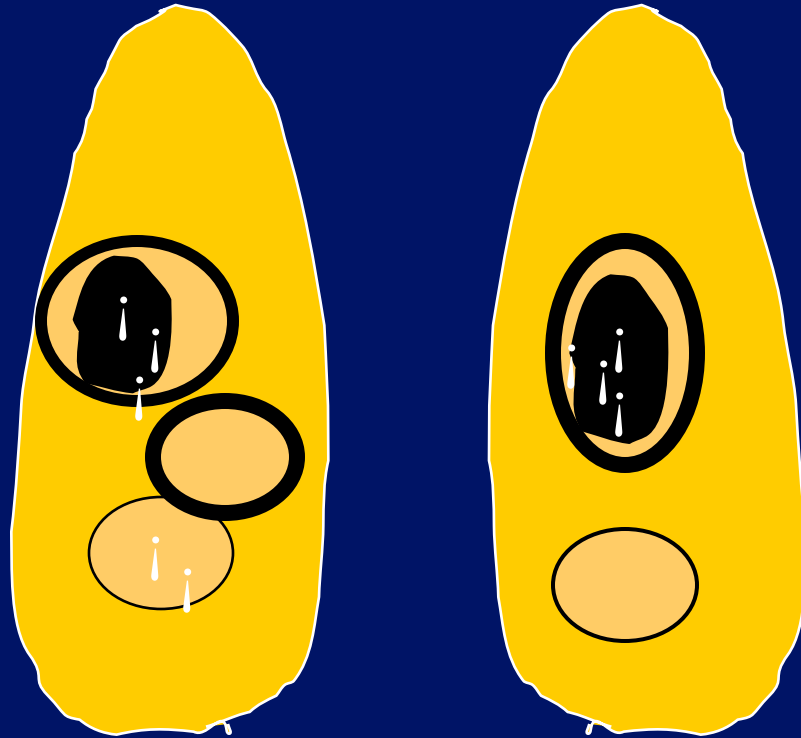


R 2

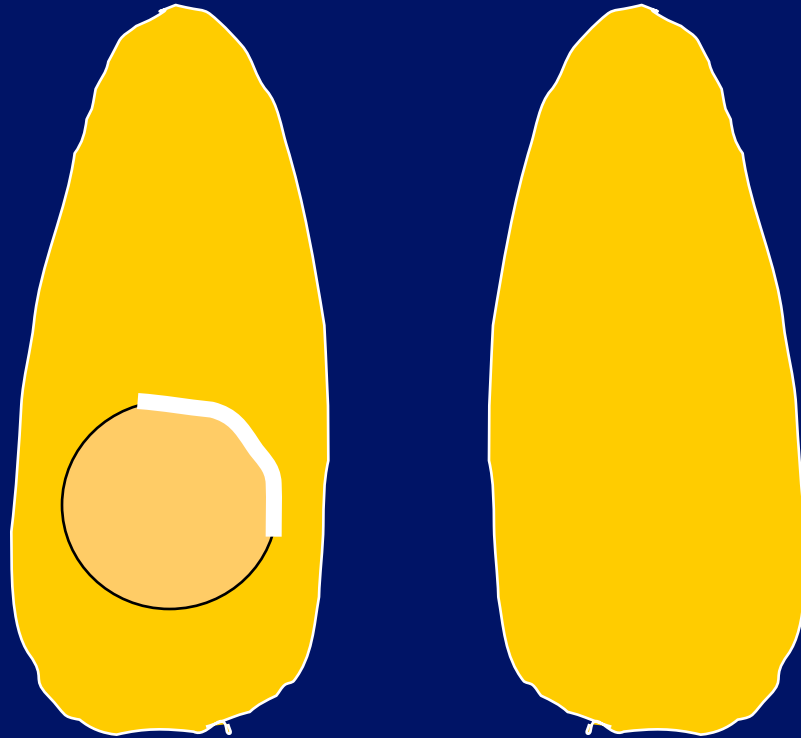




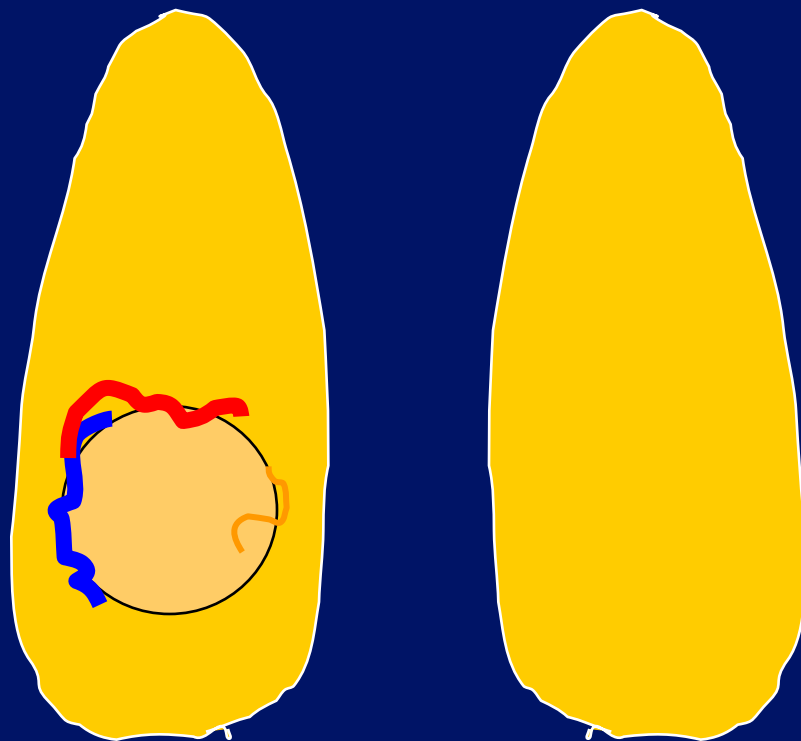
R 2




R 2

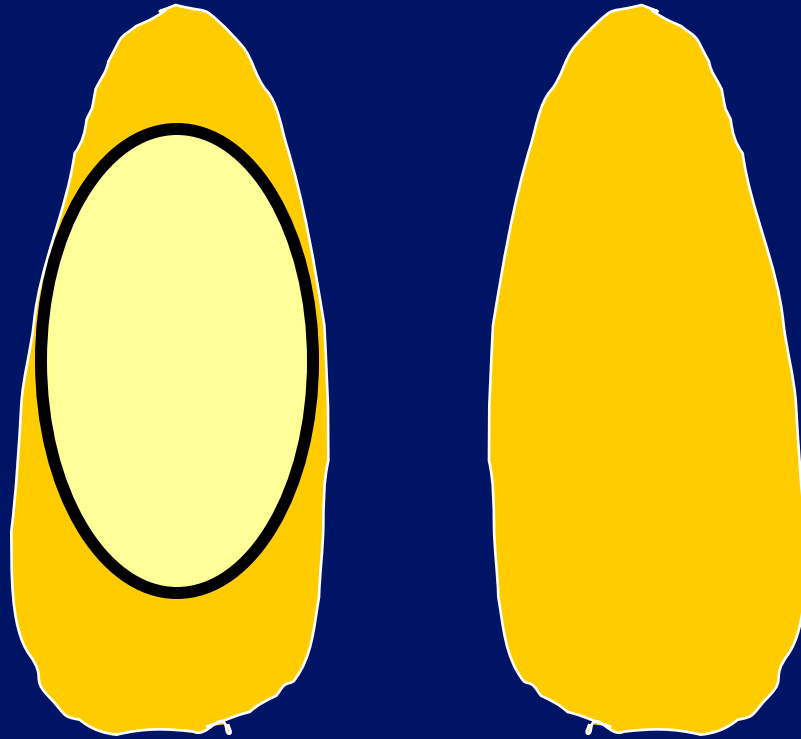


R 2






R 3

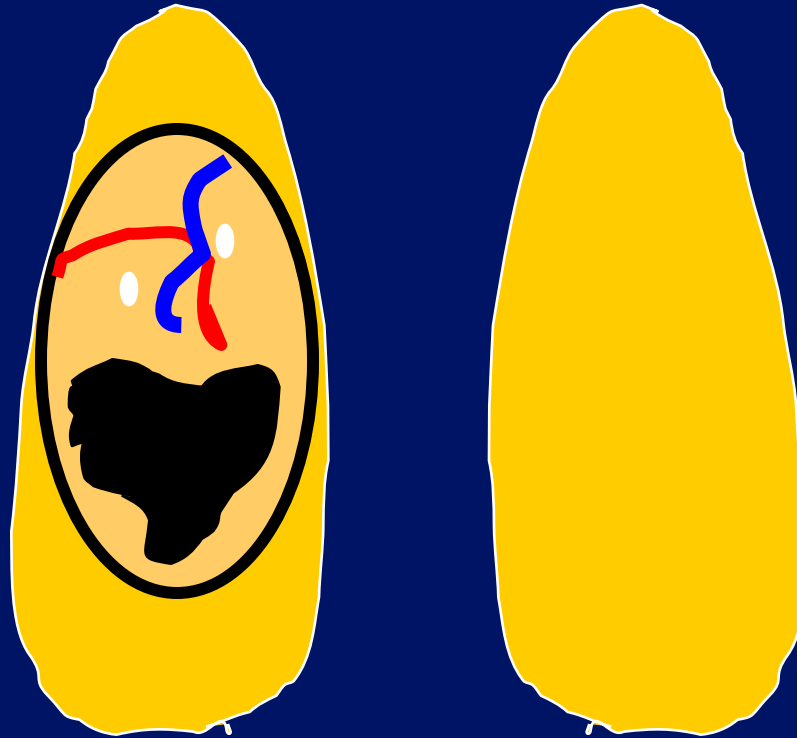




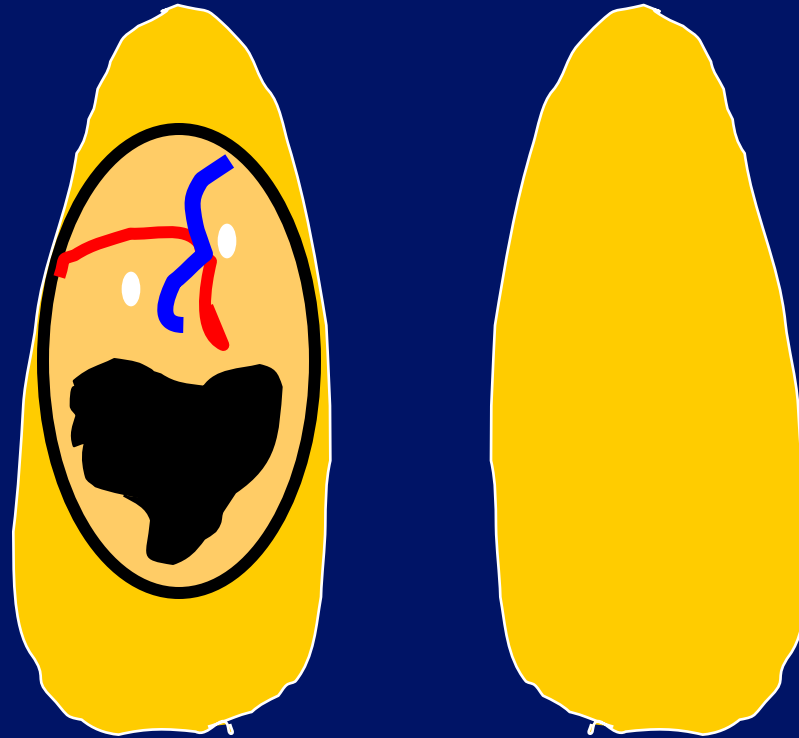
R ?



R ?

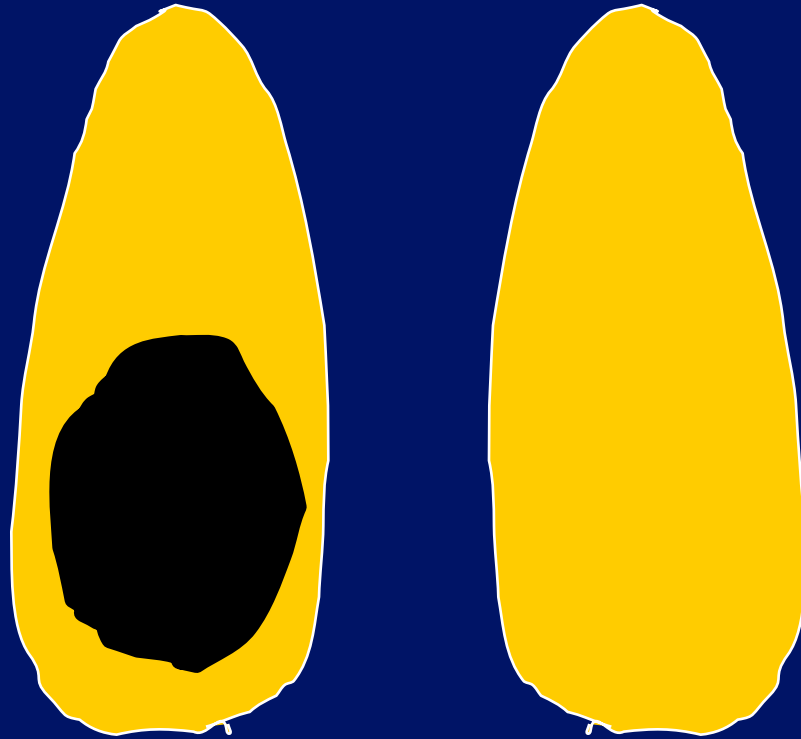


R 3





R 4



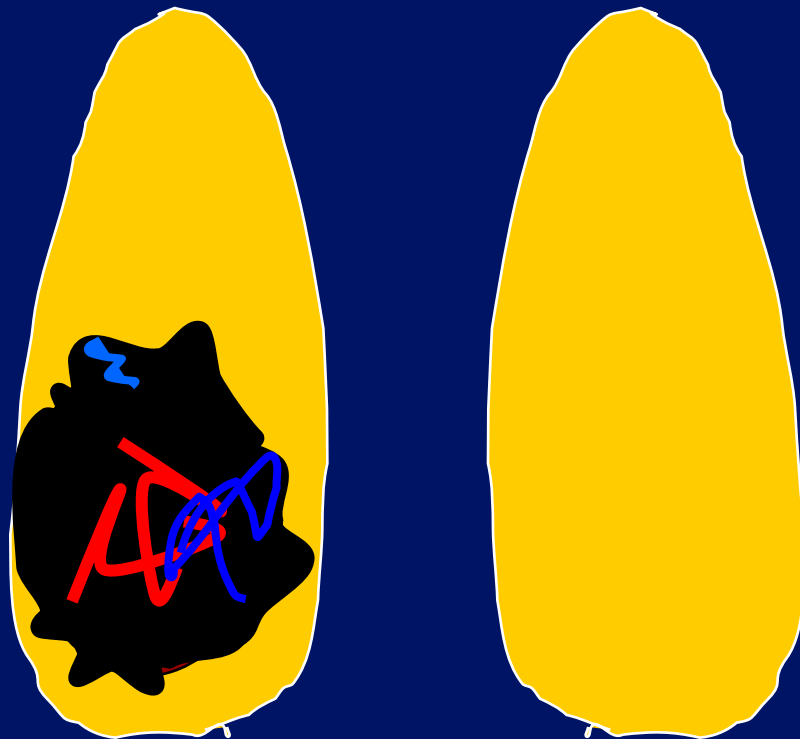



R 4/5



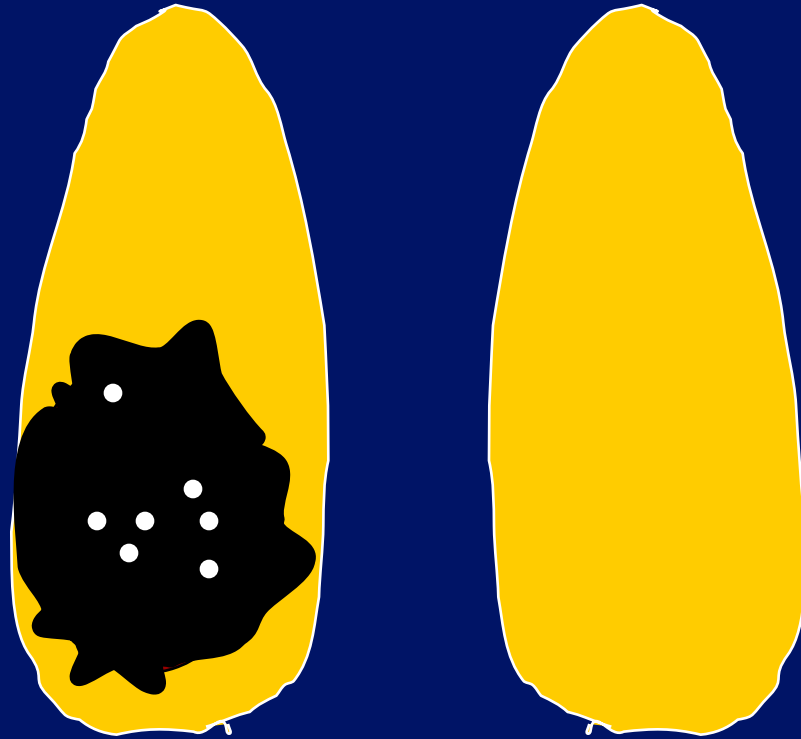




R 5






R 5






R 5



Lymphoma

R 5

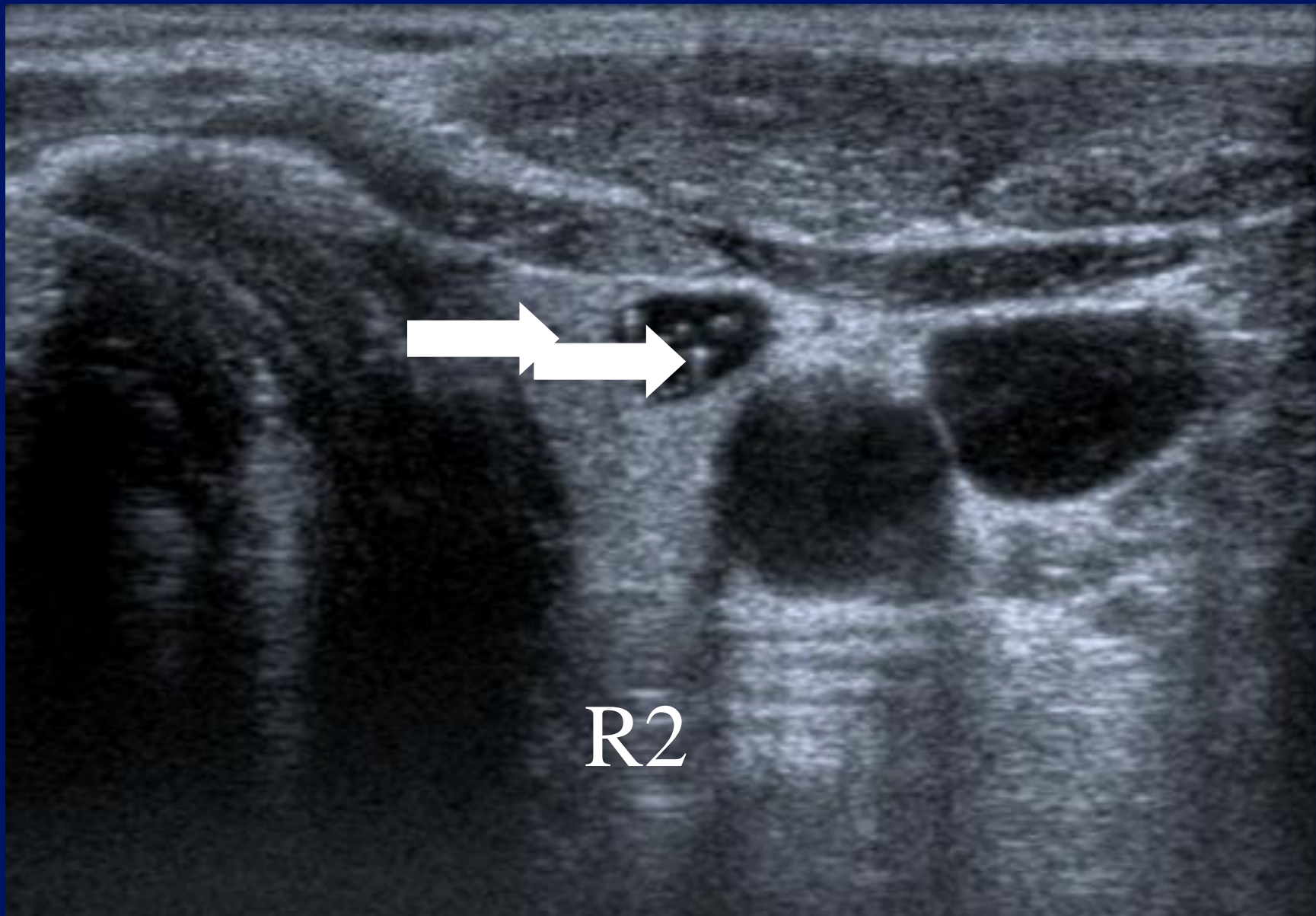


Metastases

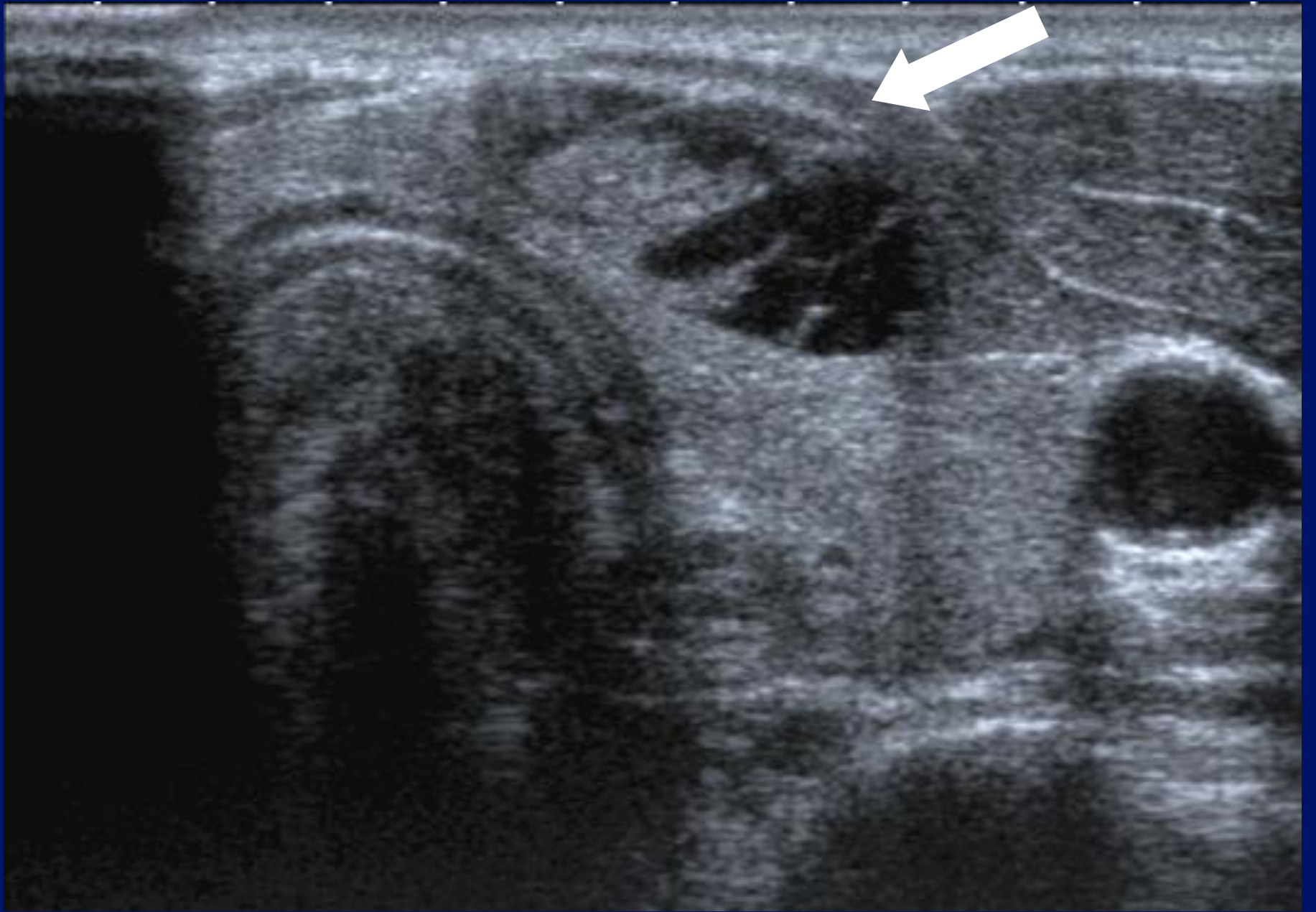
# Thyroid nodules.

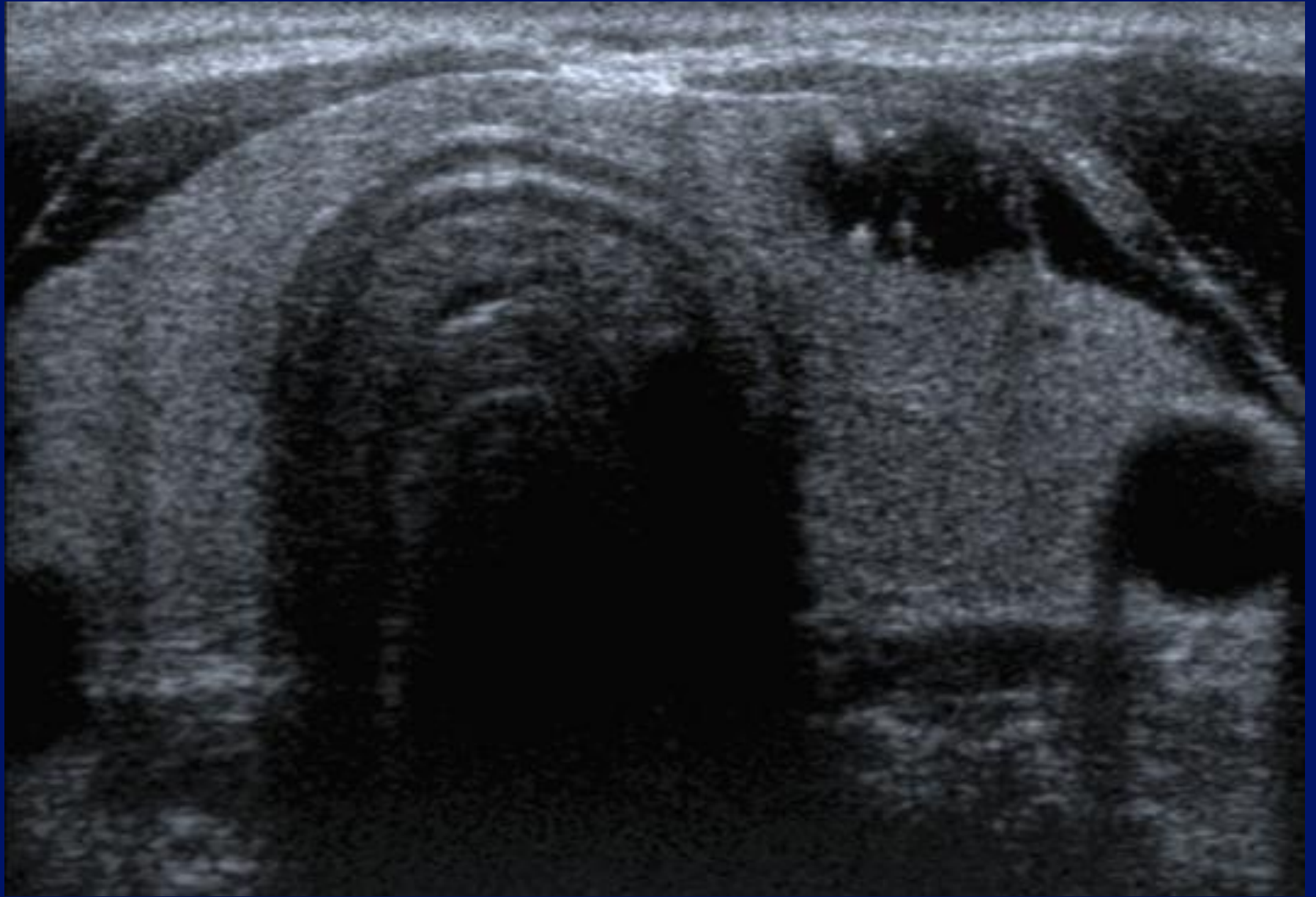
- R Classification.
- Cytological classification(1 -5)
- Clinical scenario.
- Correctly manage patient.

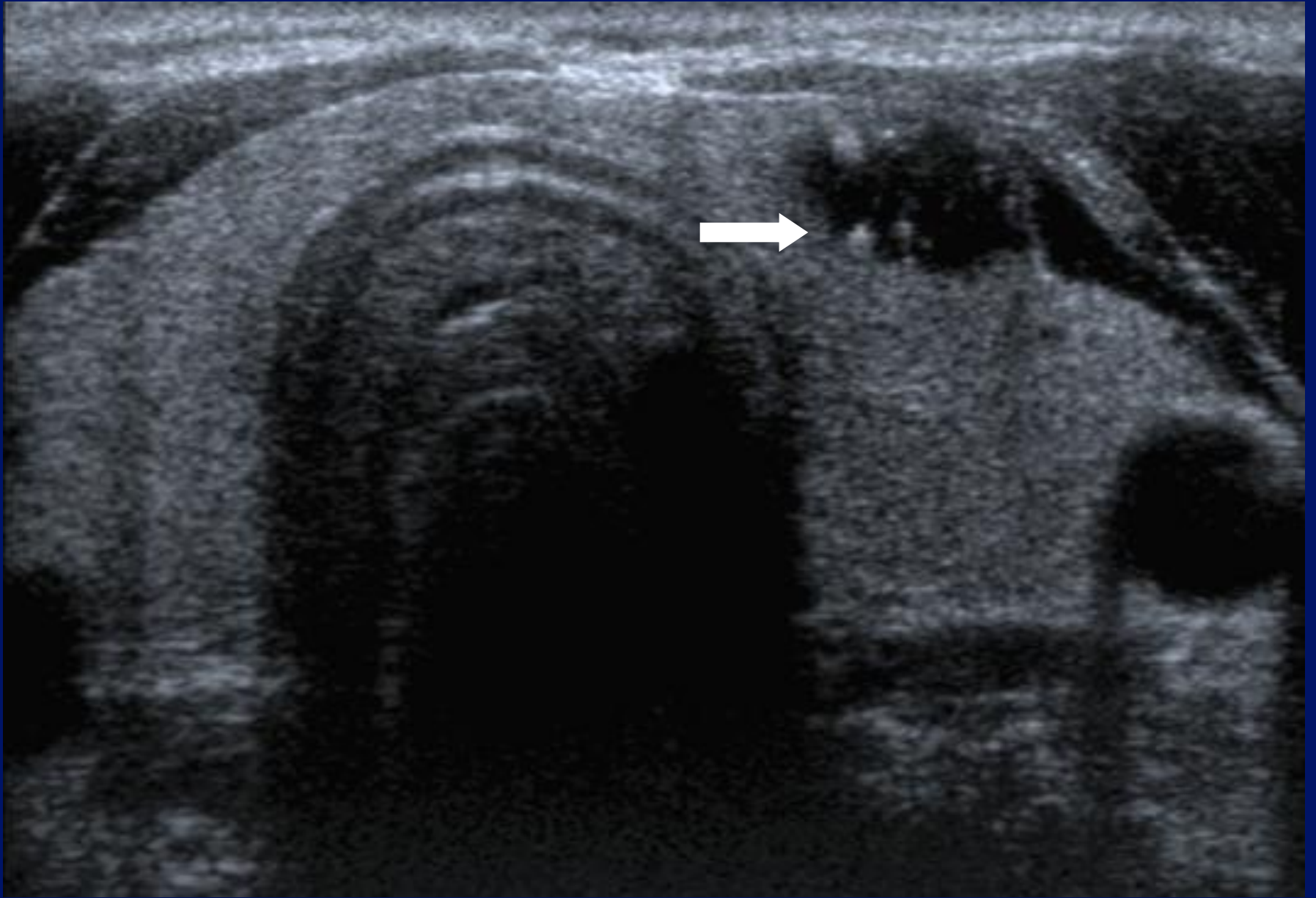
Case 1.



Case 2.







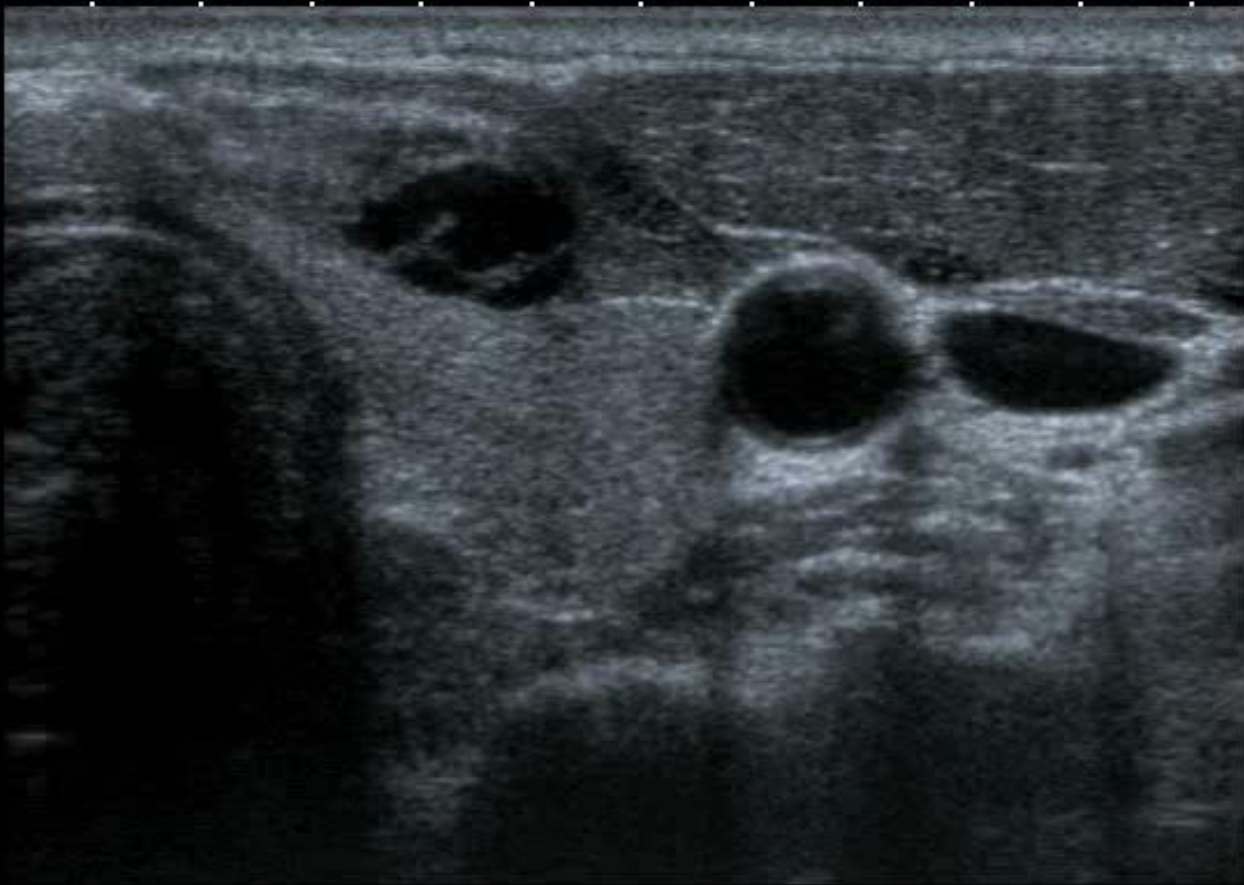
**R 2 or 3?**



T  
0 ◆  
1 ◆  
2 ◆  
3 ◆  
4 ◆

12L5  
T9.0

33 fps

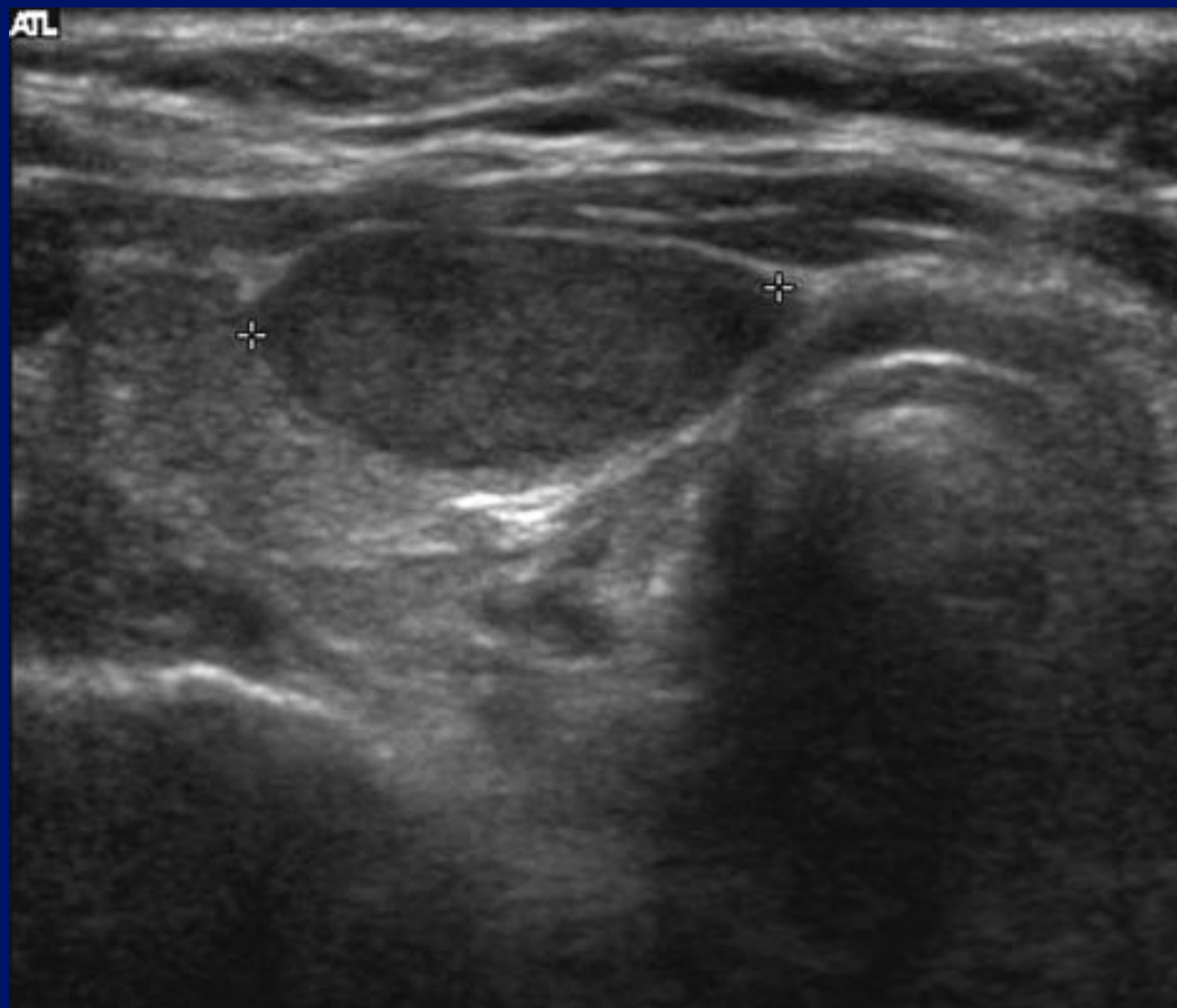


MI:1.6  
2DG  
93  
DR  
70

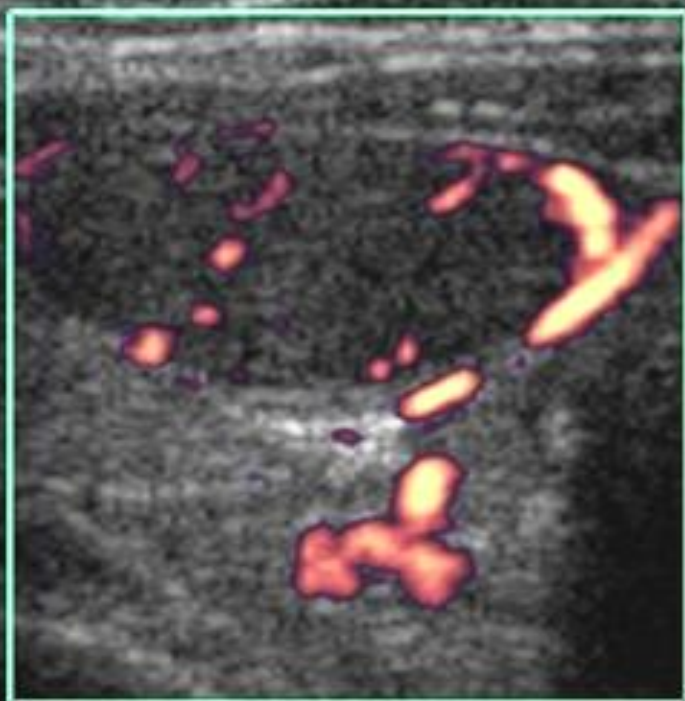


Case 3.

ATL

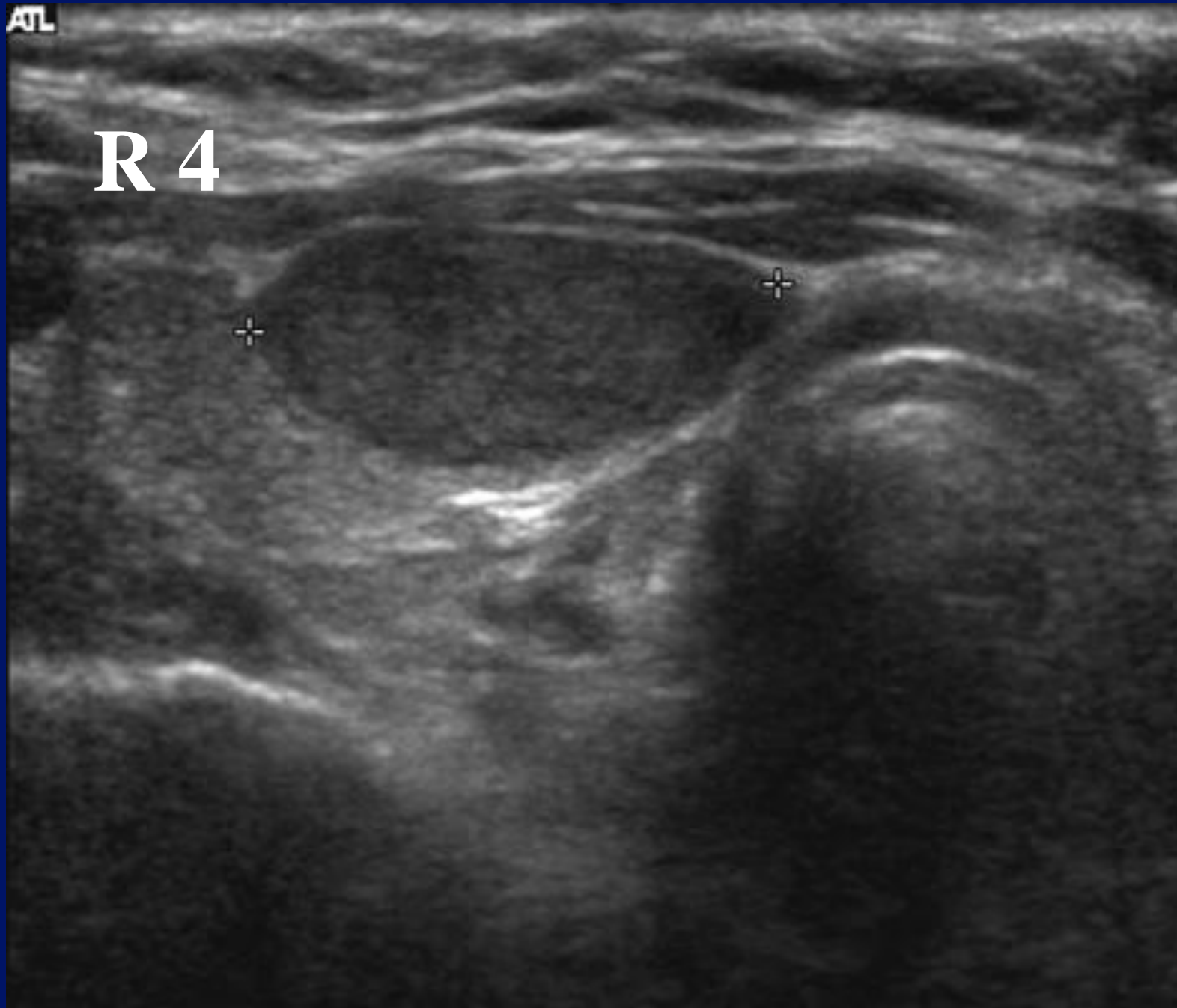

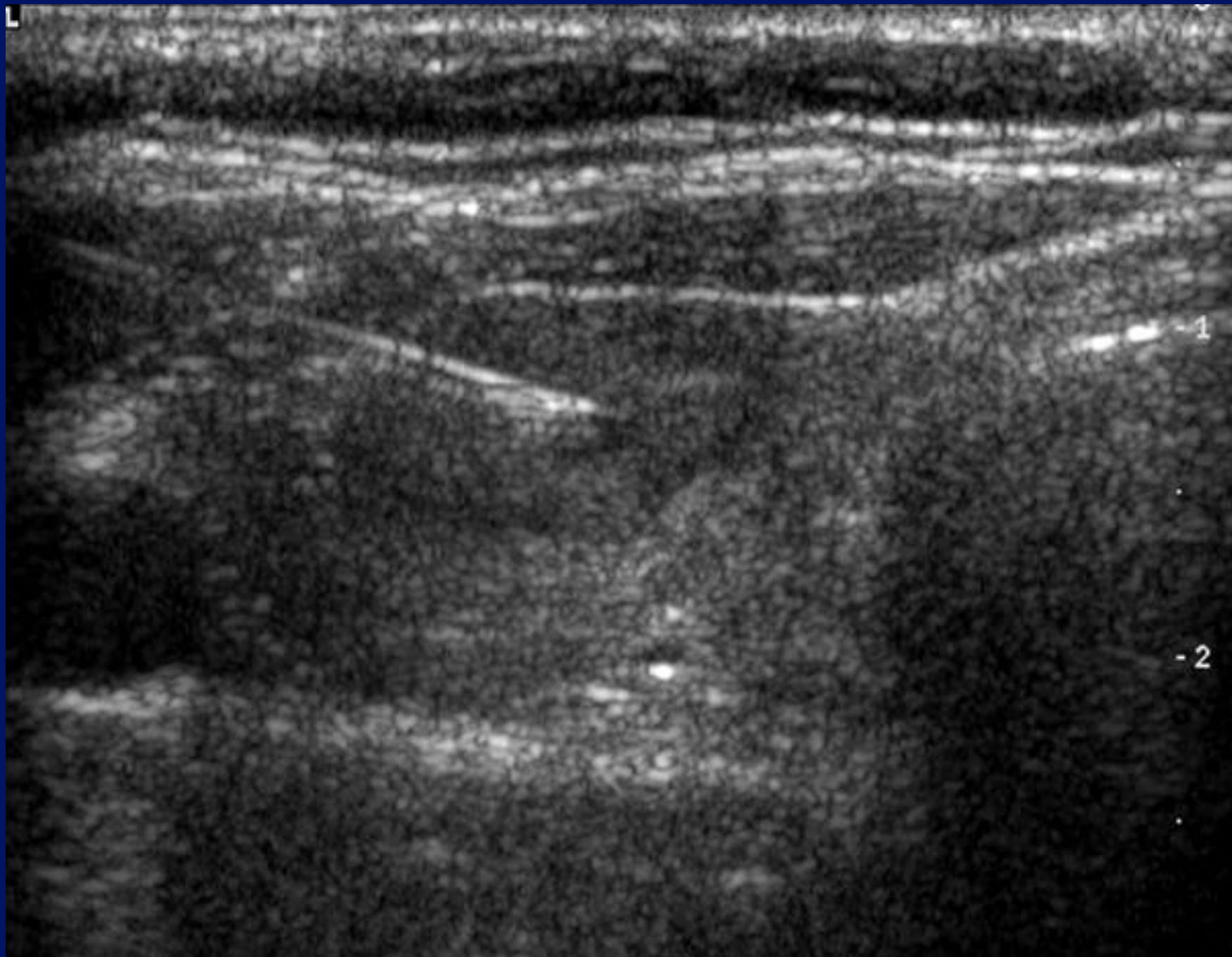
ATL

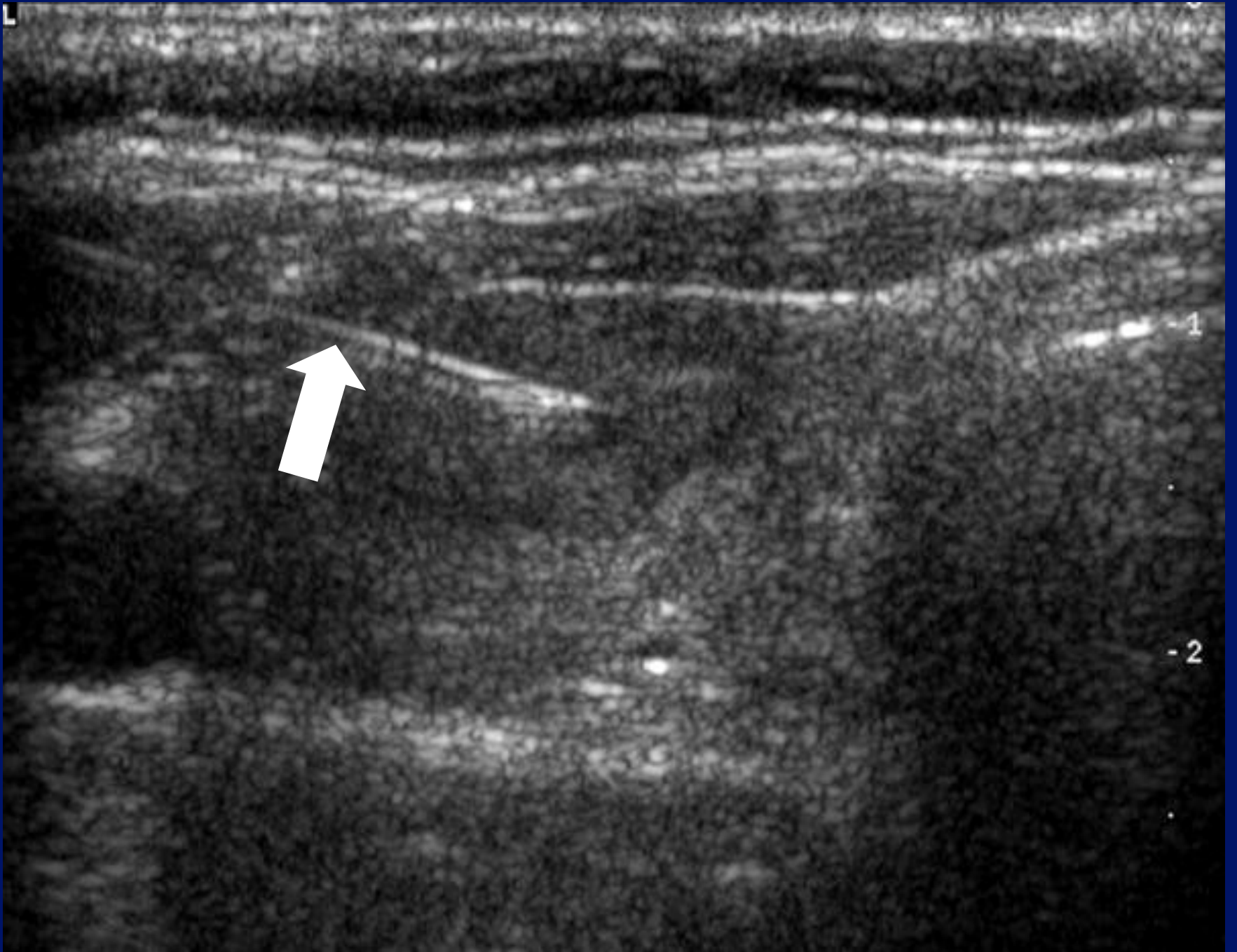

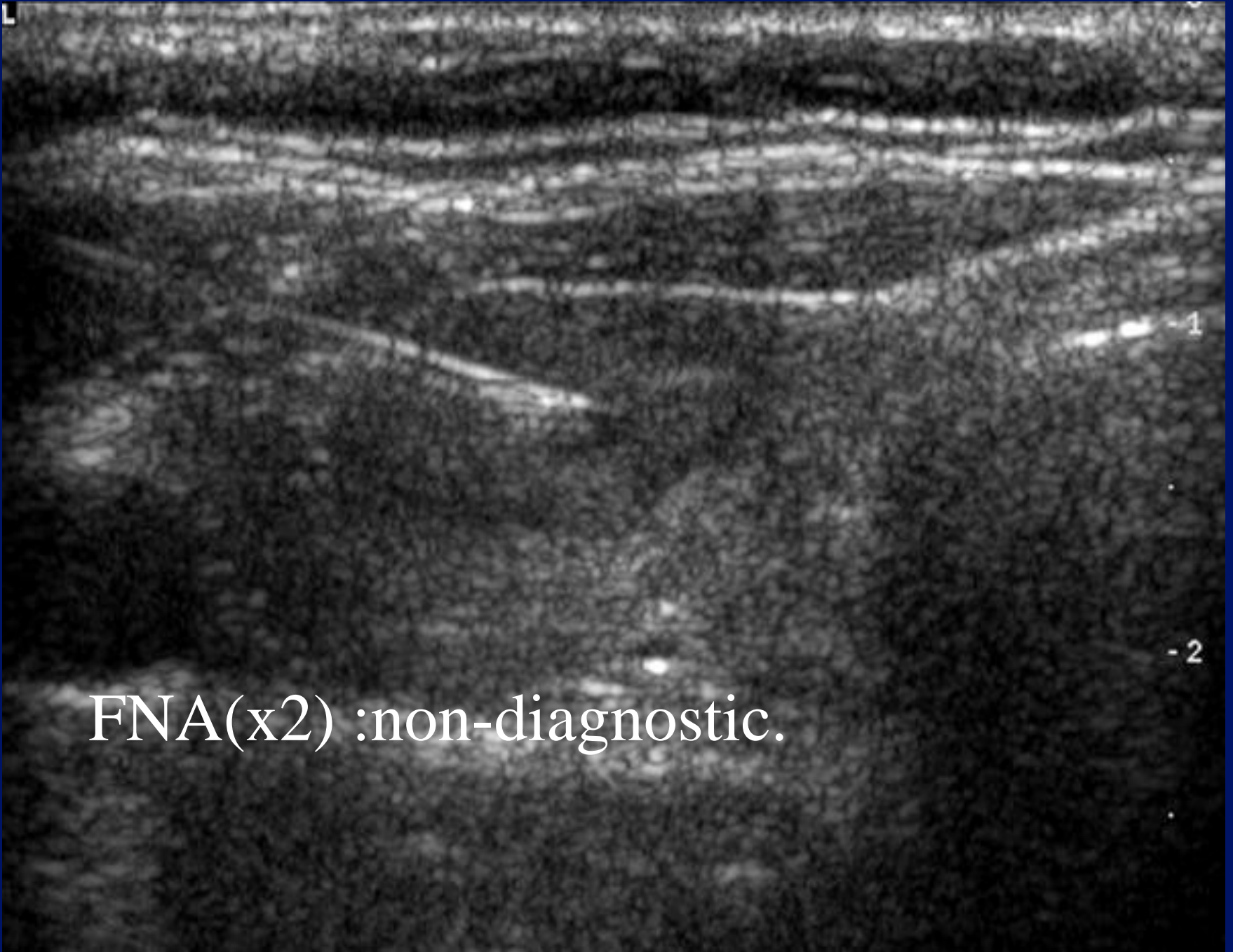
ATL

R 4



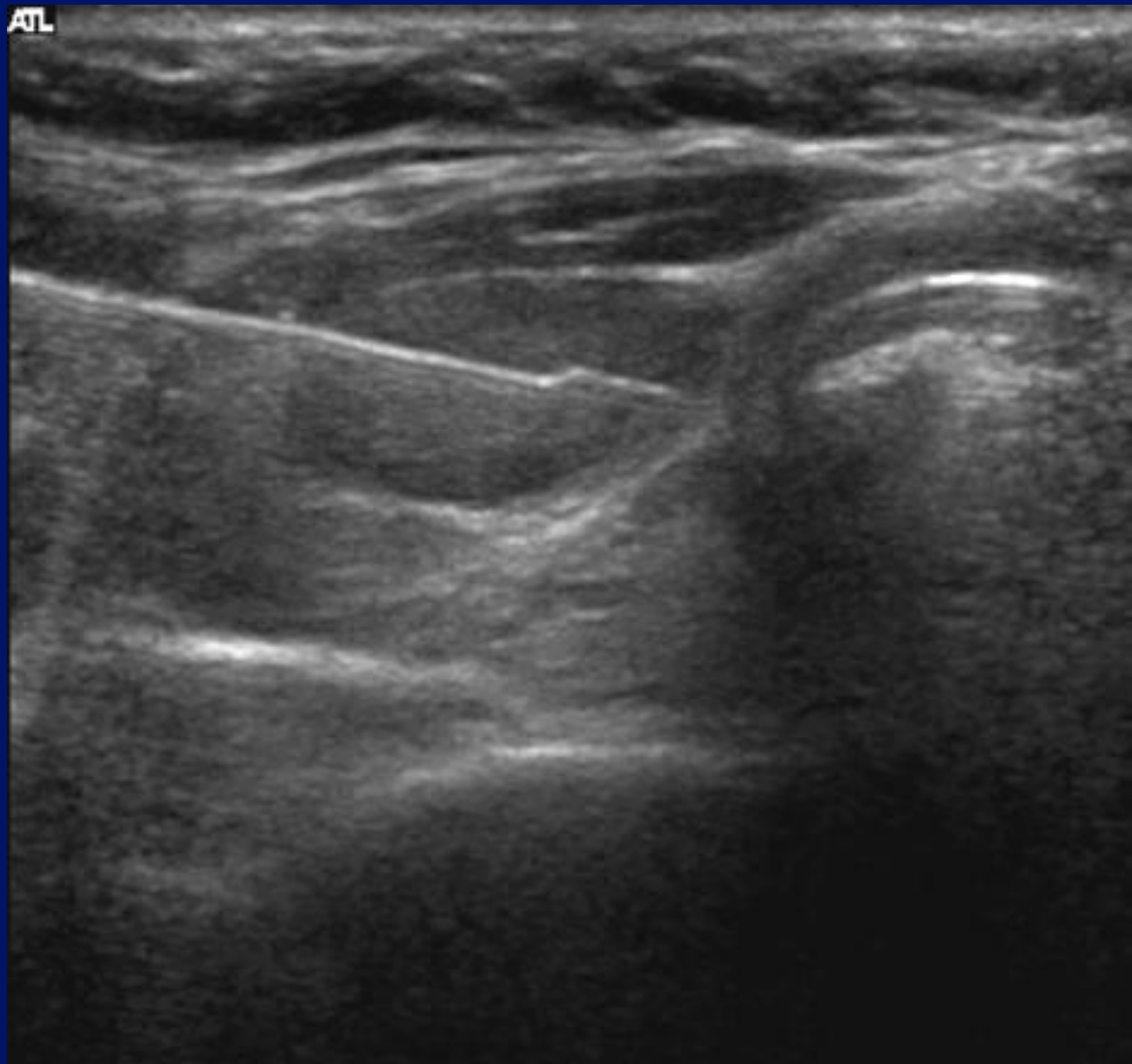




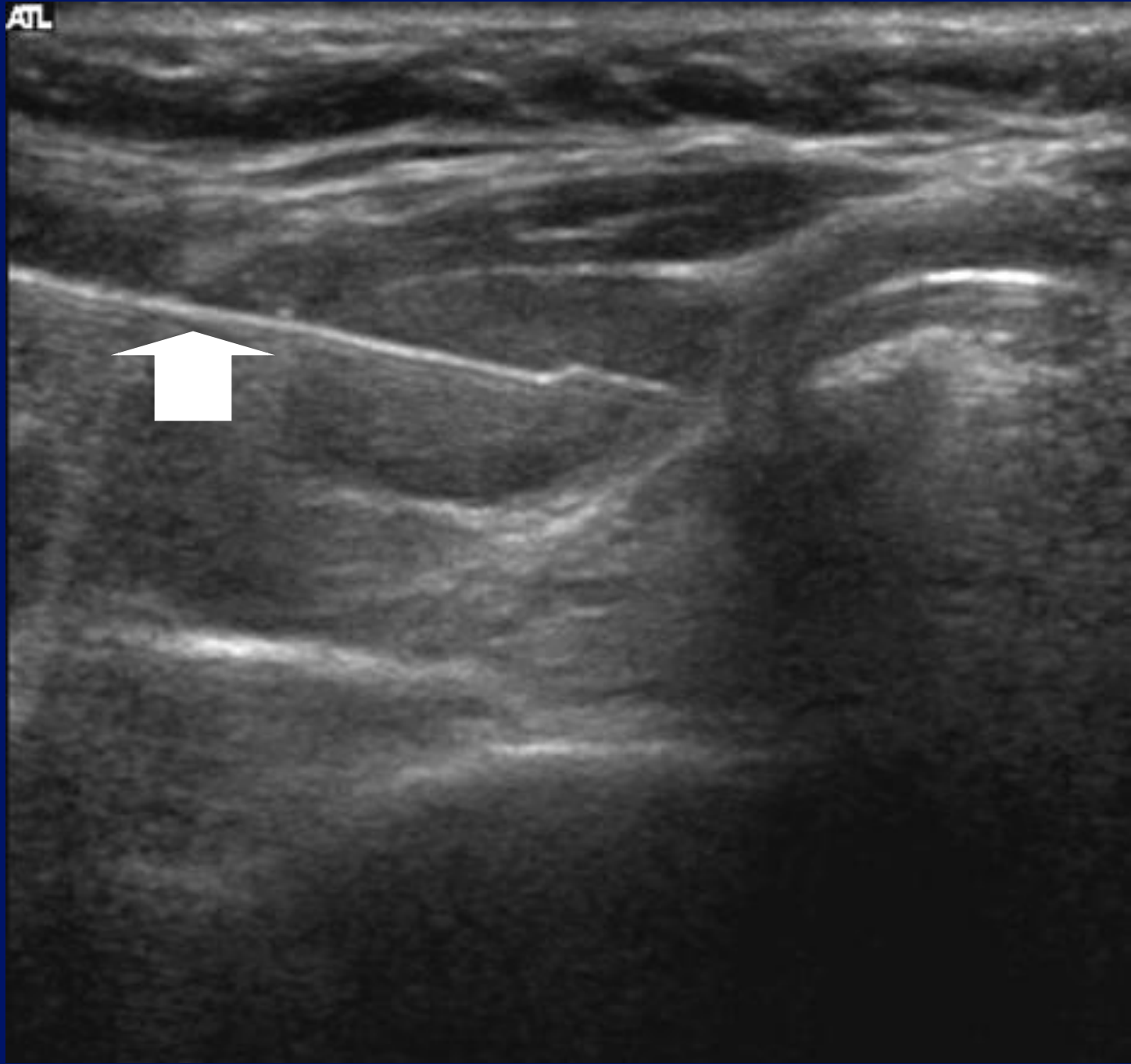

FNA(x2) :non-diagnostic.

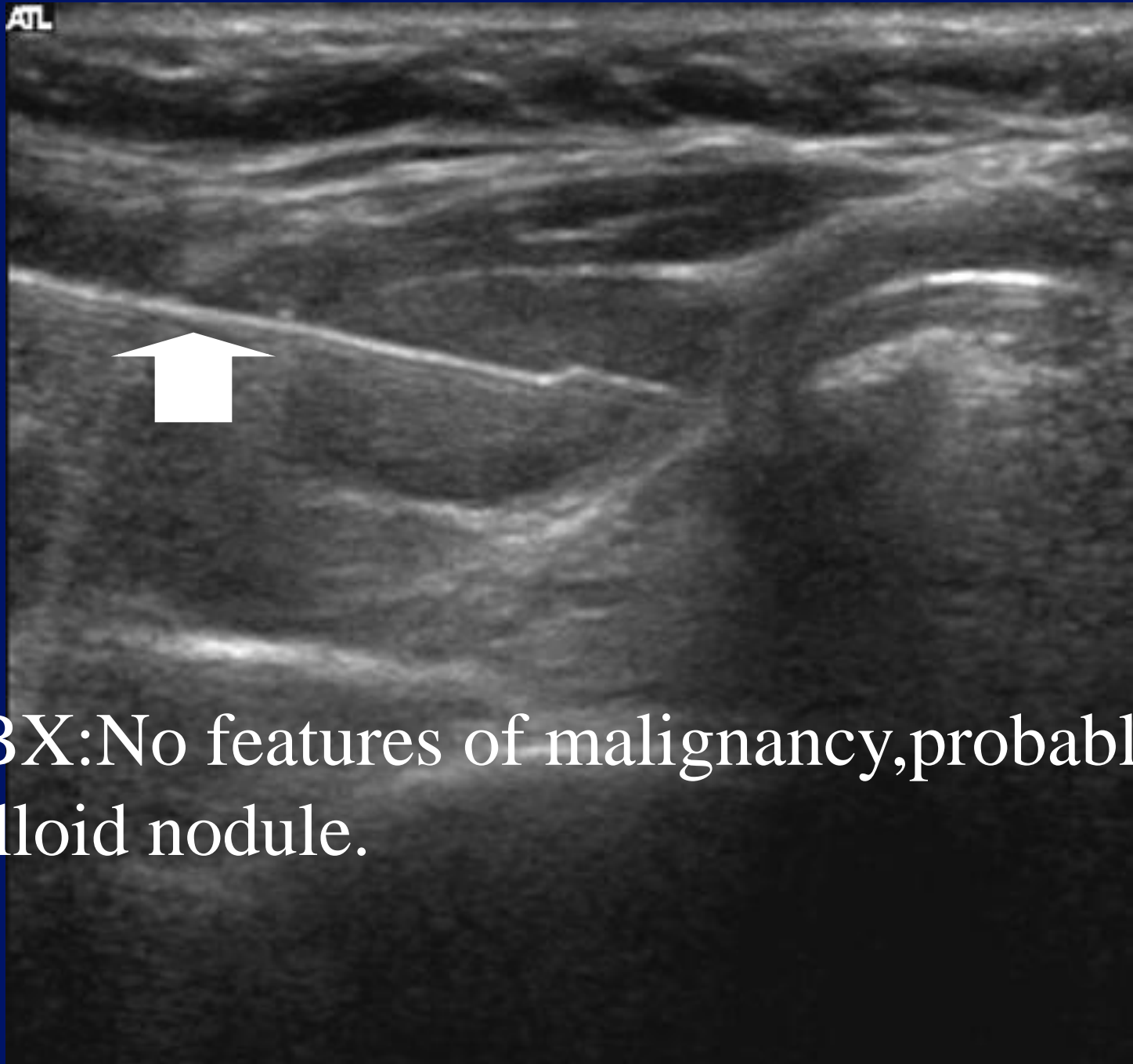ATL



ATL

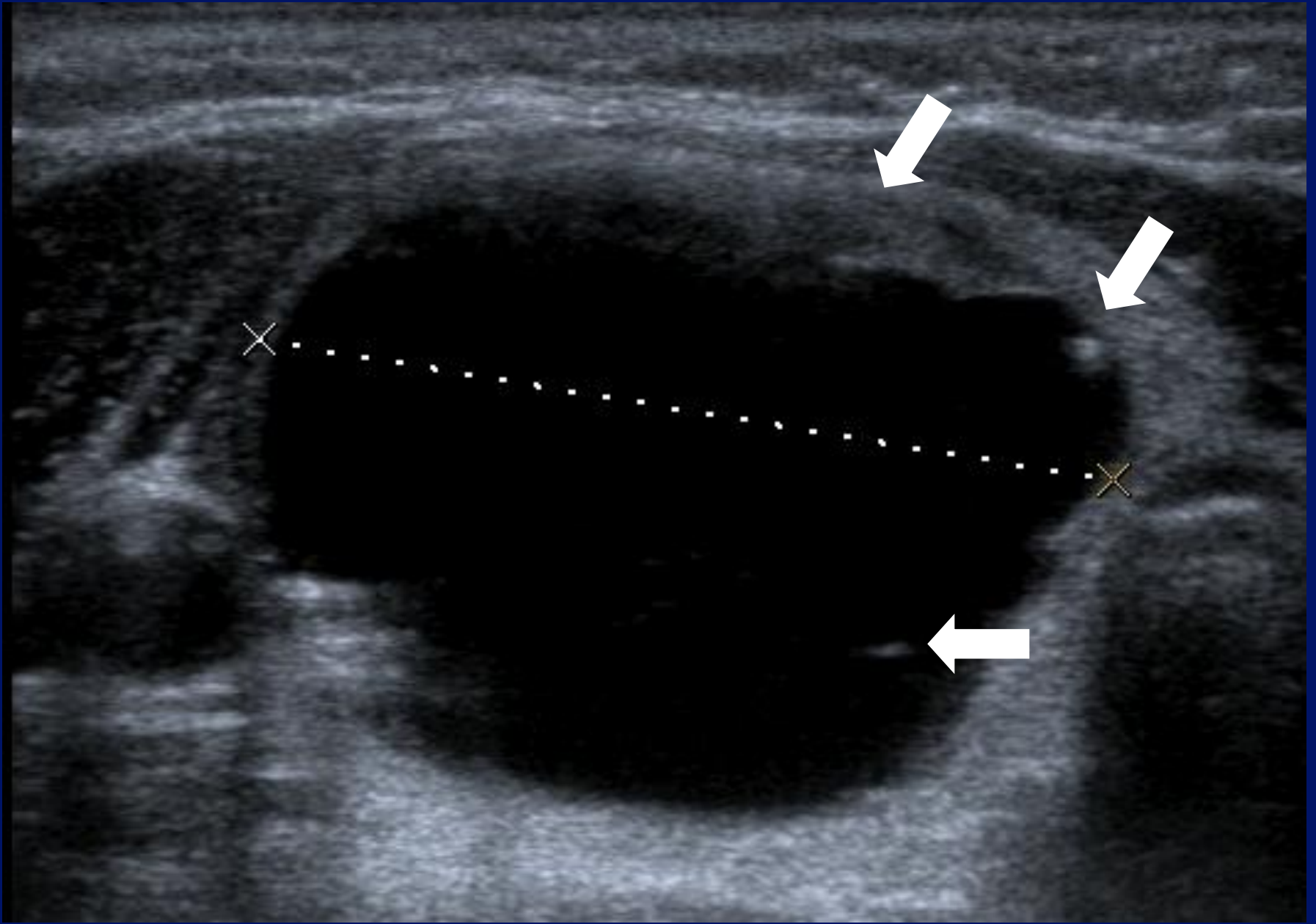


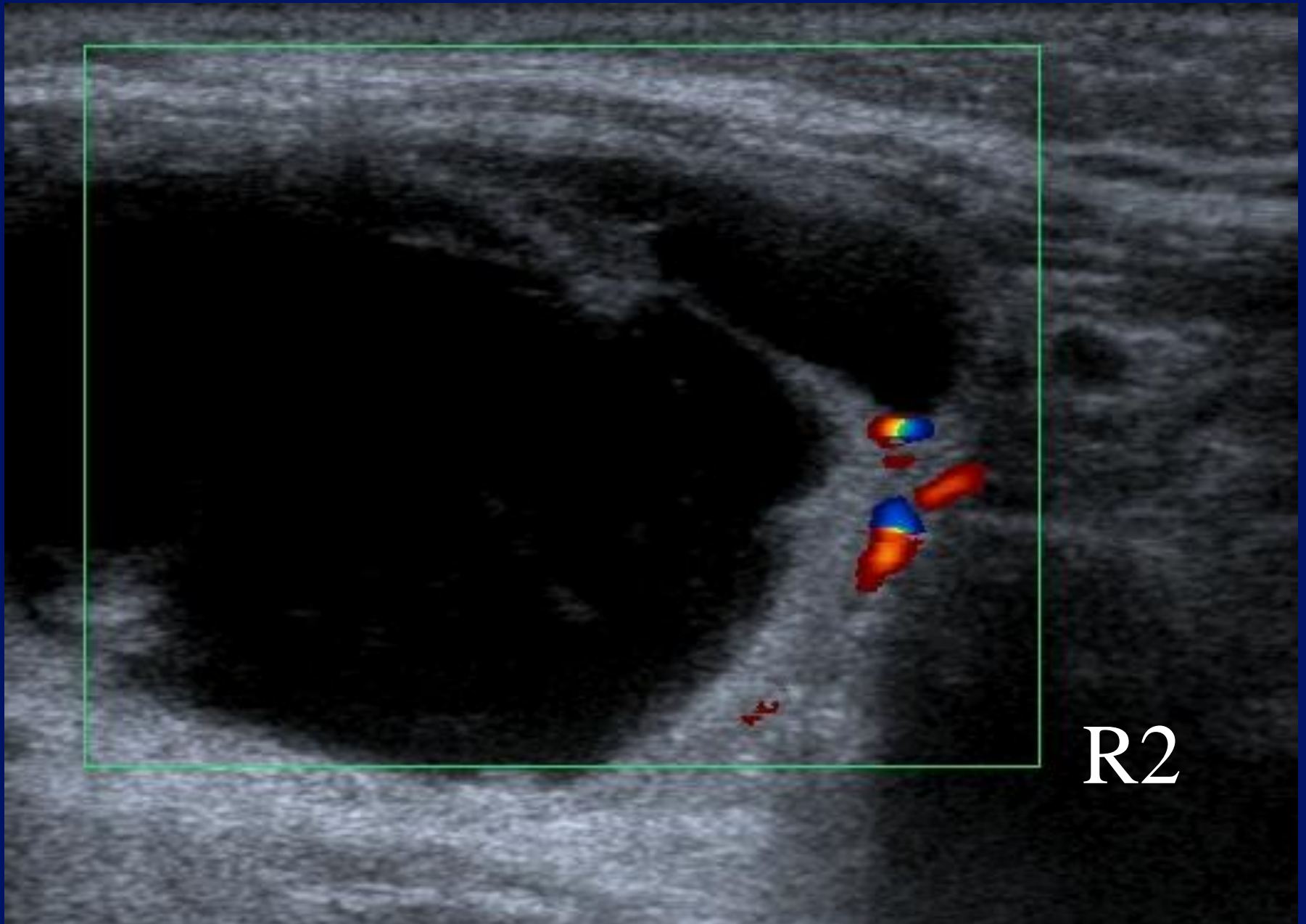
ATL



CBX: No features of malignancy, probable colloid nodule.

Case 4.





R2

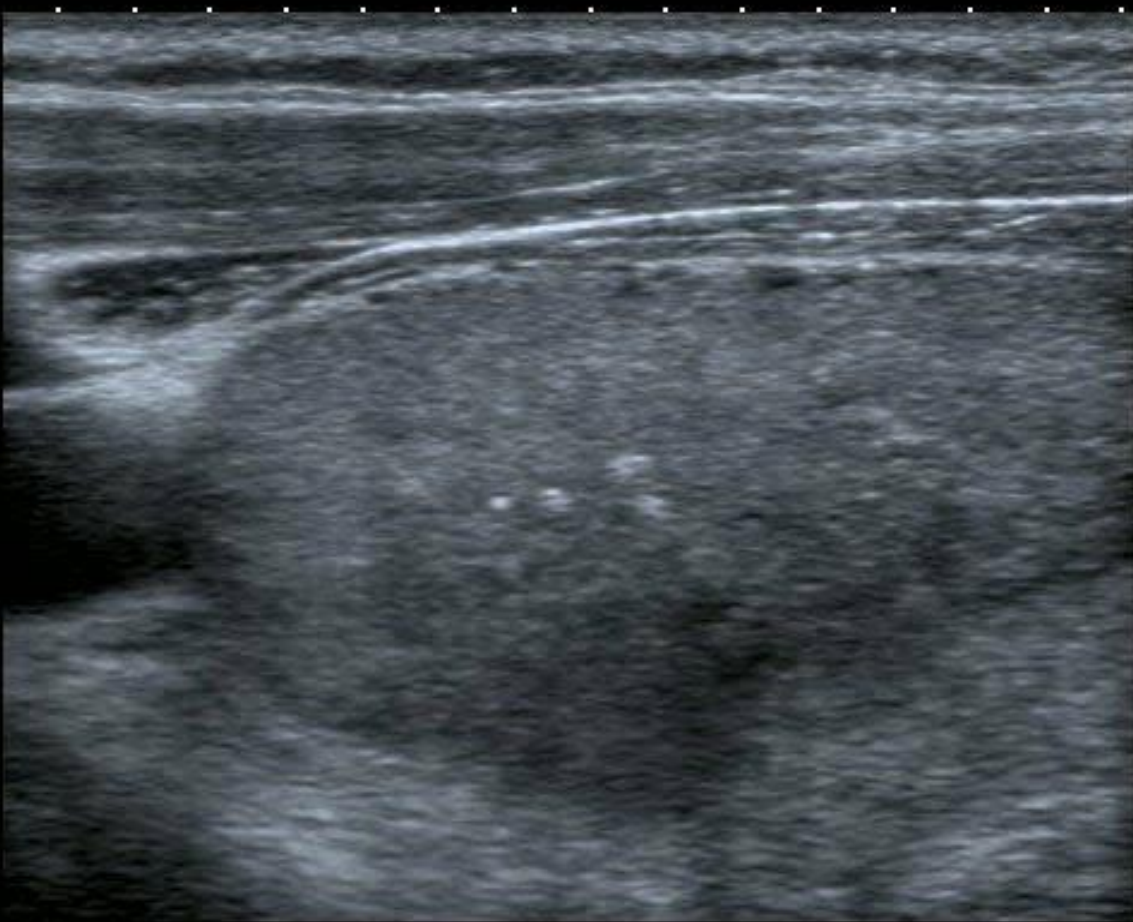
# Case 5.



R1



- 0 ◆
- 1 ◆▶
- 2 ◆
- 3 ◆



T

14L7  
diffT13.0  
25 fps

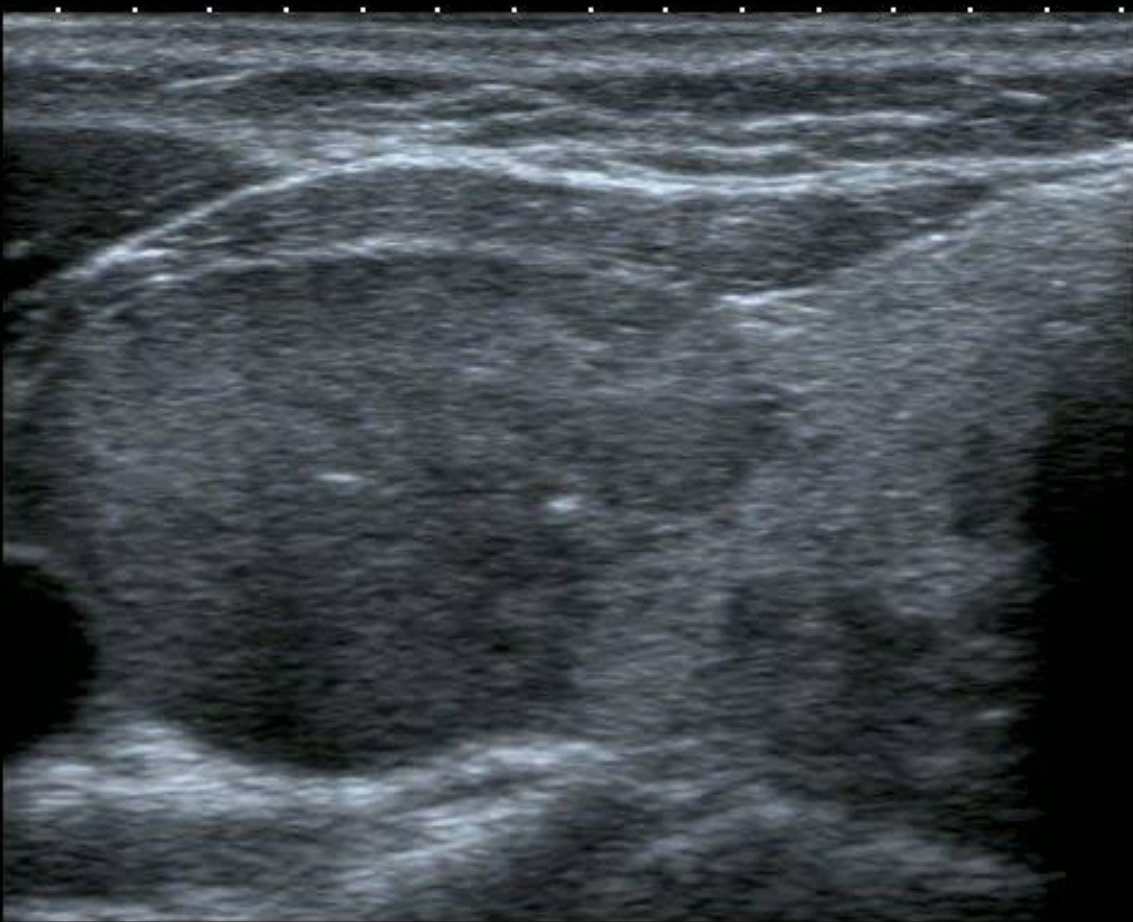MI: 1.4  
2DG  
80  
DR  
65

IP4





- 0 ◆
- 1 ◆▶
- 2 ◆
- 3 ◆



T

14L7  
diffT13.0

25 fps


MI: 1.4

2DG  
80

DR  
65

IP4





# Salivary glands.

- Stones.
- Salivary tumours.
- Extra – salivary tumours.

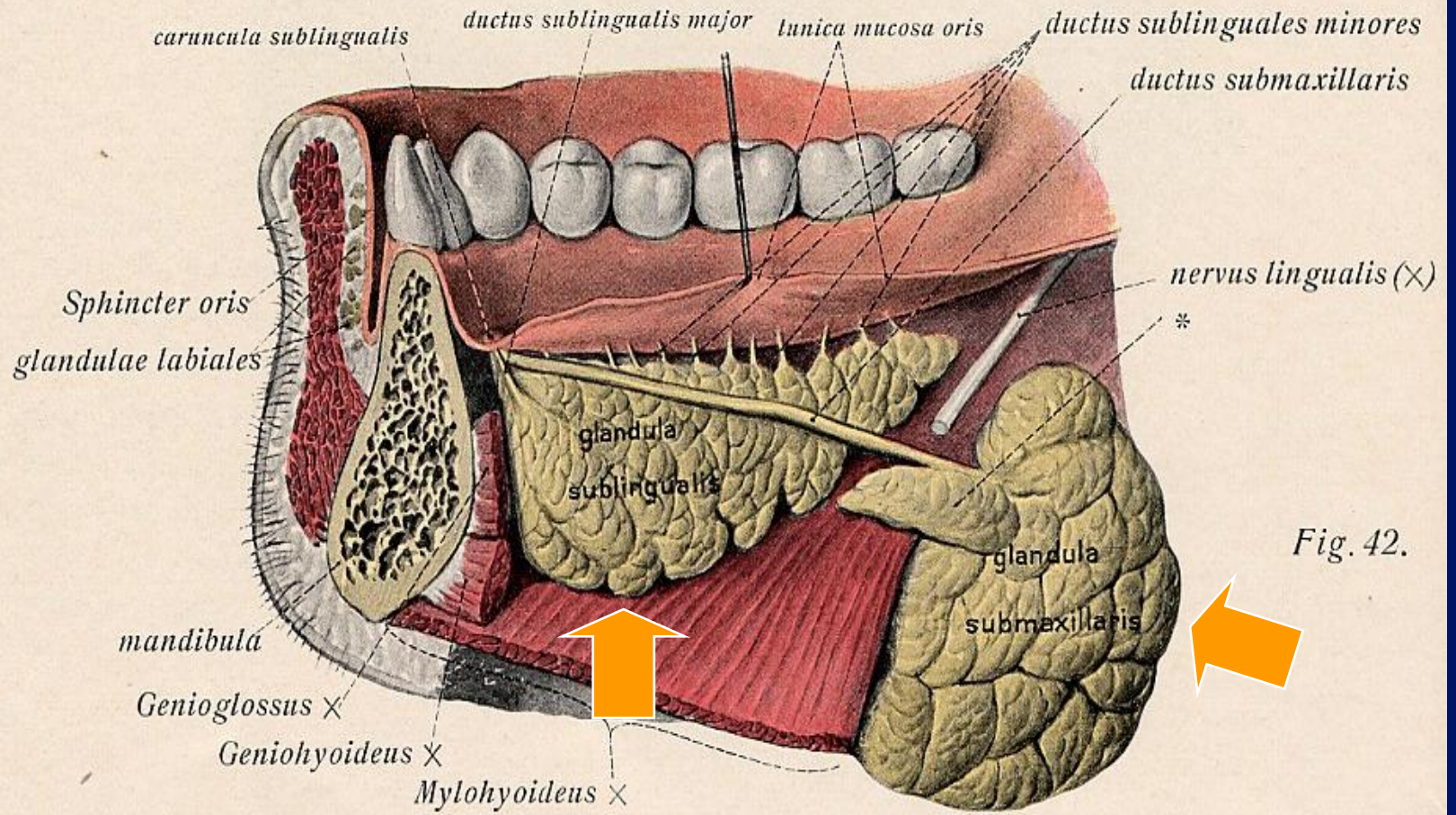
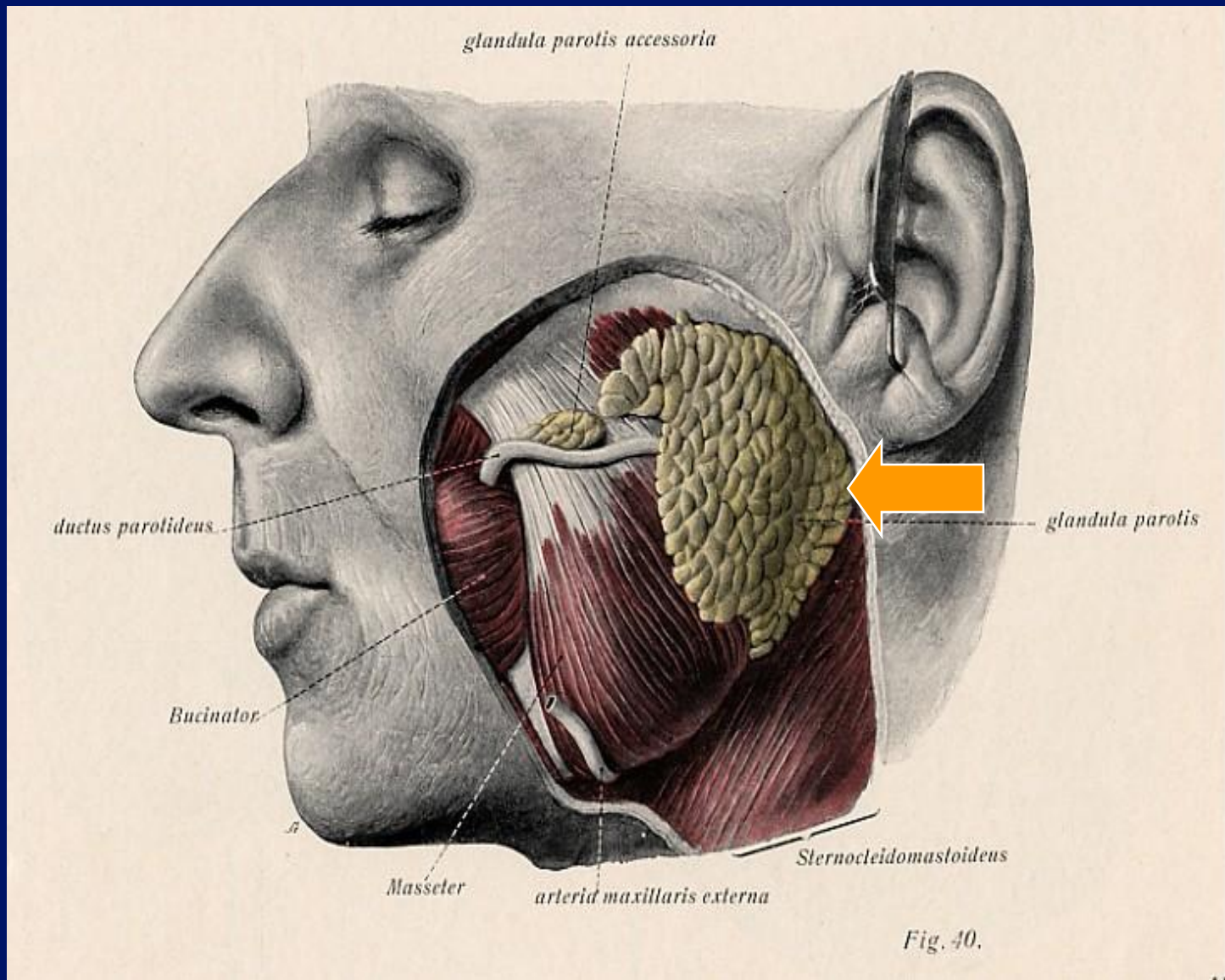


Fig. 42.



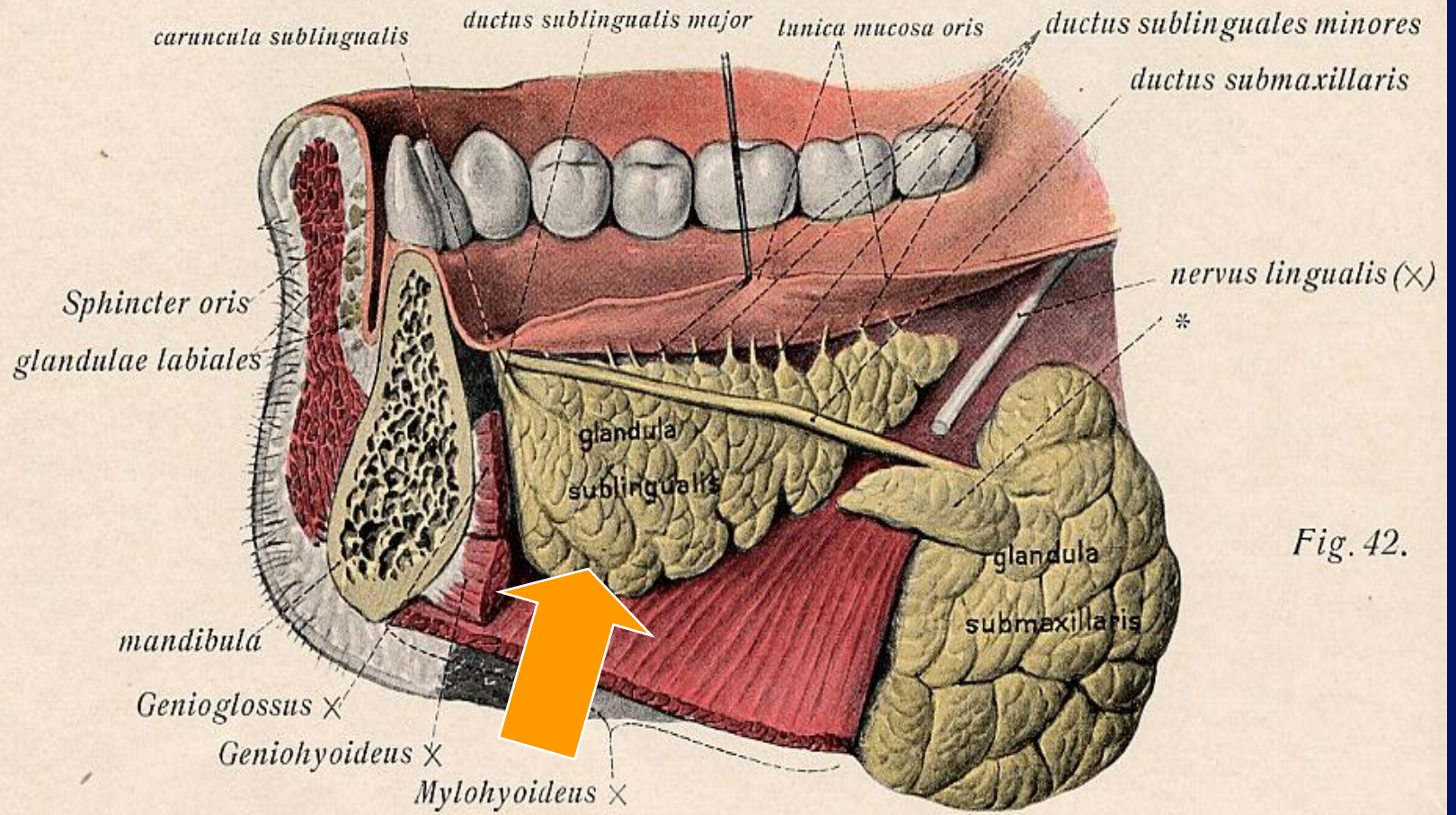


Fig. 42.

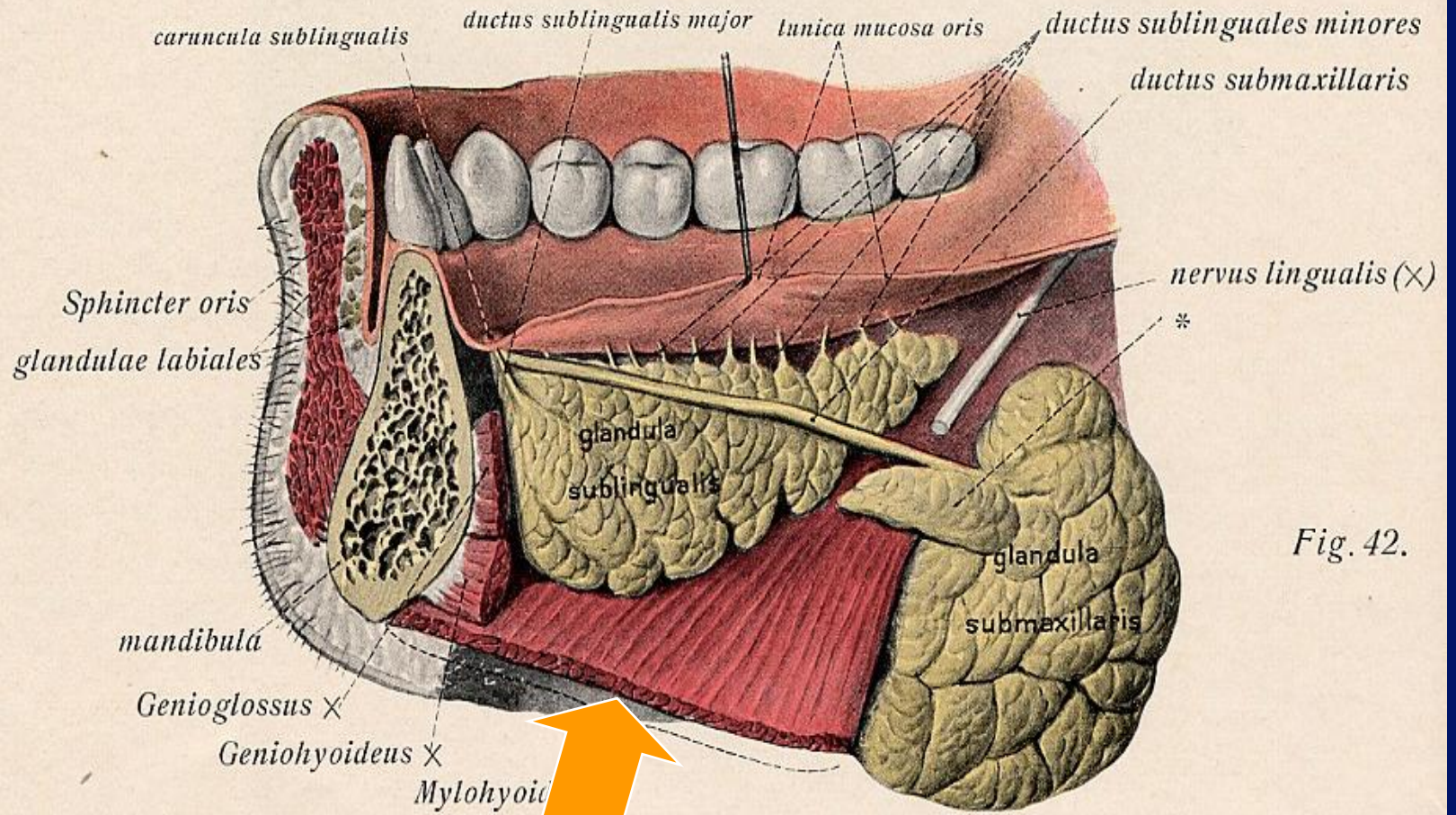


Fig. 42.

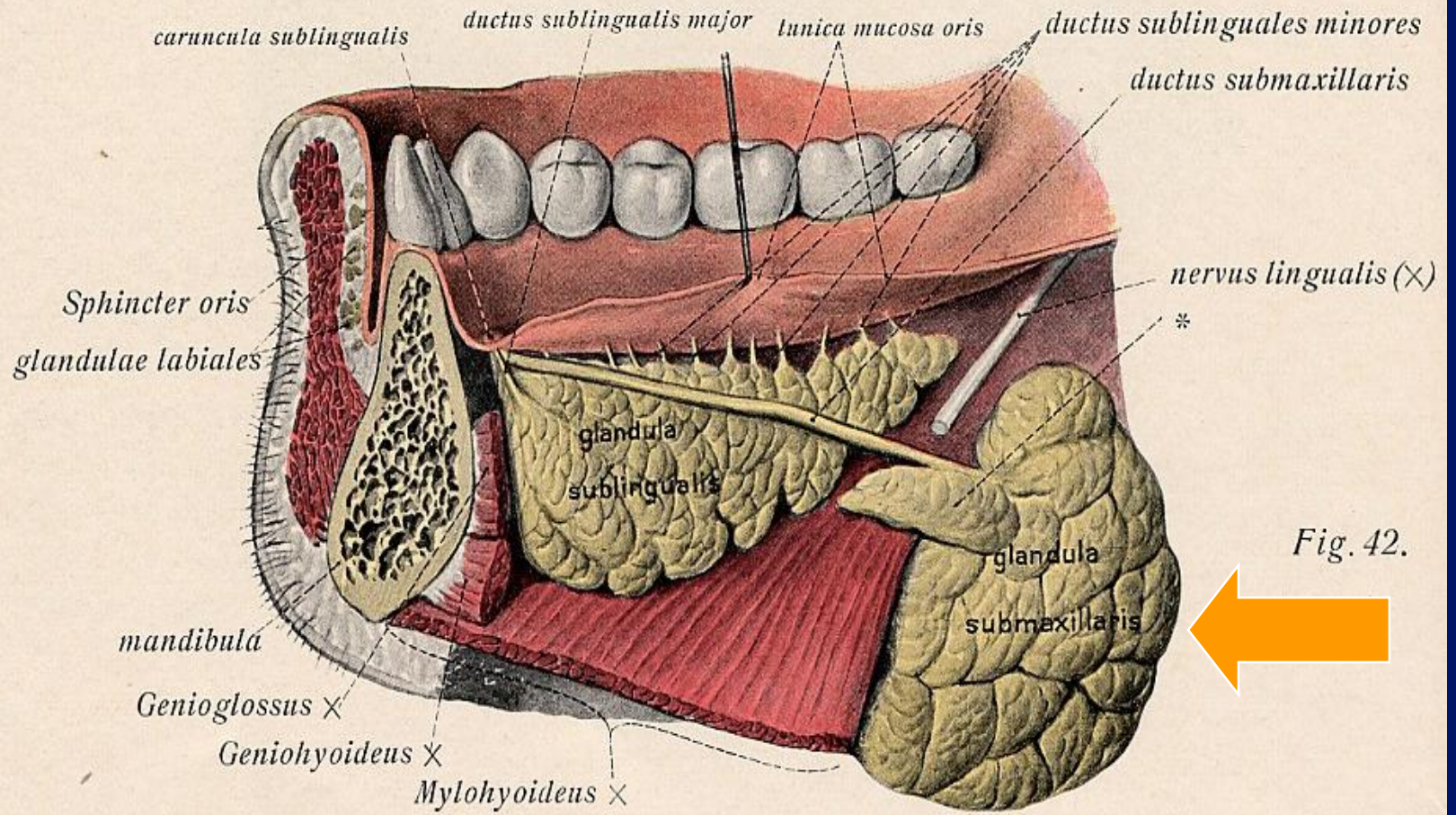


Fig. 42.

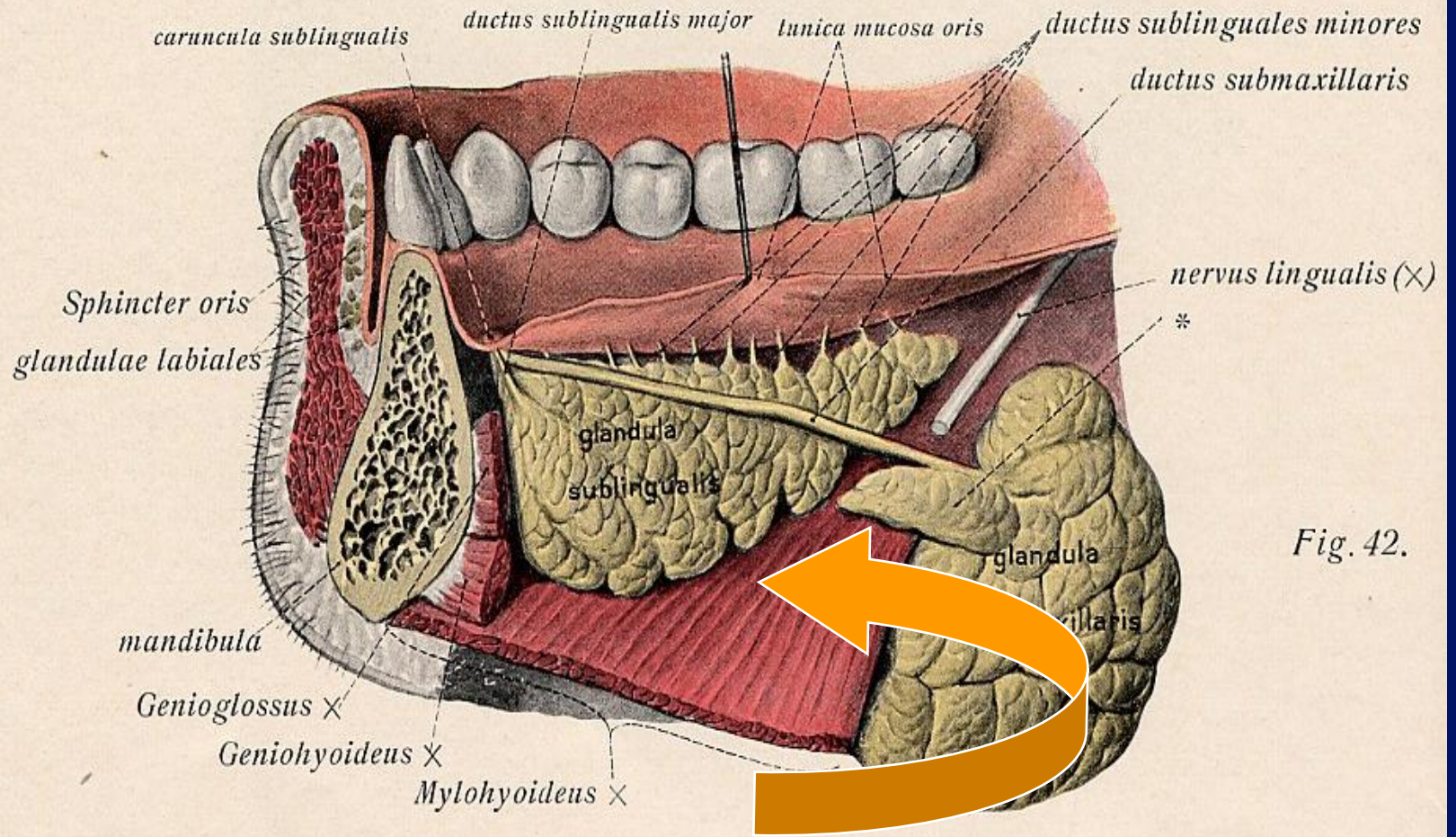


Fig. 42.

Sublingual glands.

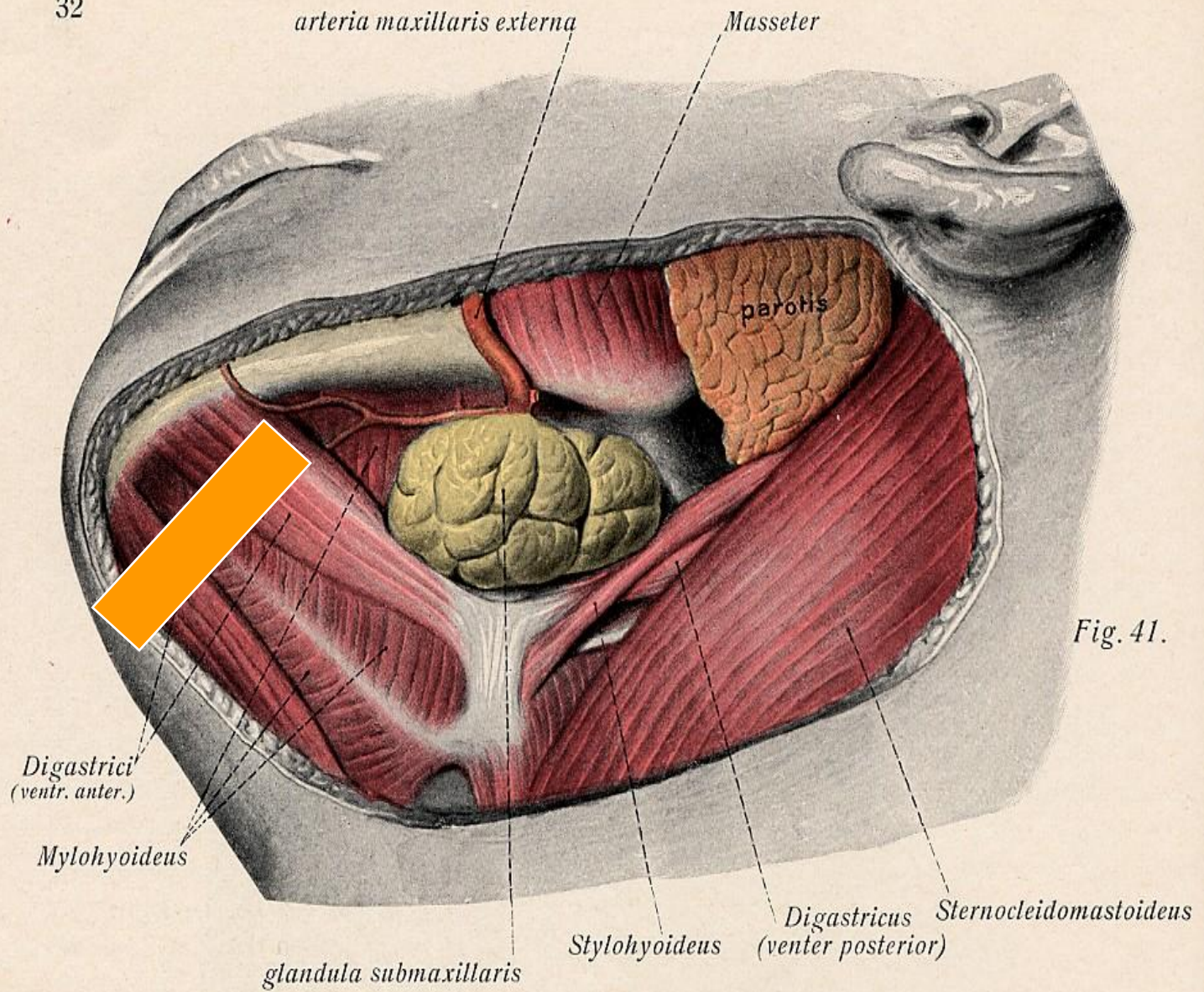

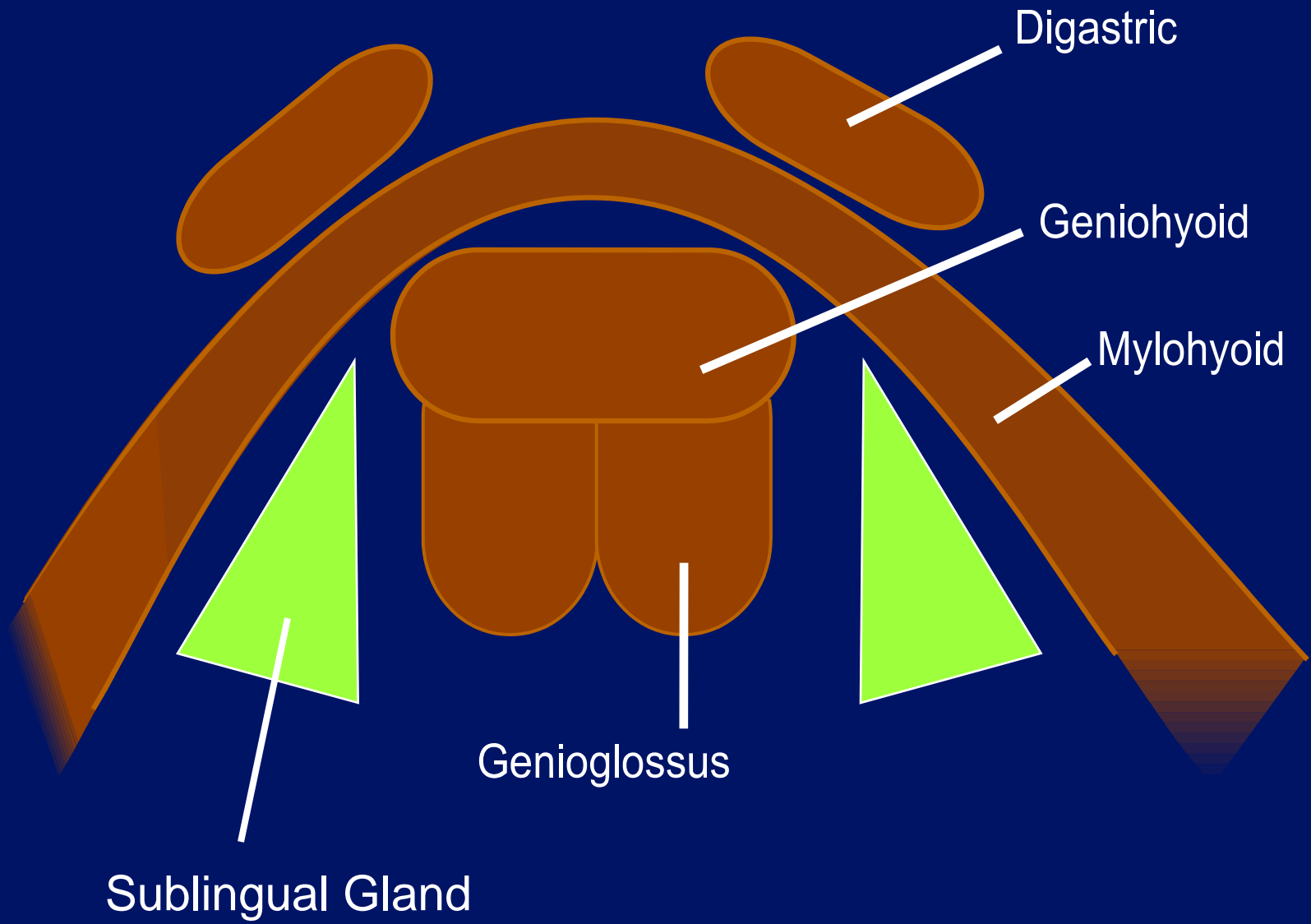

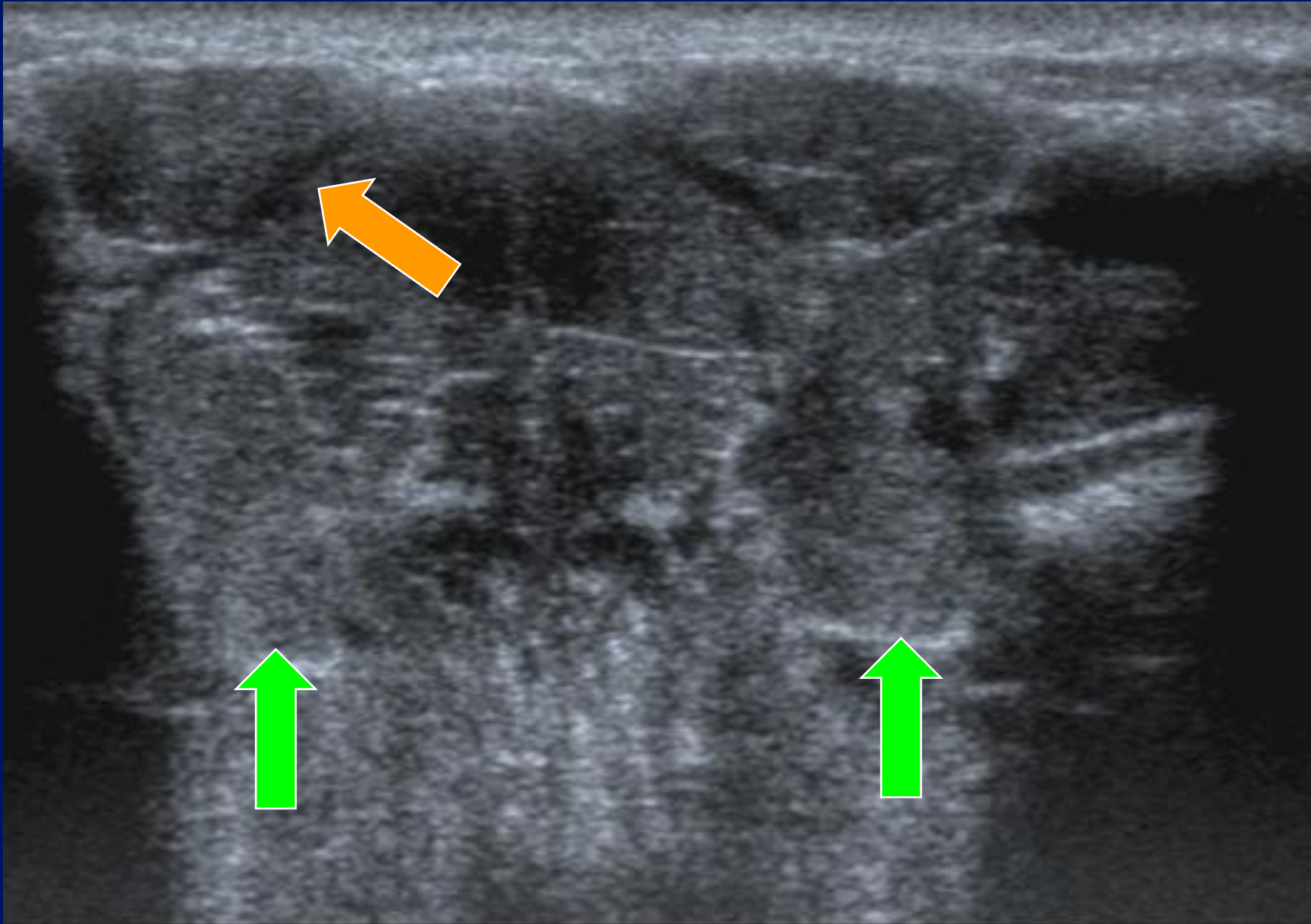


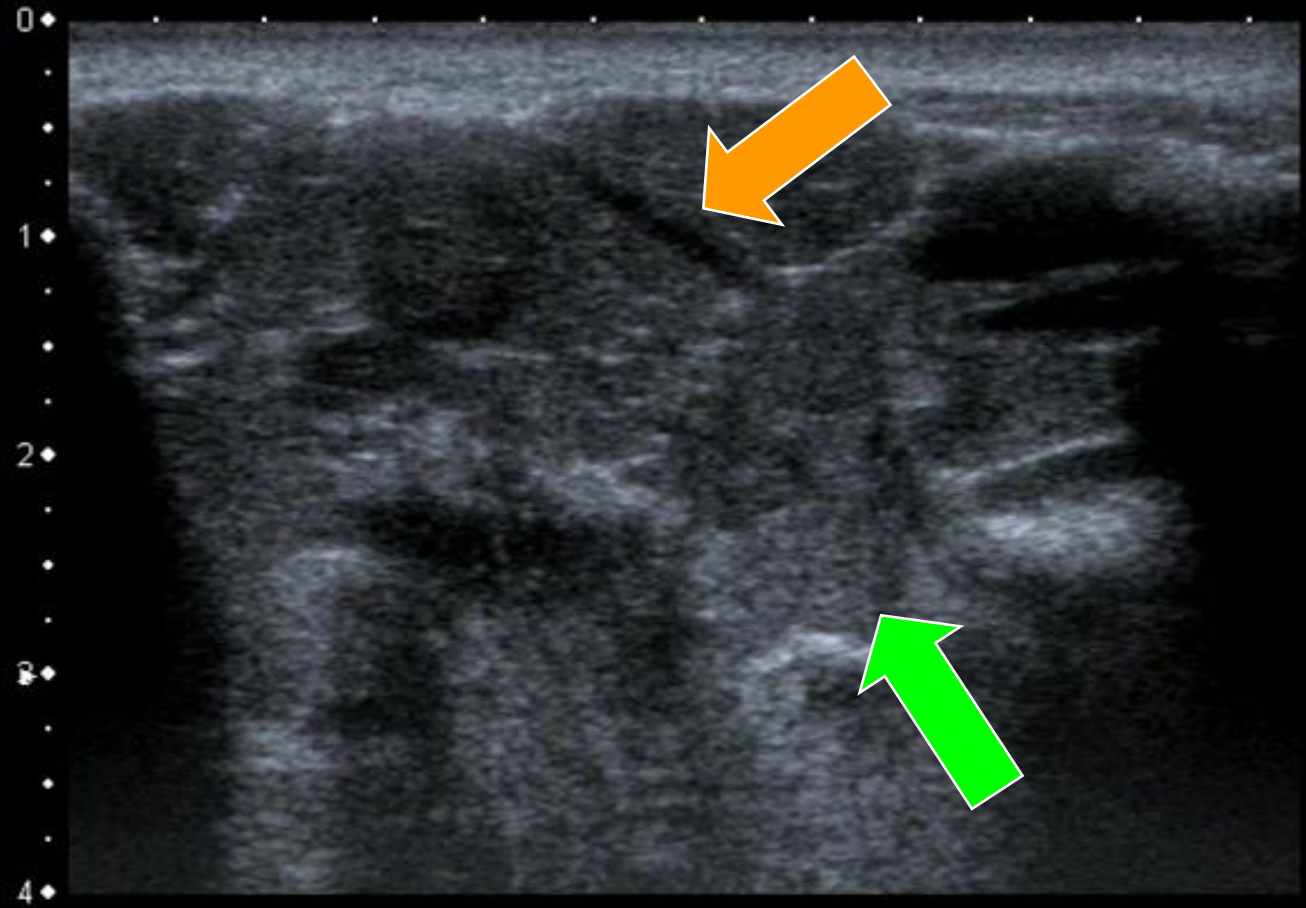
Fig. 41.








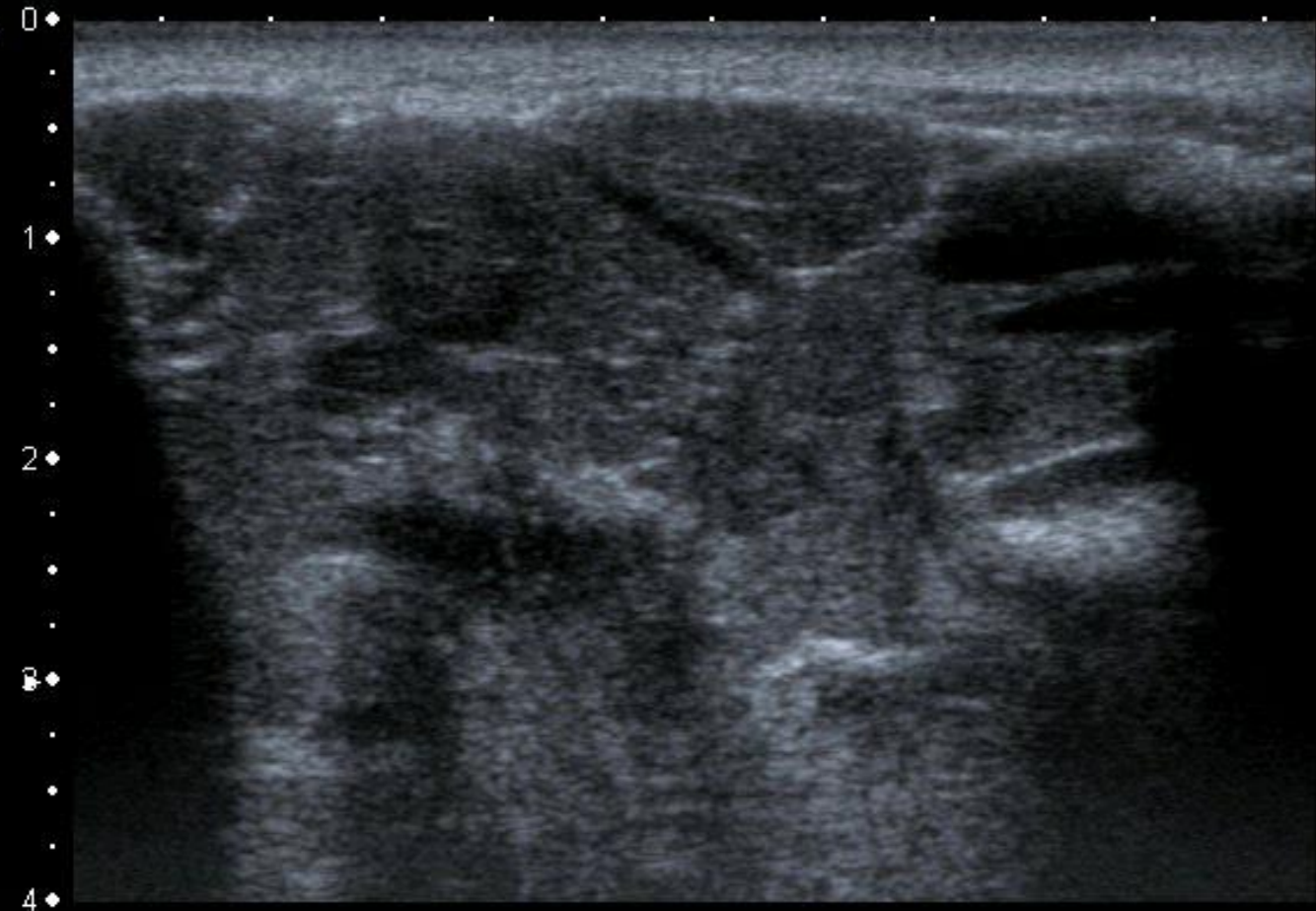




MI: 1.4  
2DG  
85  
DR  
70

12L5  
T9.0  
36 fps

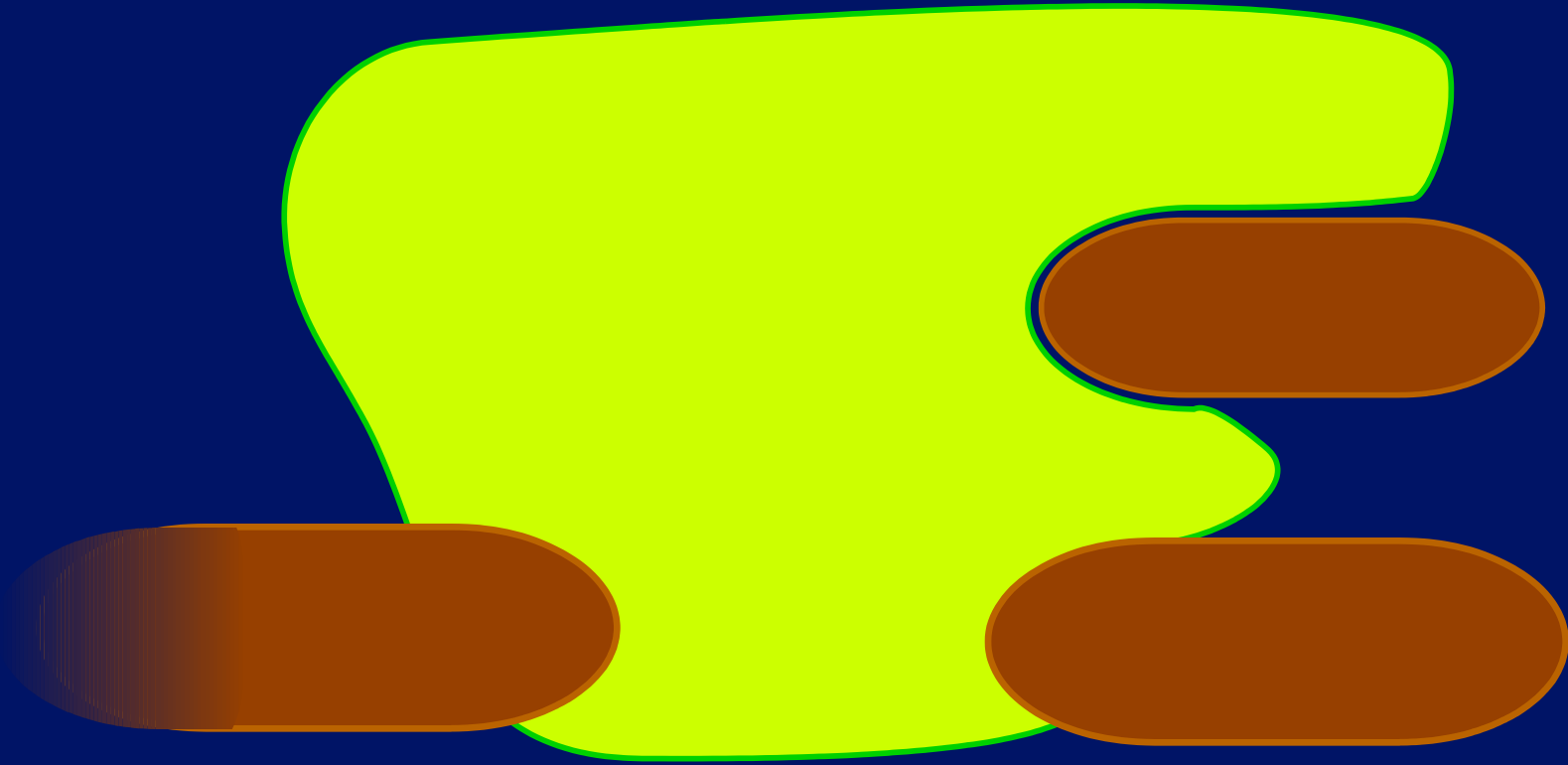


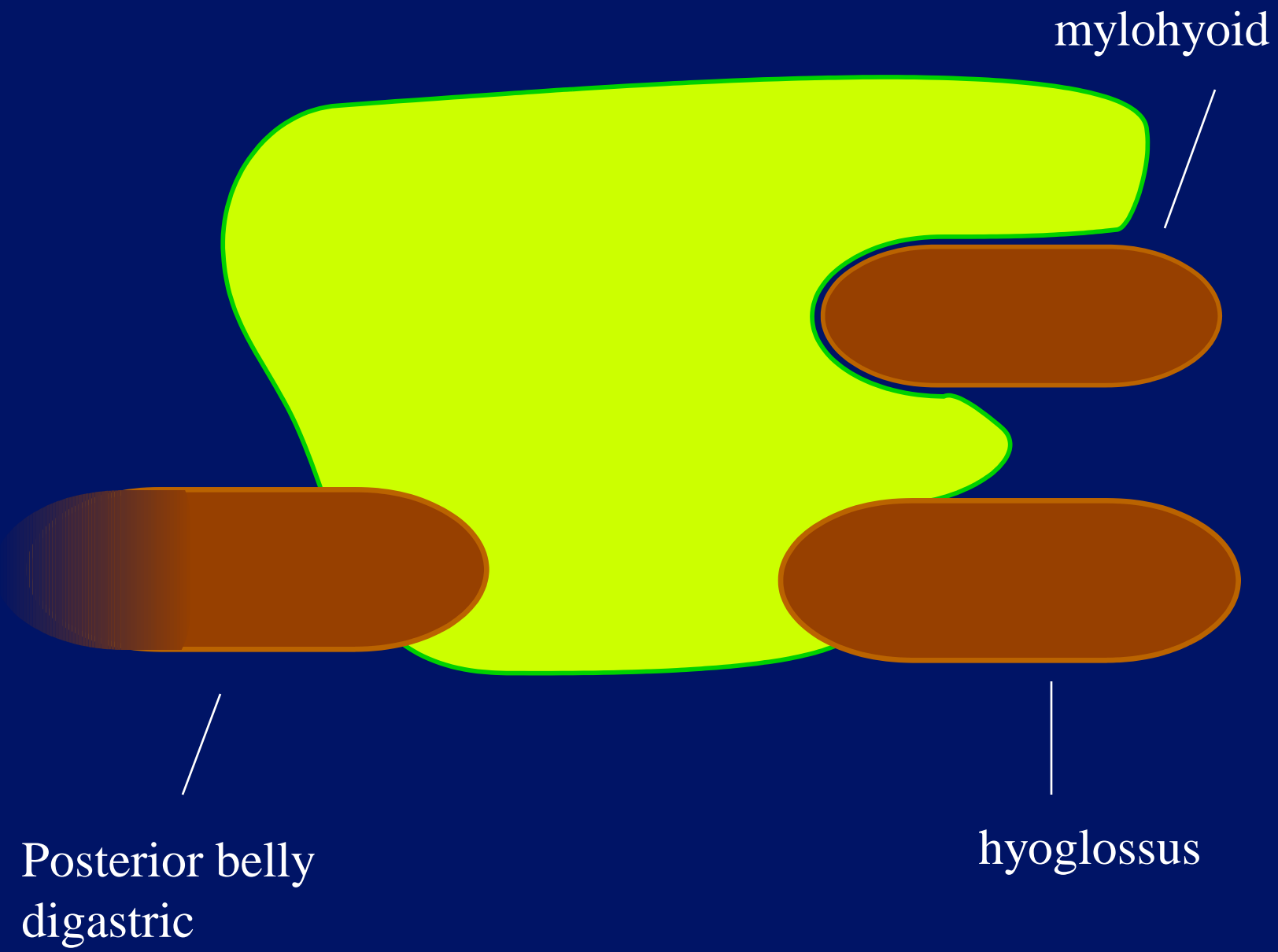


MI:1.4  
2DG  
85  
DR  
70

12L5  
T9.0  
36 fps



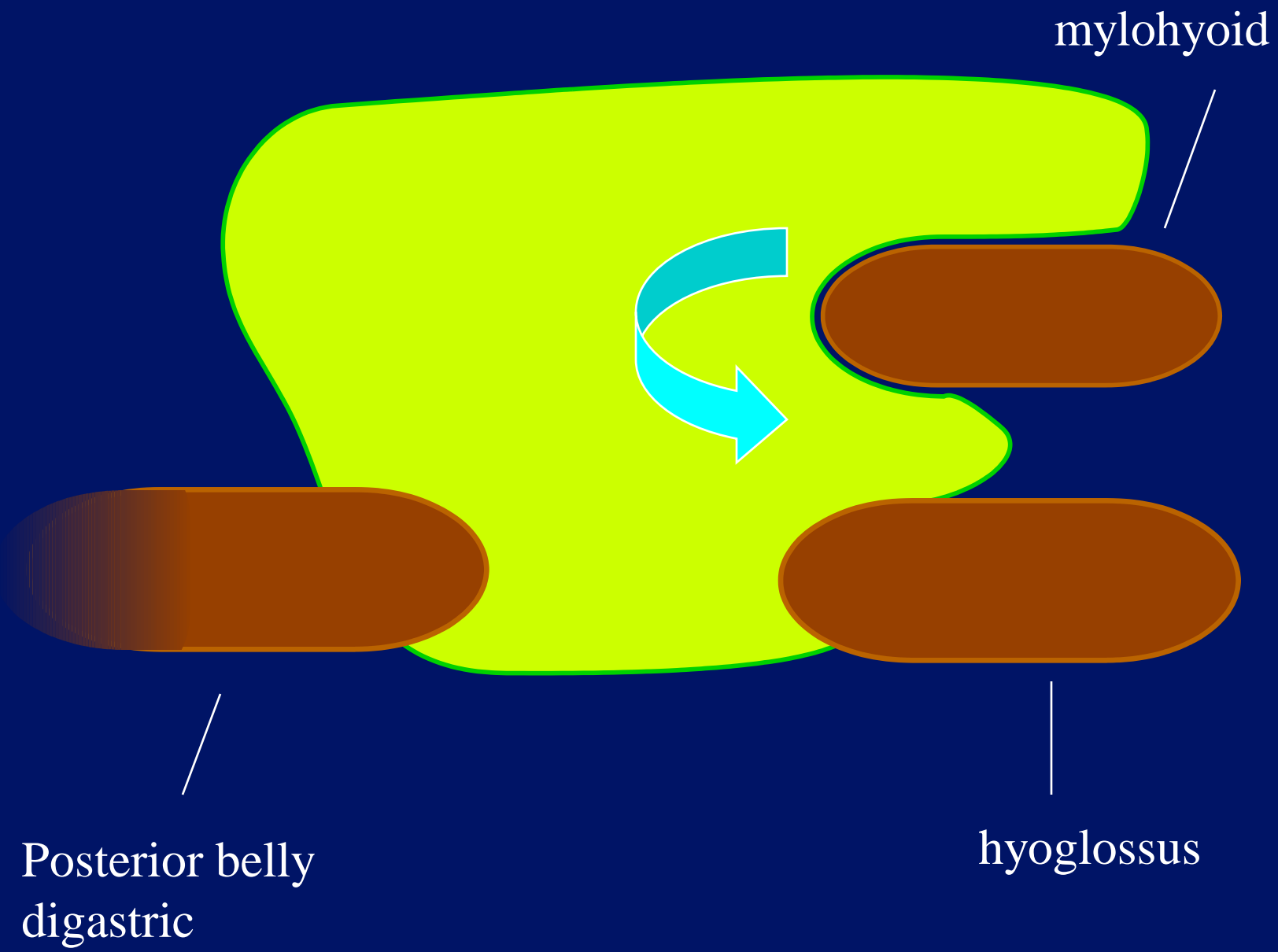





mylohyoid

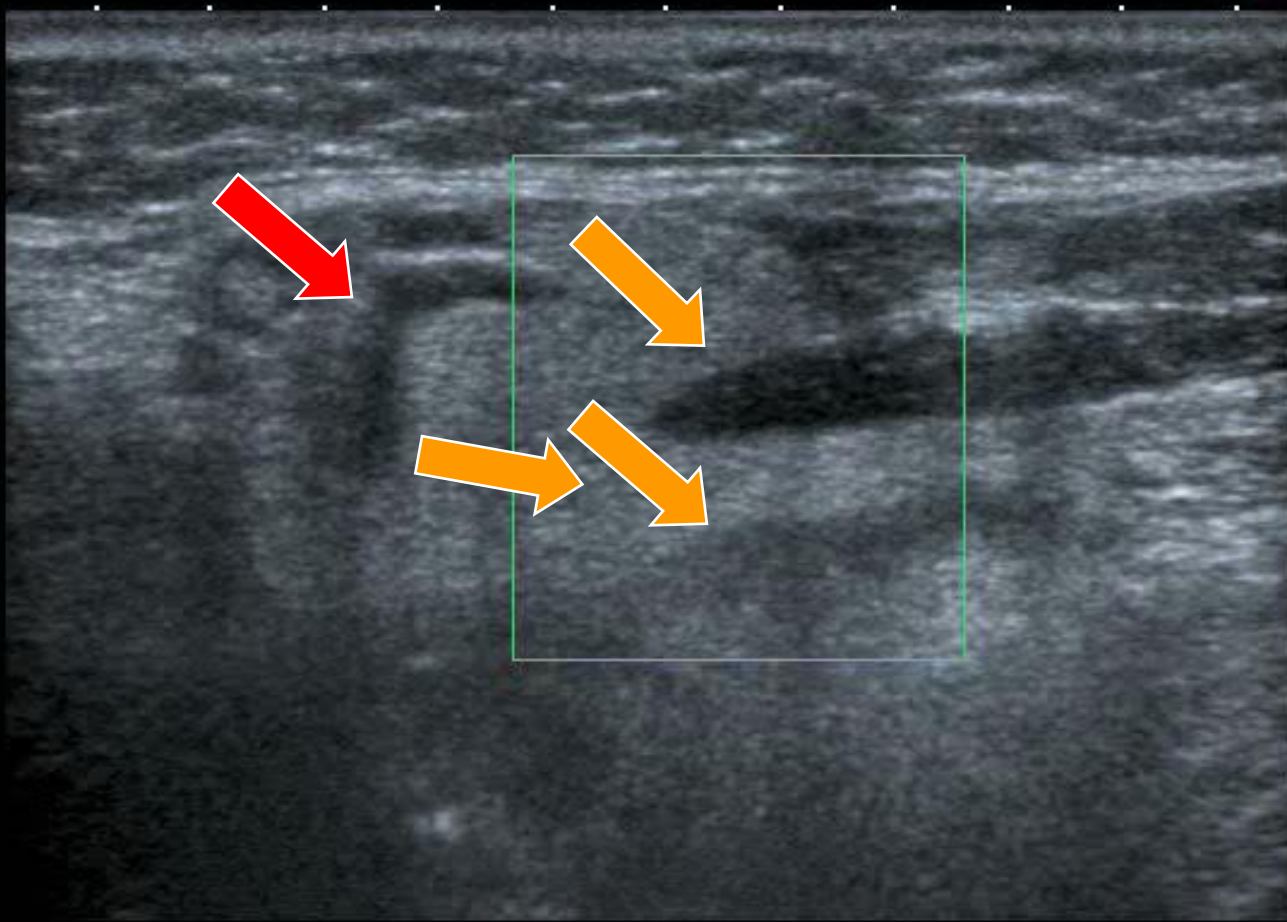
Posterior belly  
digastric

hyoglossus





T  
0  
1  
2  
3  
4



MI: 1.6  
2DG  
79  
DR  
65  
CG  
41  
PRF  
15.6k  
Filter  
5

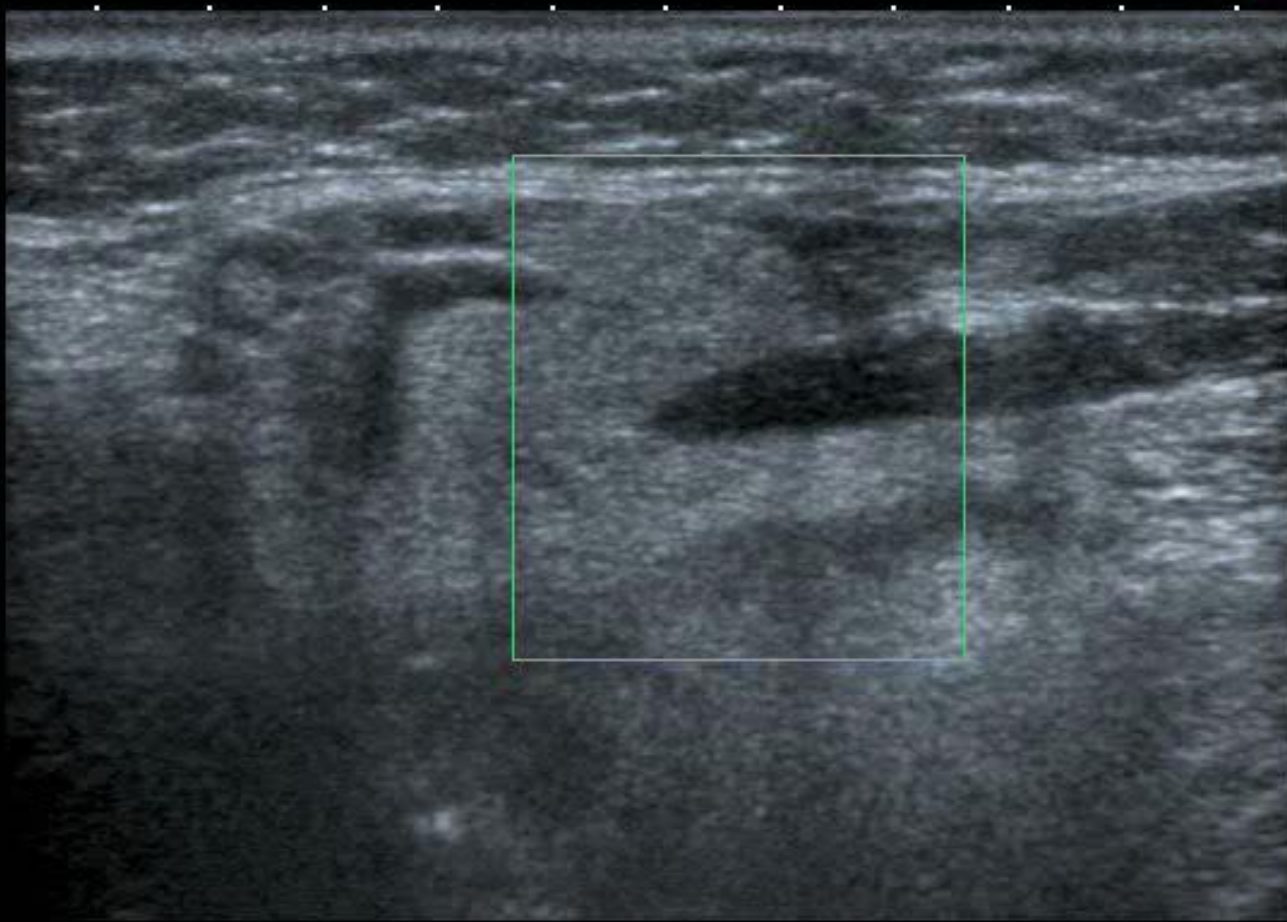12L5  
T9.0  
CF 7.2  
16 fps

APure

8.5  
8.5  
cm/s

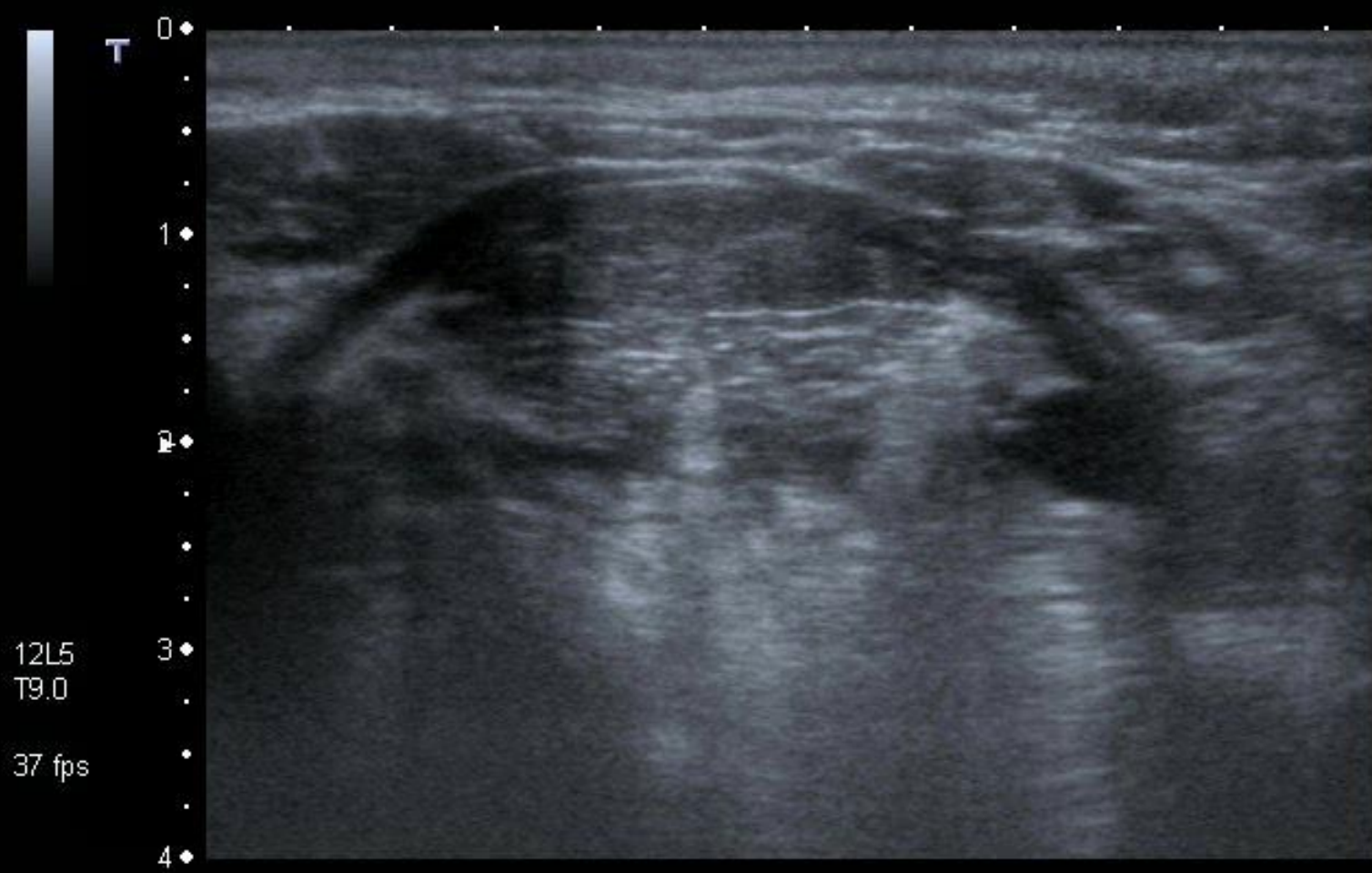
T

0  
1  
2  
3  
4

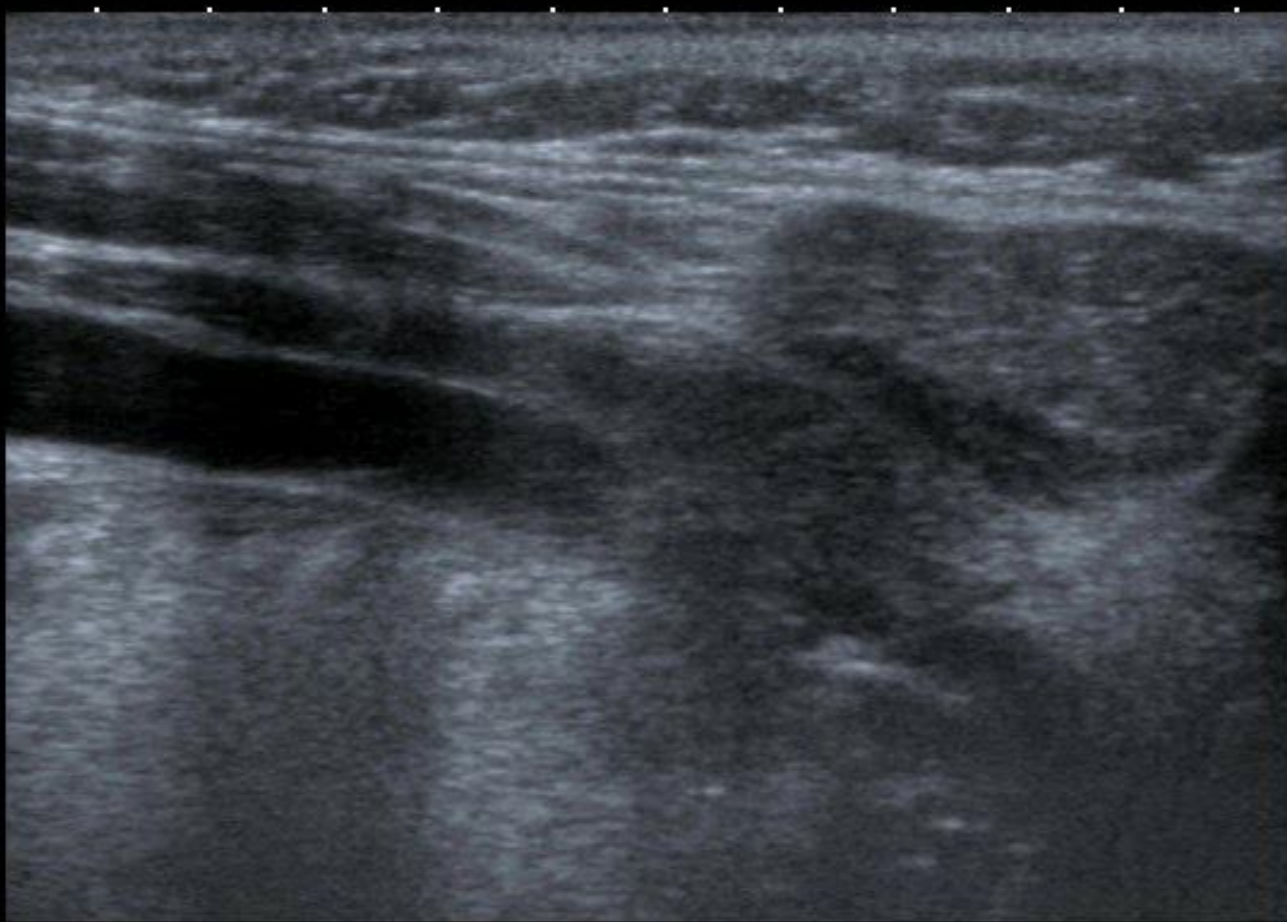


MI: 1.6  
2DG  
79  
DR  
65  
CG  
41  
PRF  
15.6k  
Filter  
5

12L5  
T9.0  
CF 7.2  
16 fps




T  
0  
1  
2  
3  
4



MI: 1.6  
2DG  
85  
DR  
70

12L5  
T9.0  
37 fps







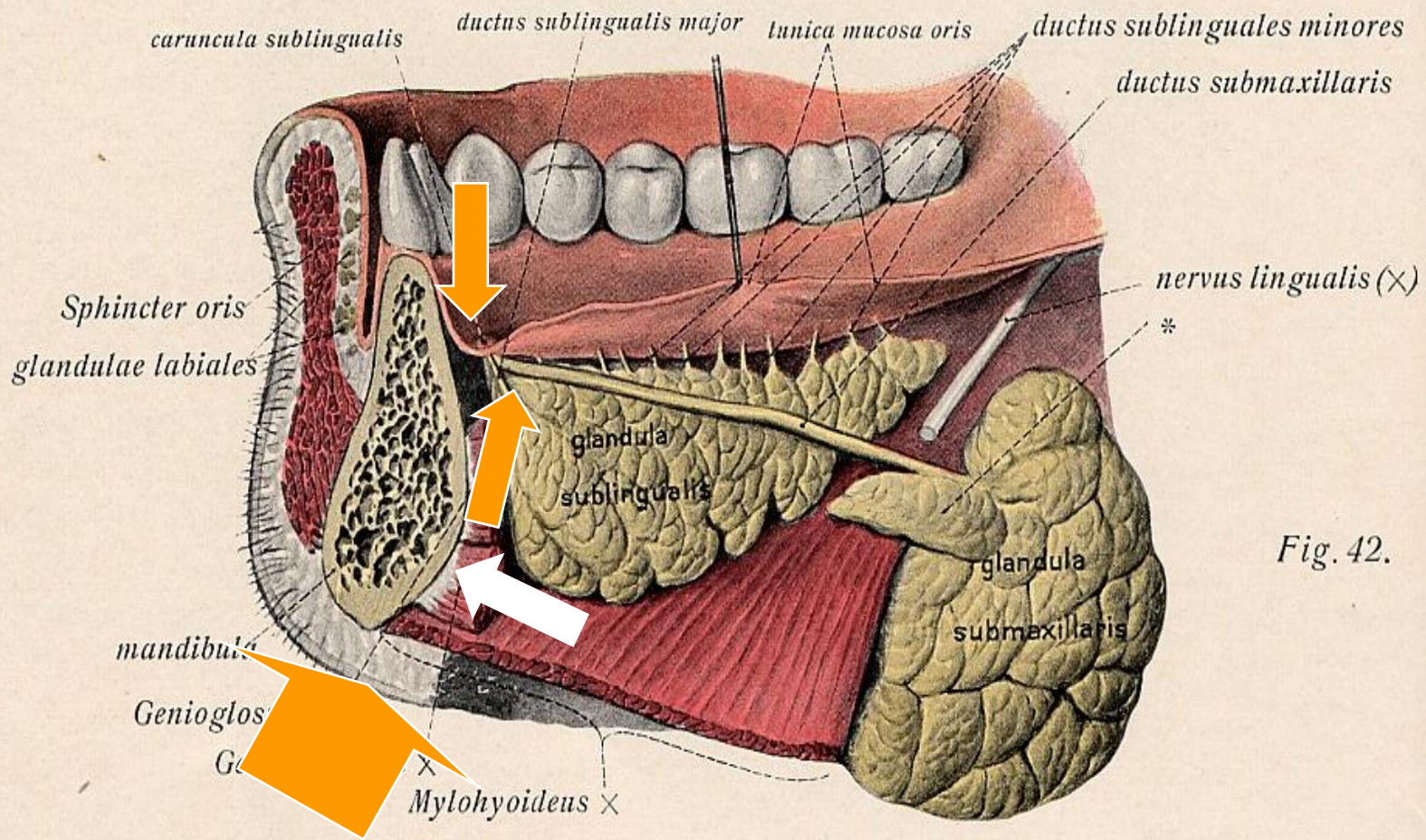
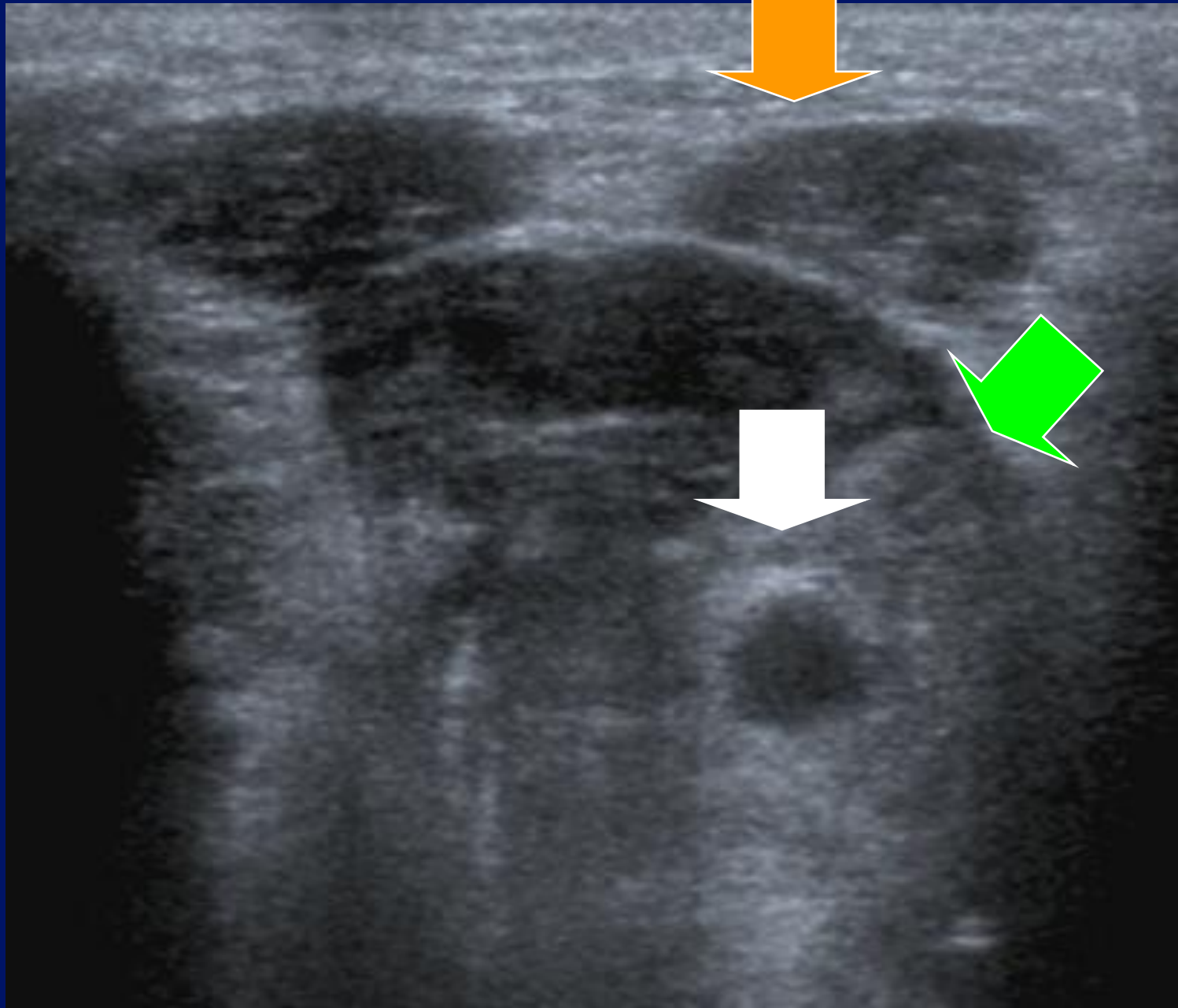


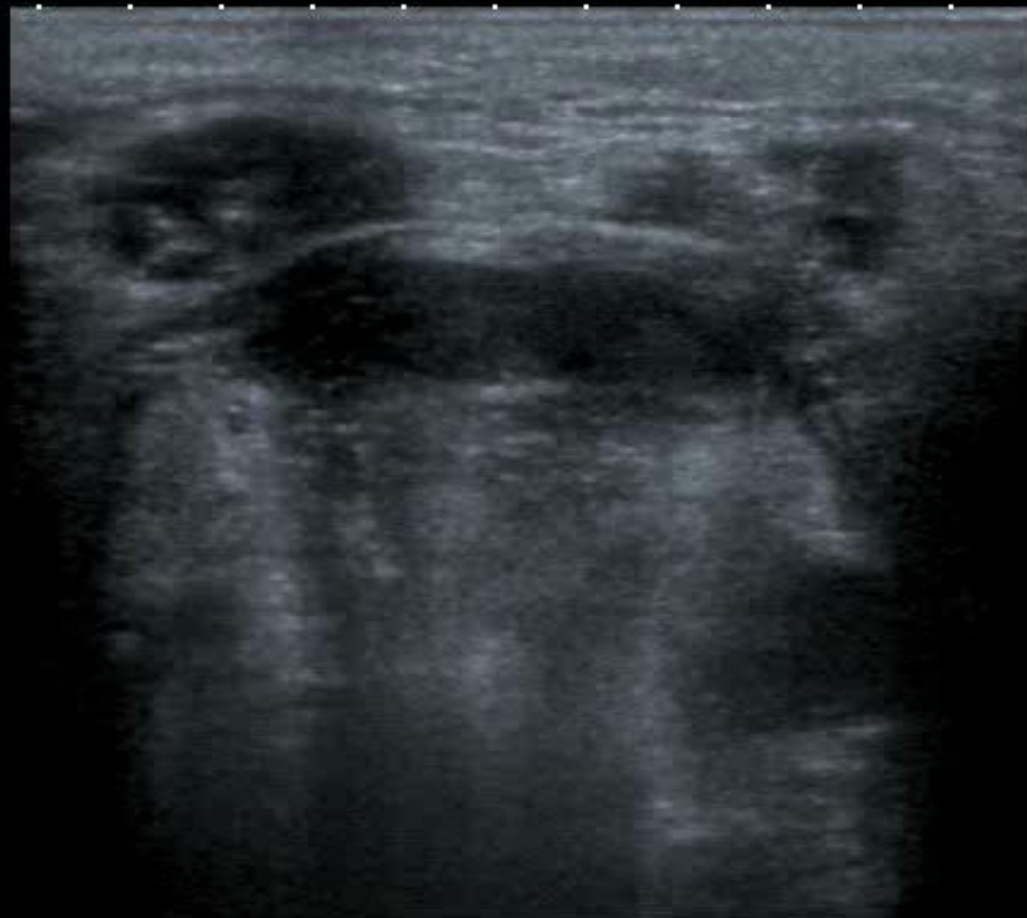Fig. 42.



APure



0 ♦ T  
.  
.  
2 ♦  
.  
▼  
.  
4 ♦  
.  
.  
.



MI: 1.6  
2DG  
97  
DR  
70

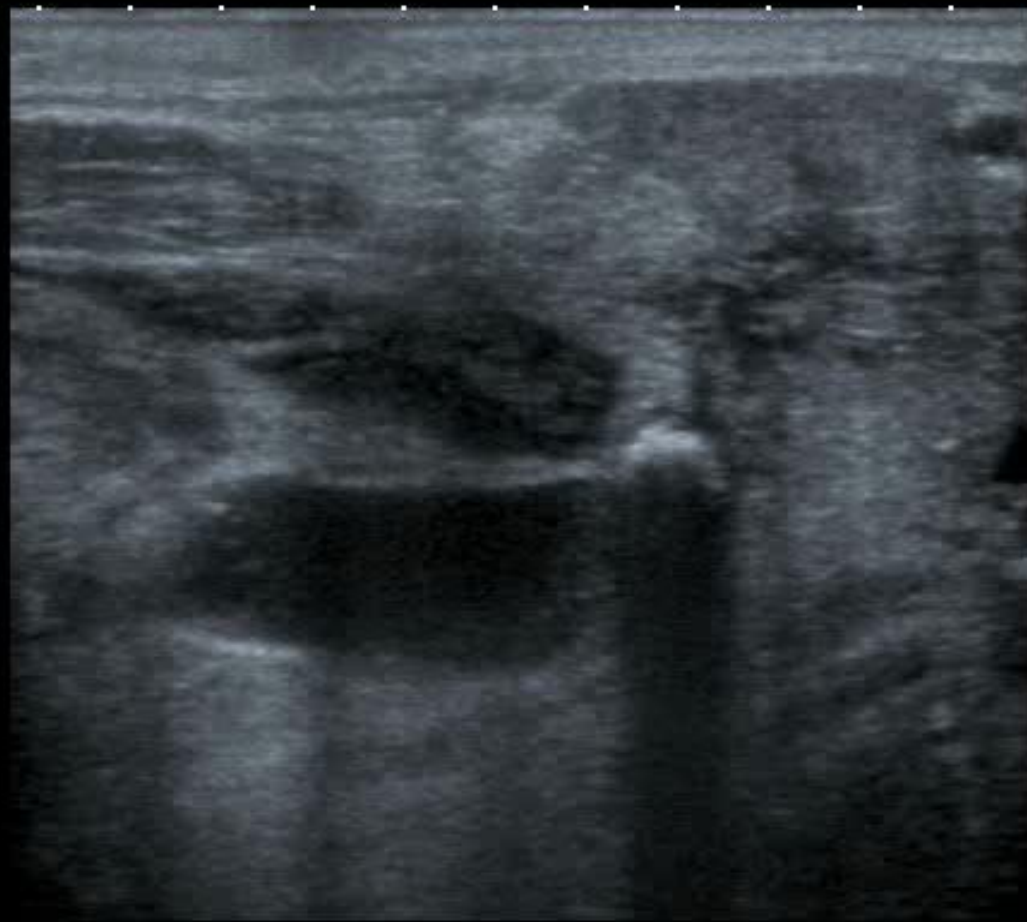12L5  
T9.0  
18 fps



APure



0 ♦ T  
.  
.  
2 ♦  
.  
▼ ♦  
.  
4 ♦  
.  
.  
.



MI: 1.6  
2DG  
97  
DR  
70

12L5  
T9.0  
18 fps



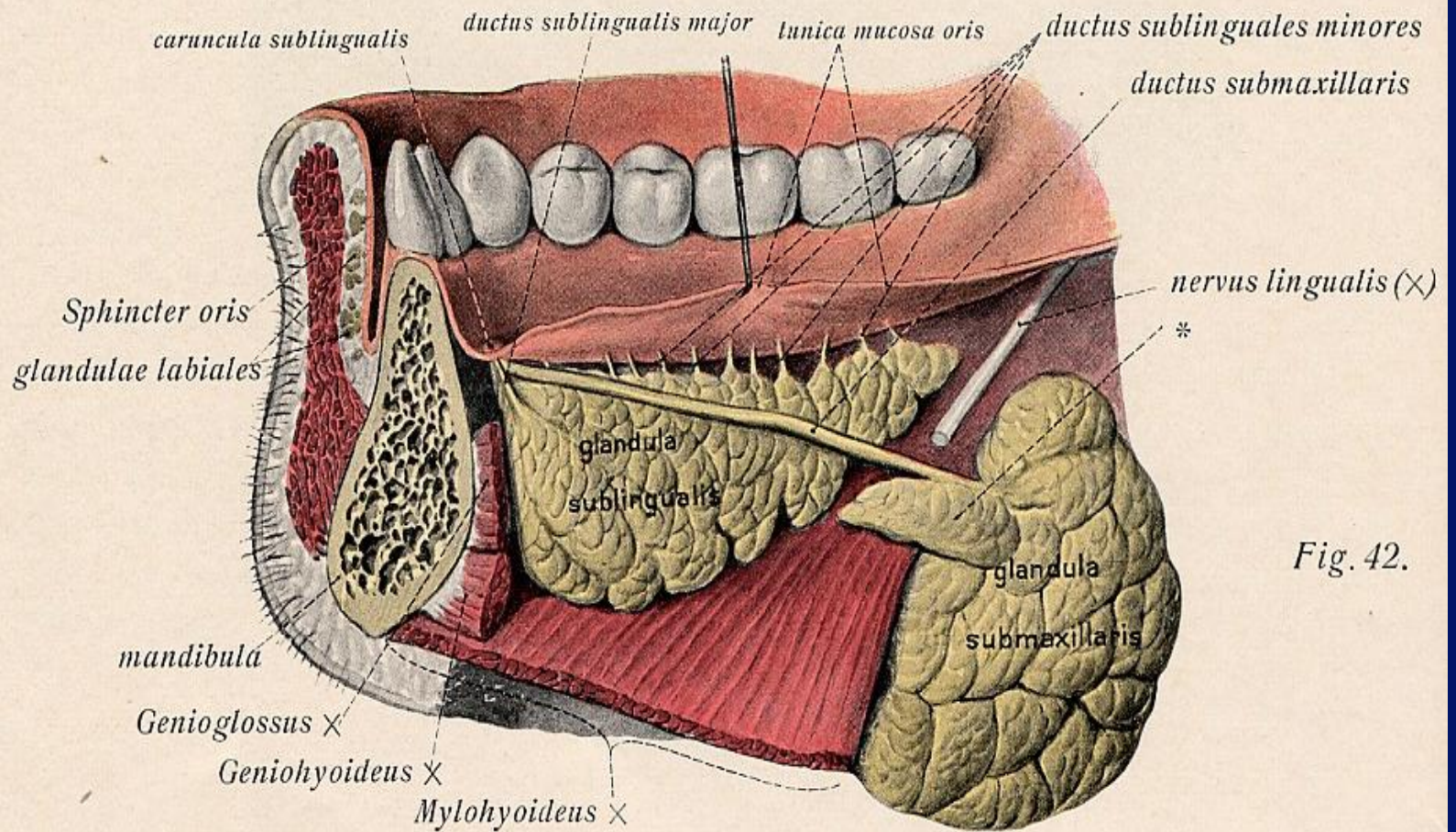


Fig. 42.

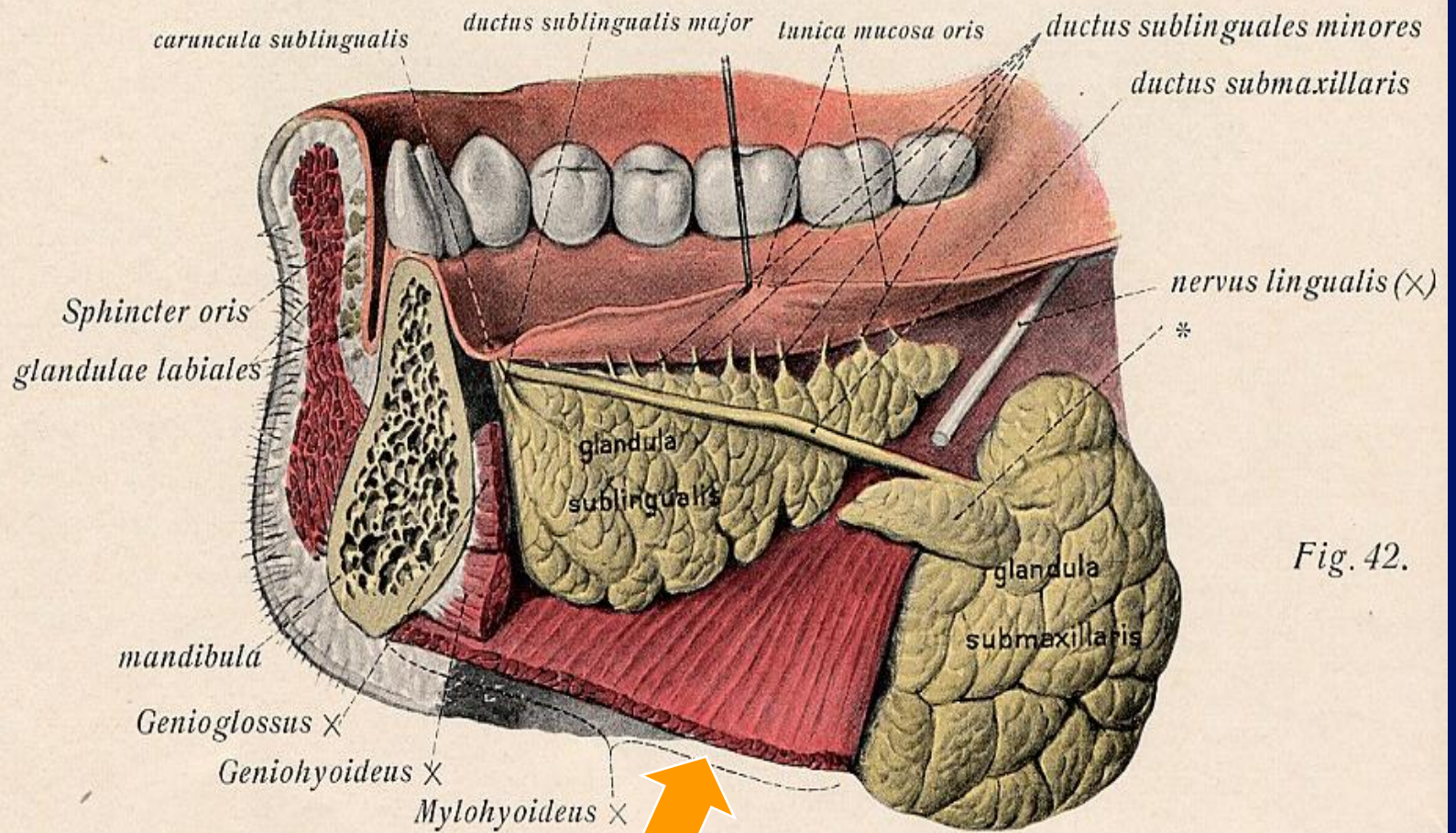


Fig. 42.

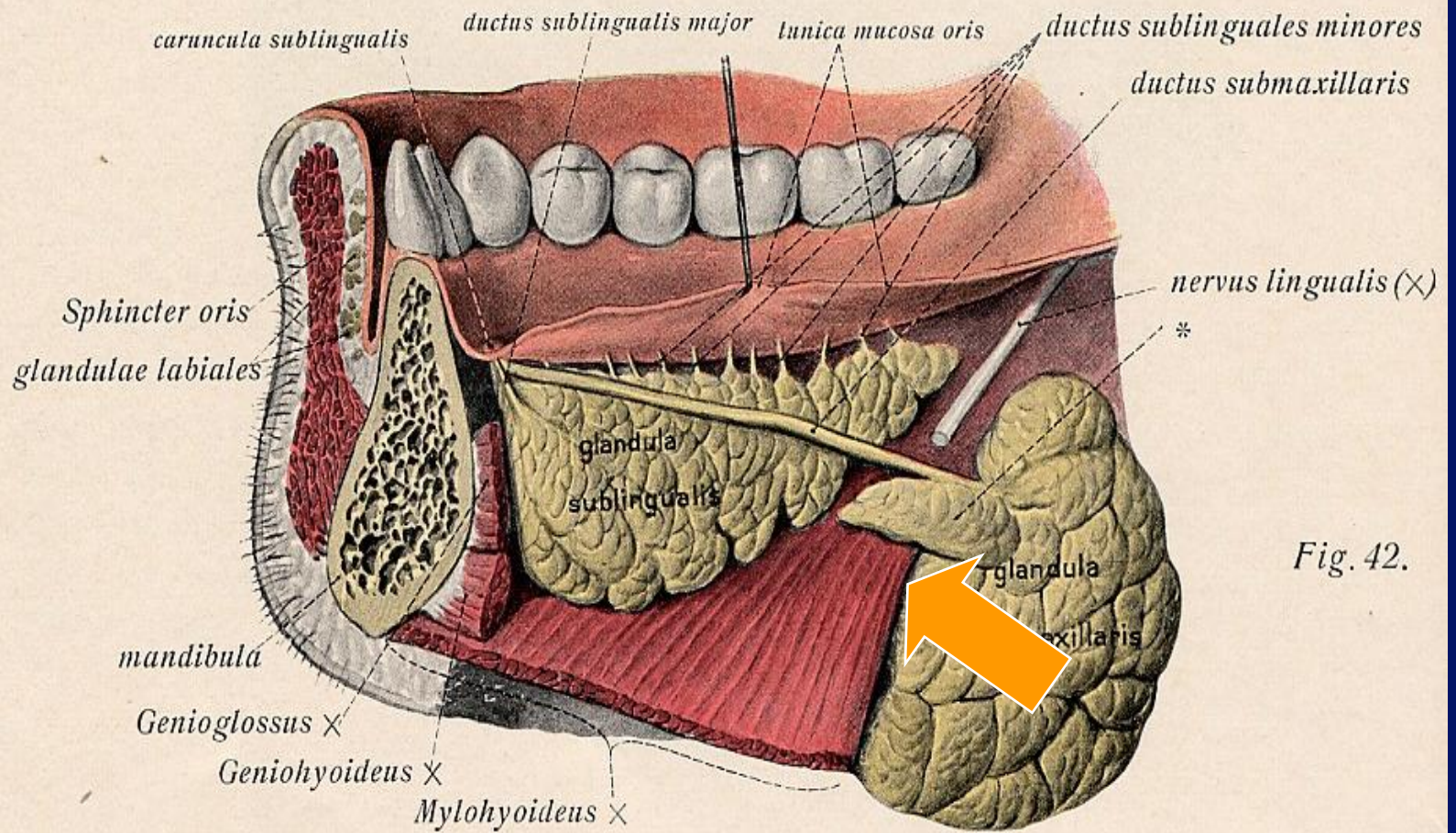


Fig. 42.

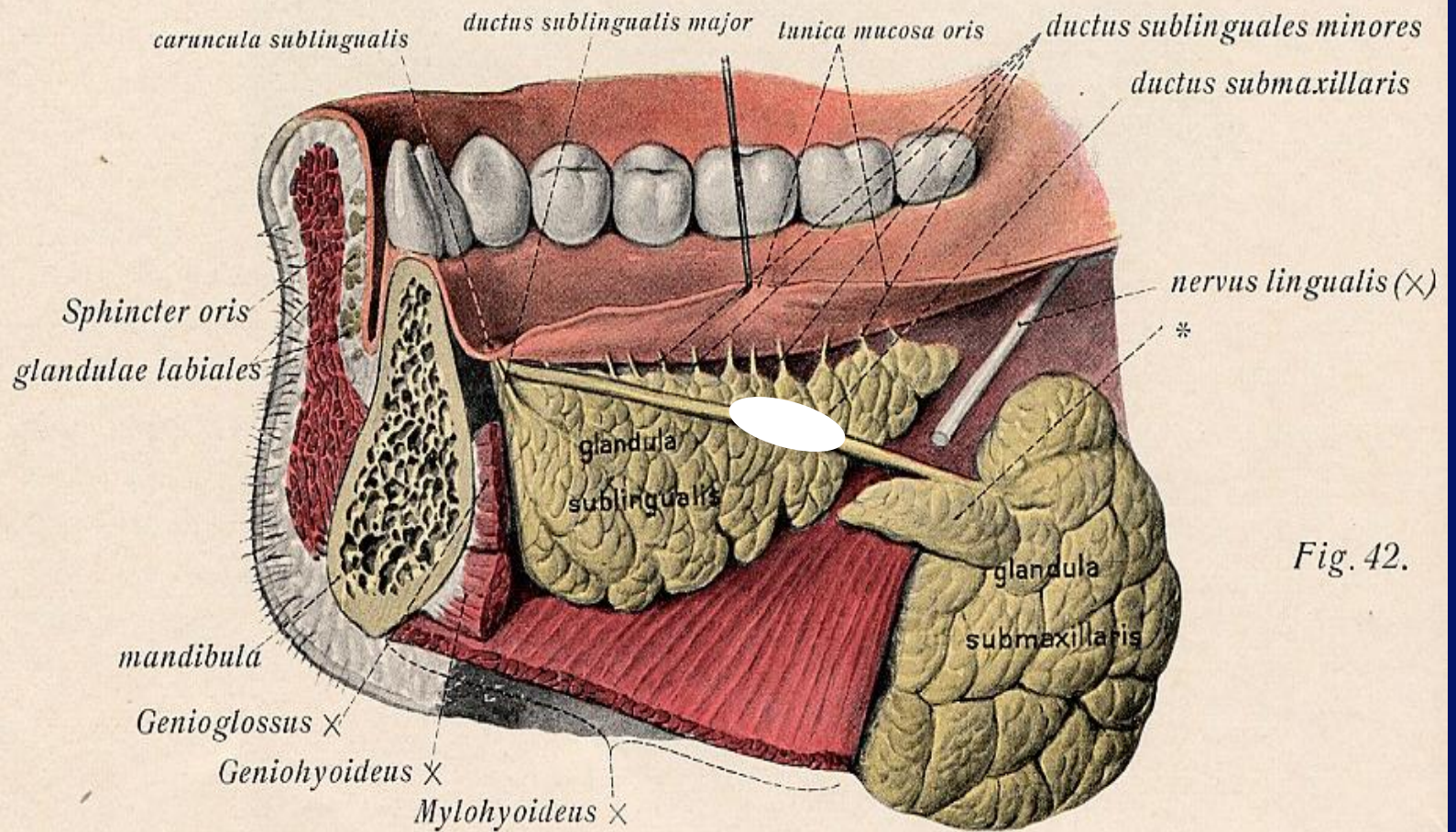


Fig. 42.

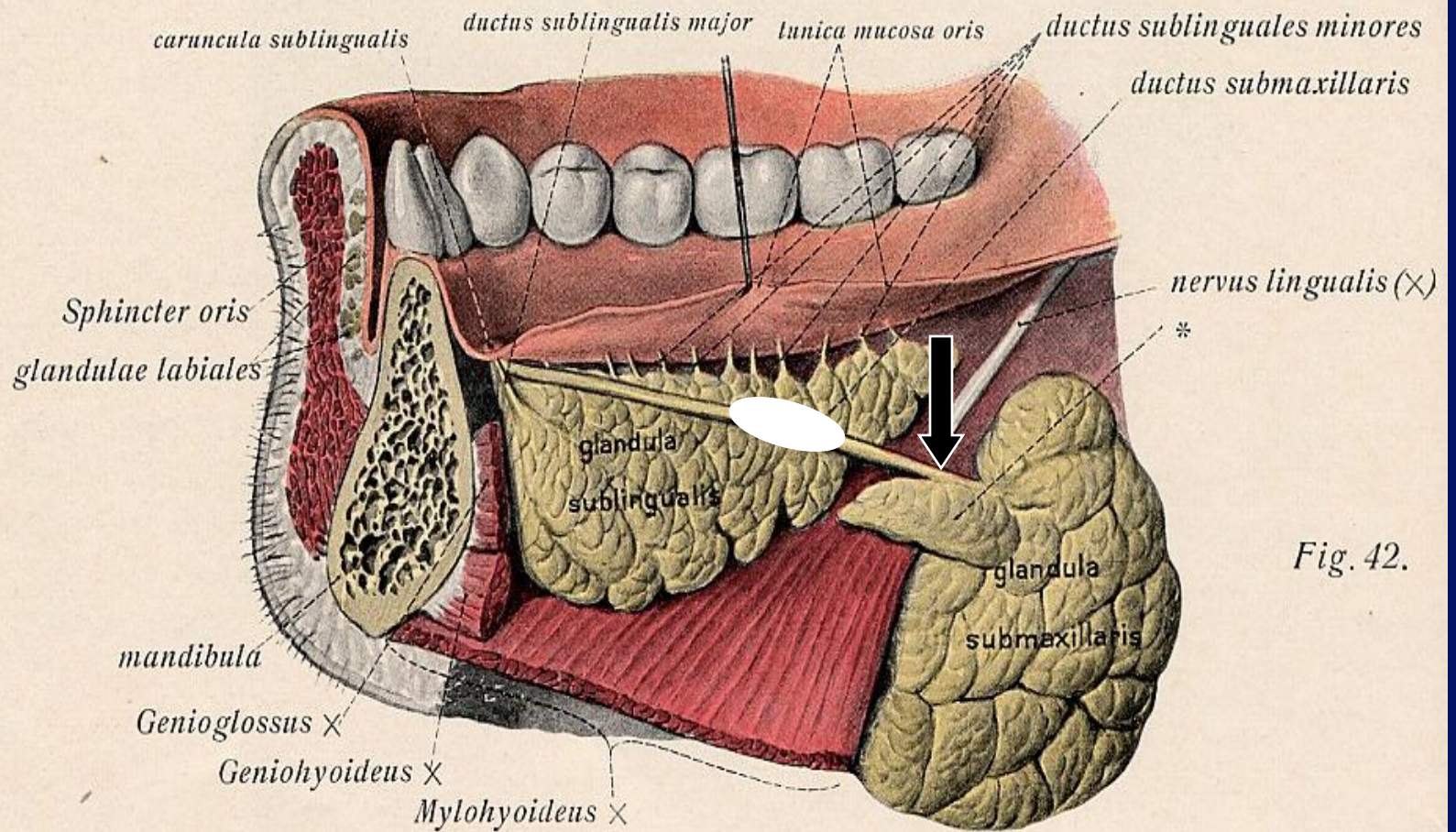


Fig. 42.

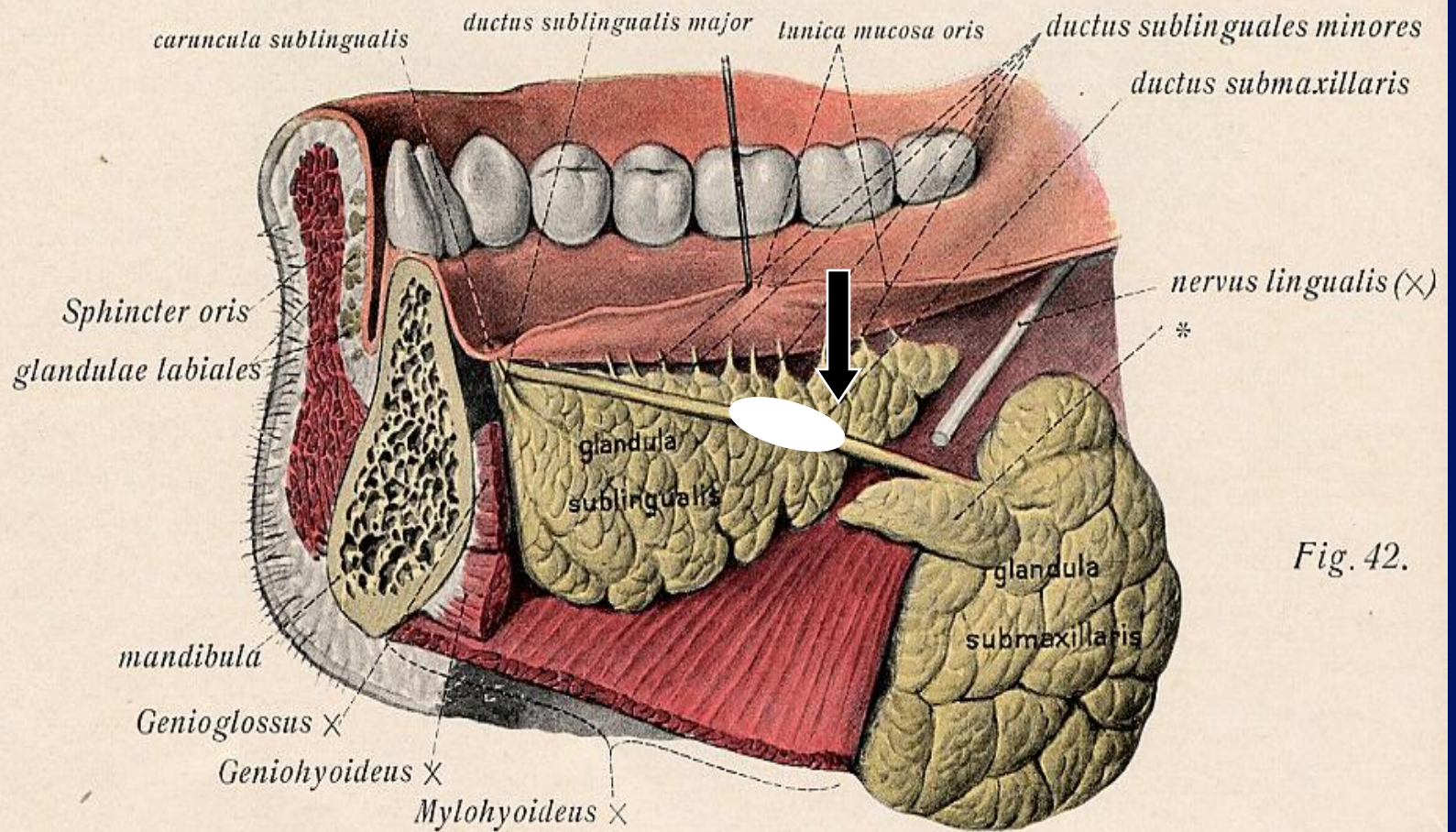


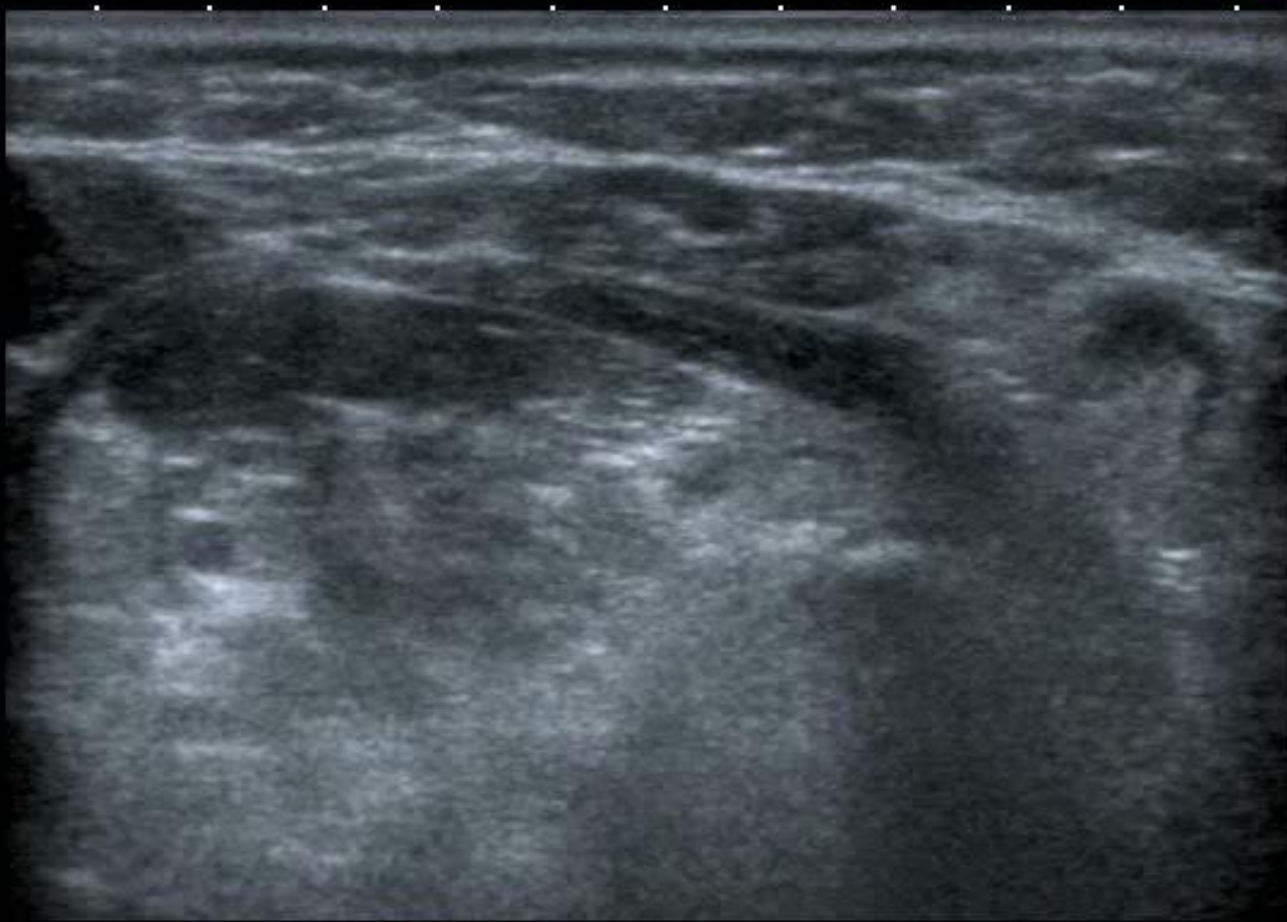Fig. 42.

APure

T  
0  
1  
2  
3  
4

12L5  
T9.0

16 fps



MI: 1.6  
2DG  
79  
DR  
65

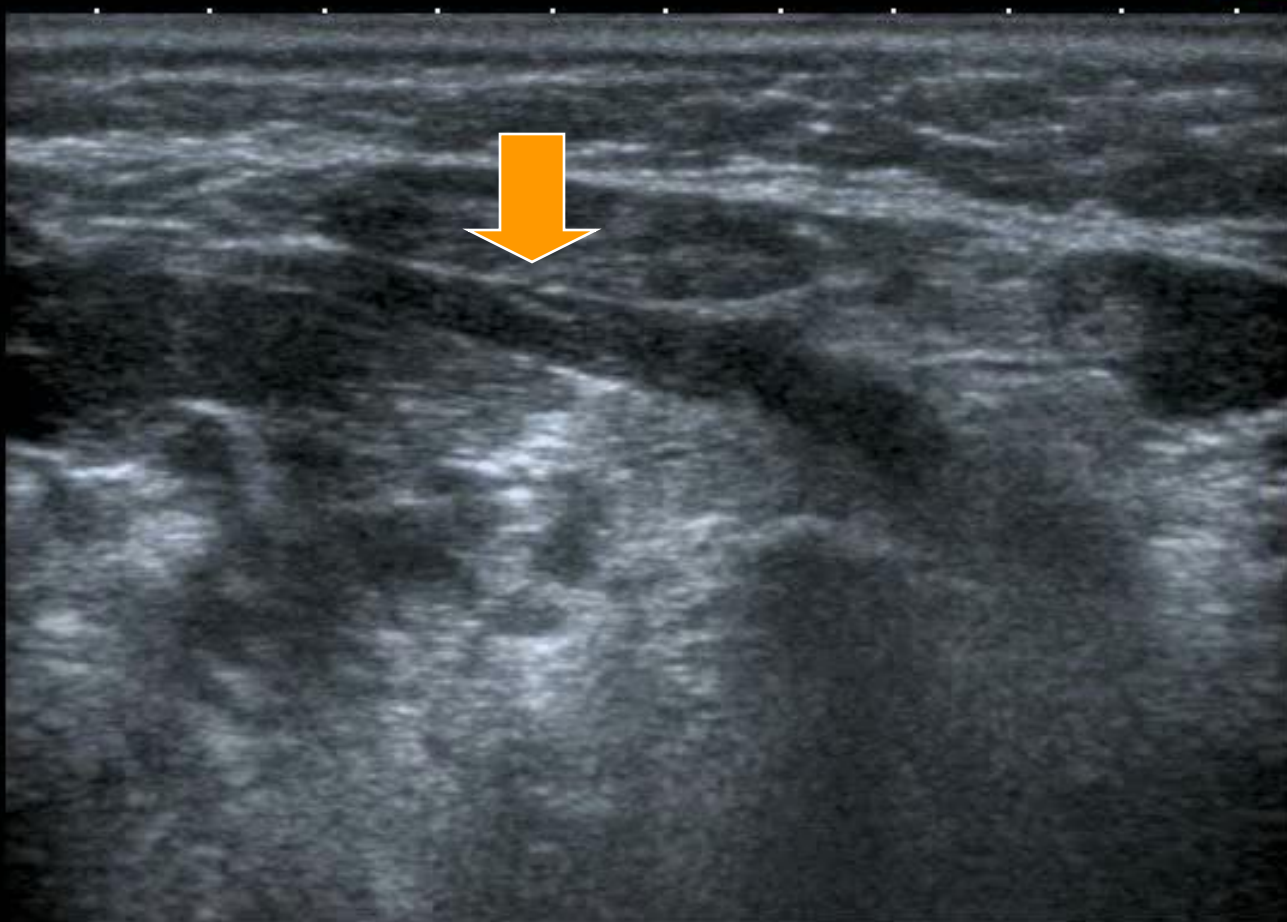


APure

T  
0  
1  
2  
3  
4

12L5  
T9.0

16 fps



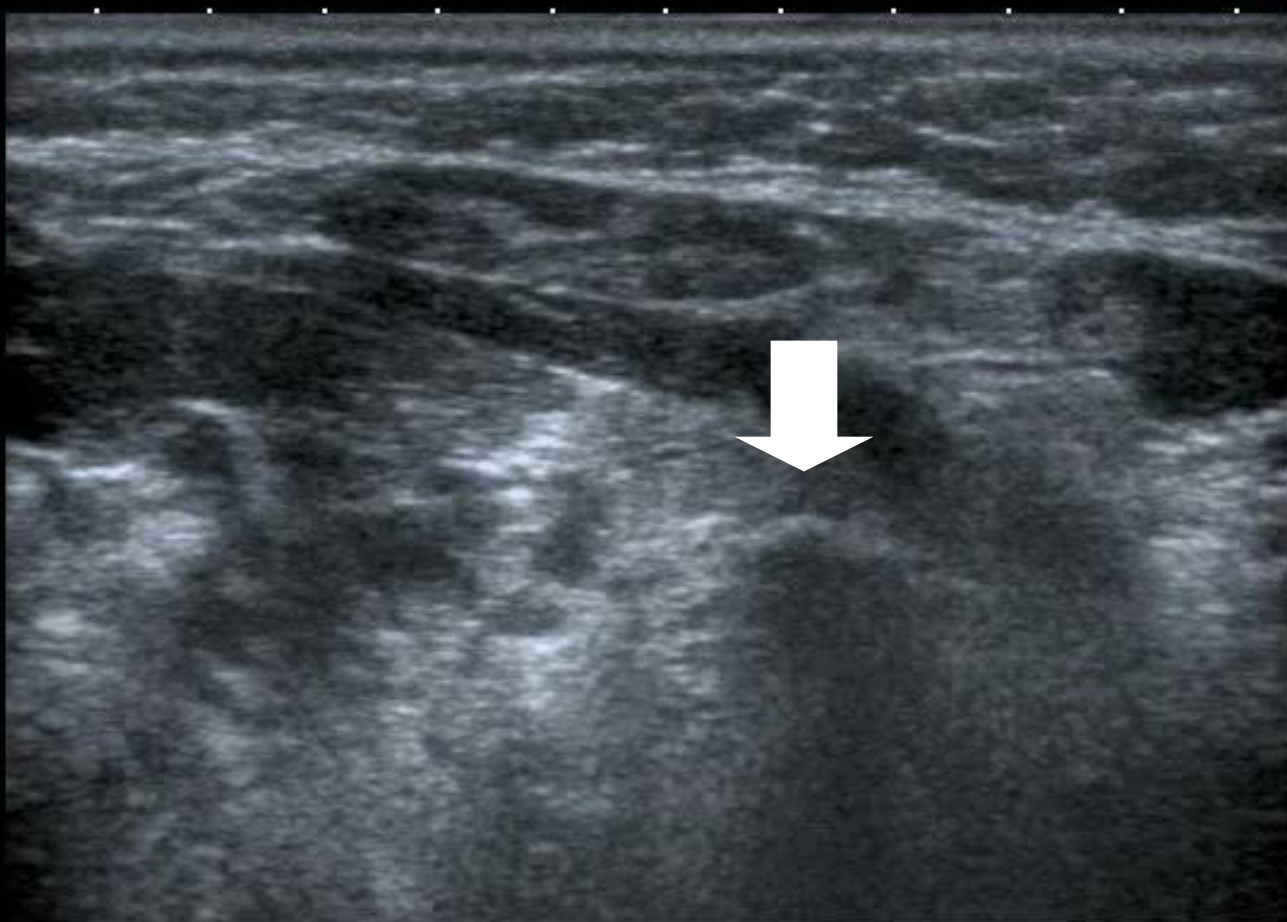
MI: 1.6  
2DG  
79  
DR  
65

APure

T  
0  
1  
2  
3  
4

12L5  
T9.0

16 fps



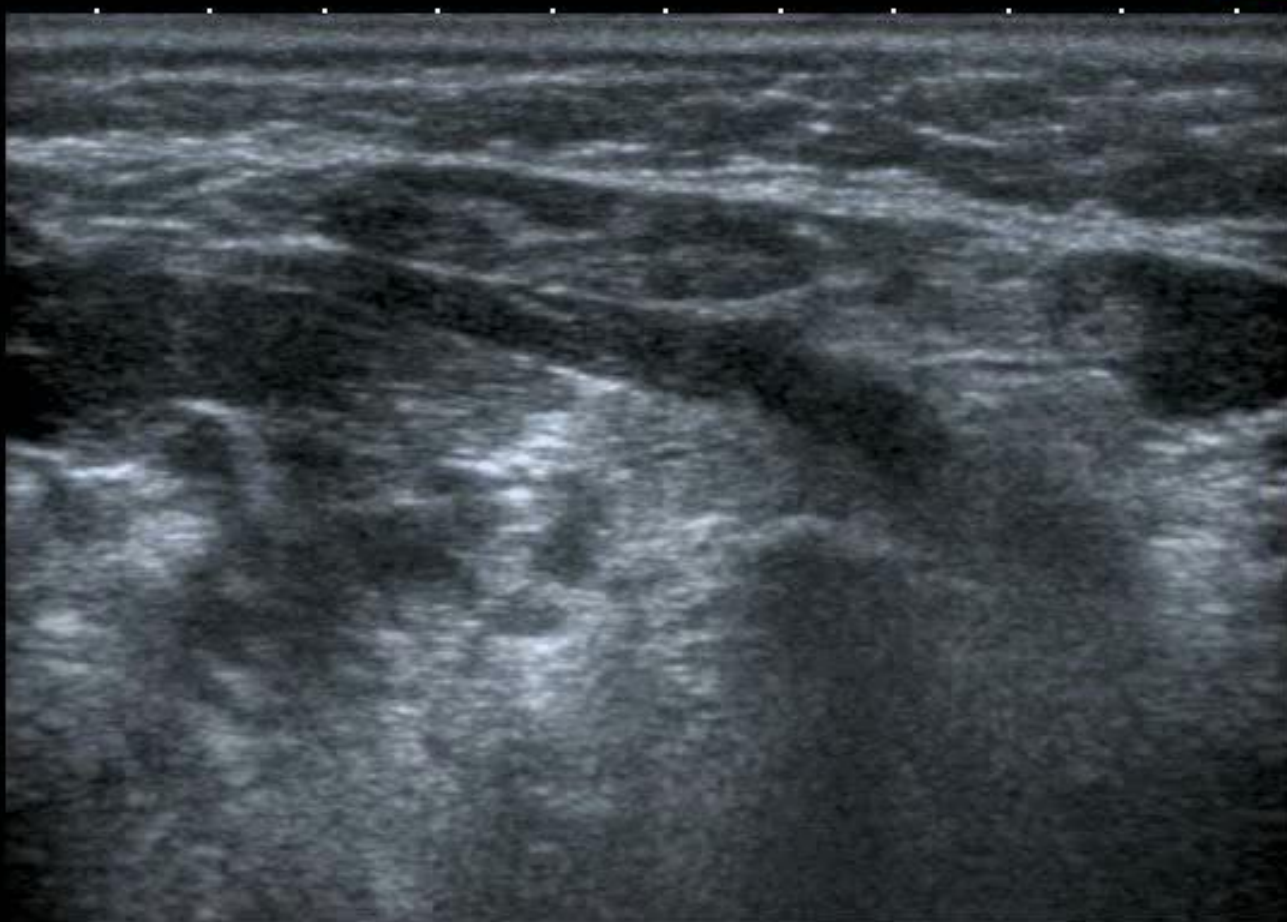MI: 1.6  
2DG  
79  
DR  
65

APure

T  
0  
1  
2  
3  
4

12L5  
T9.0

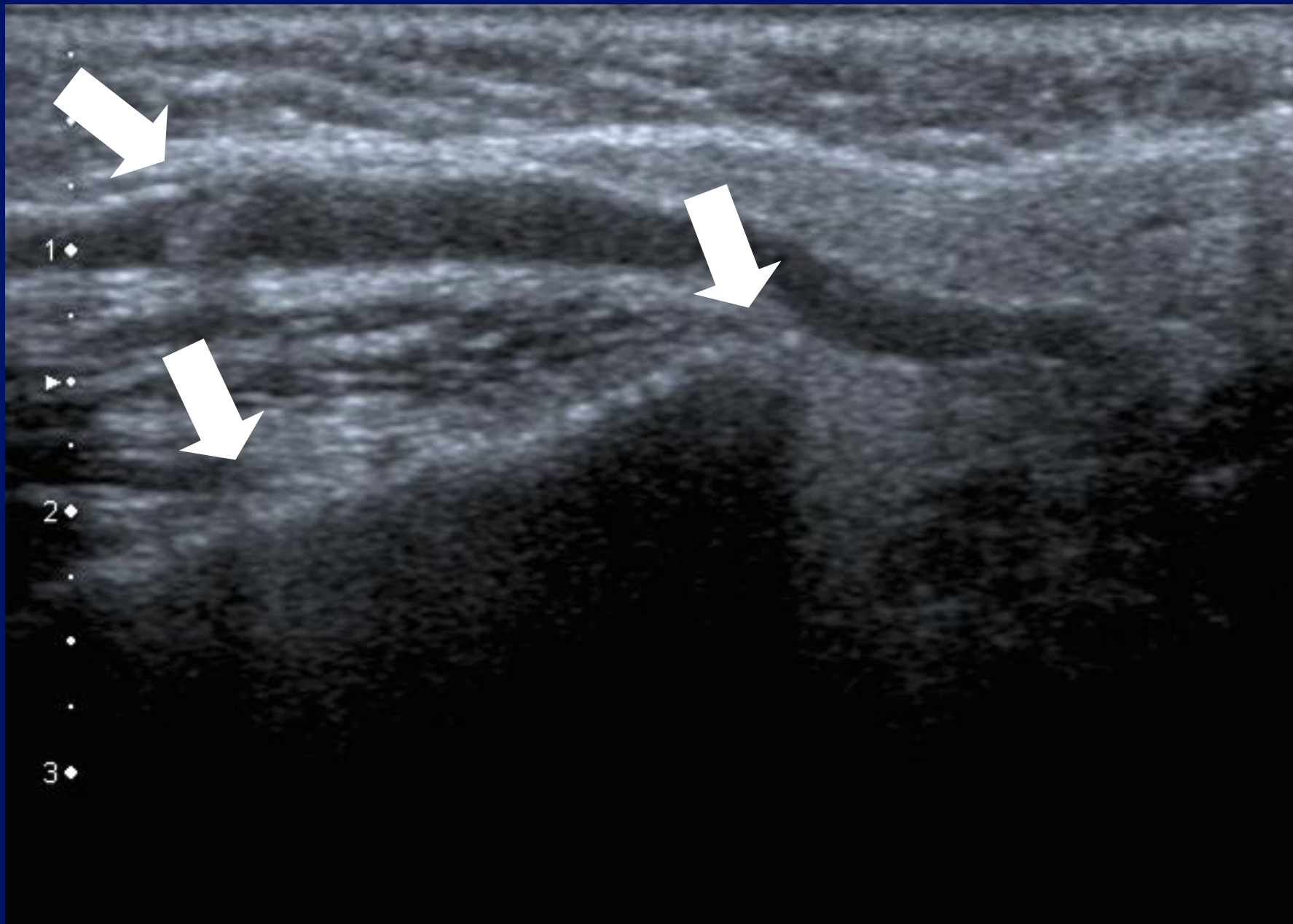
16 fps

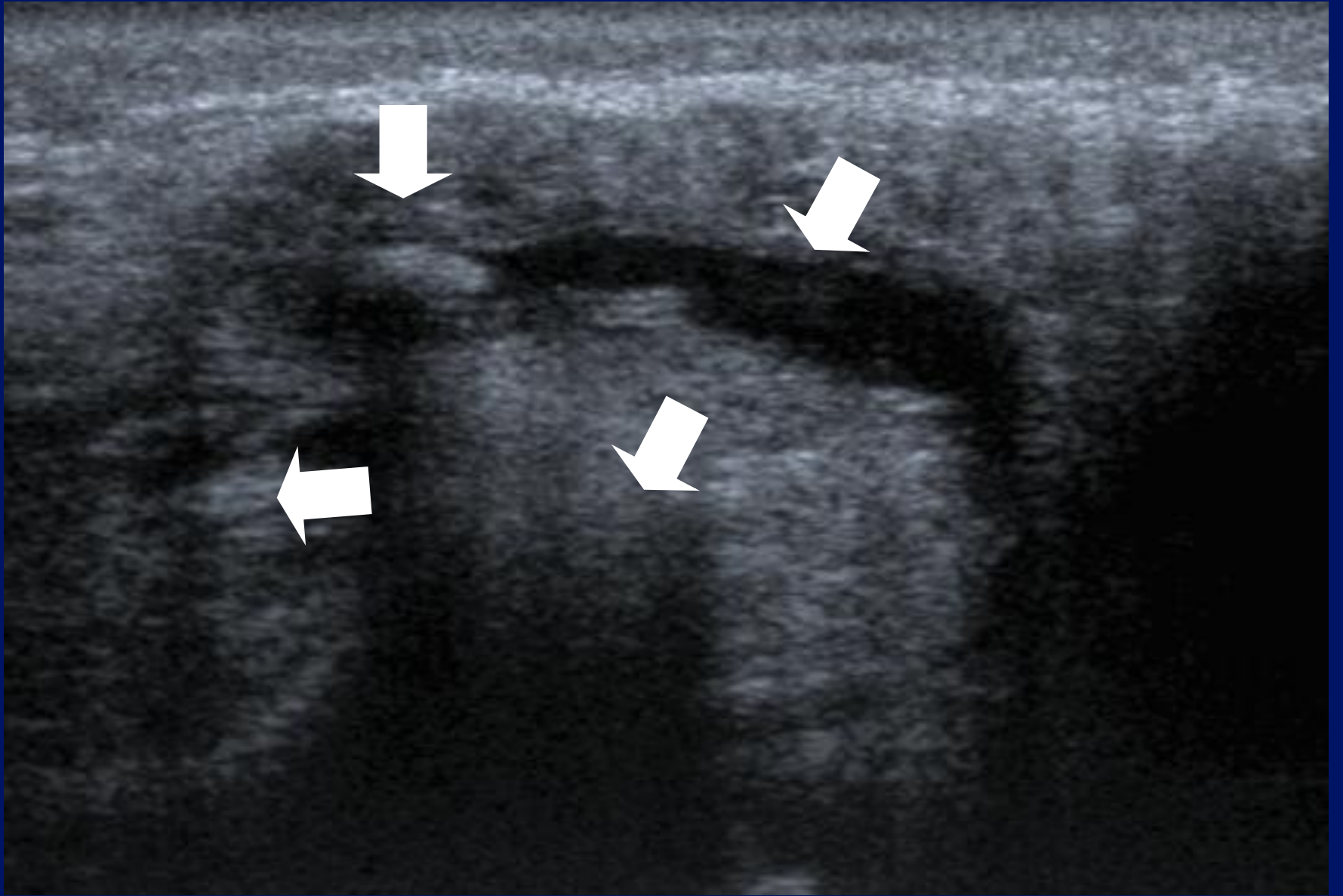


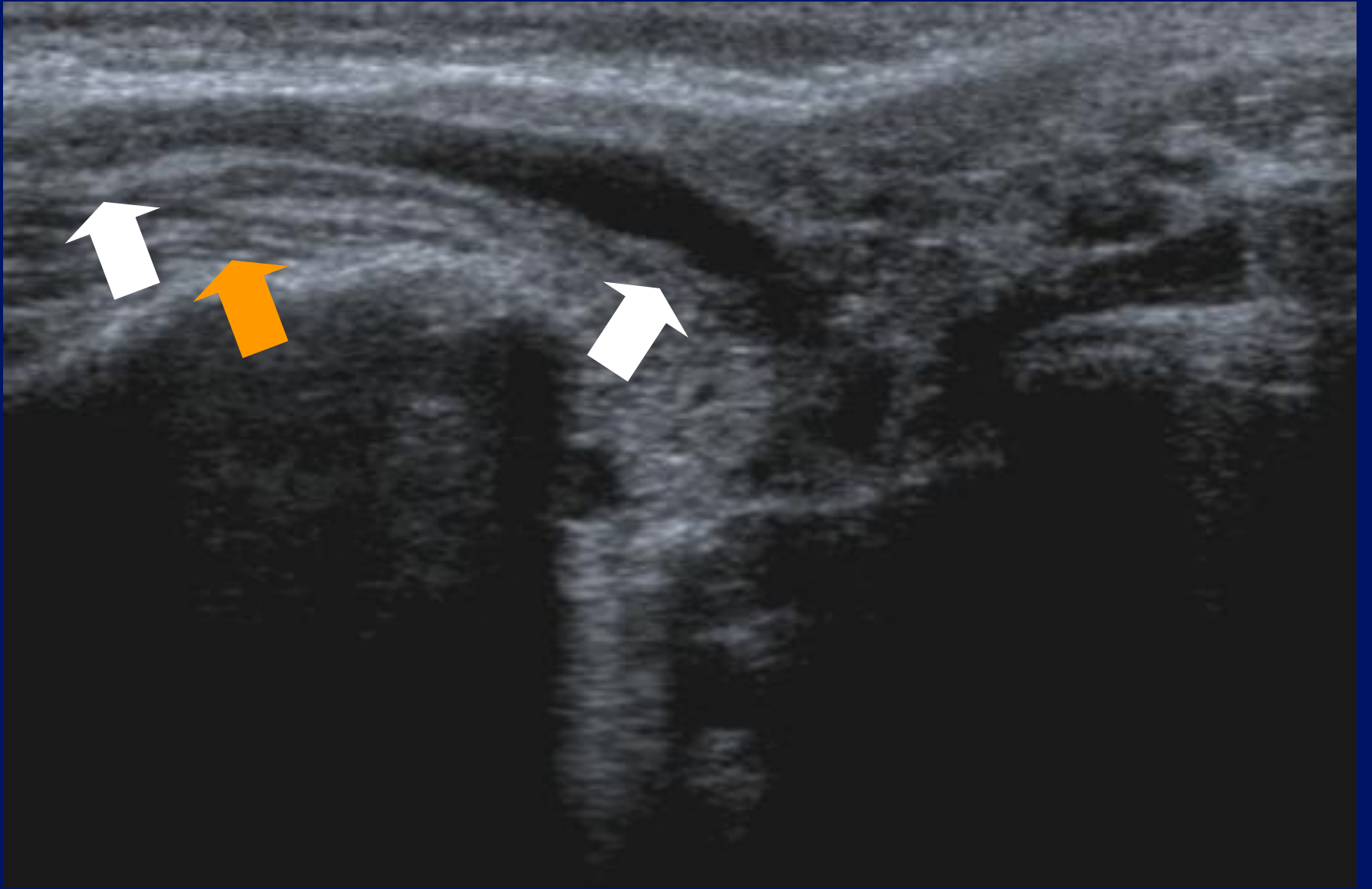
MI: 1.6  
2DG  
79  
DR  
65



Parotid.



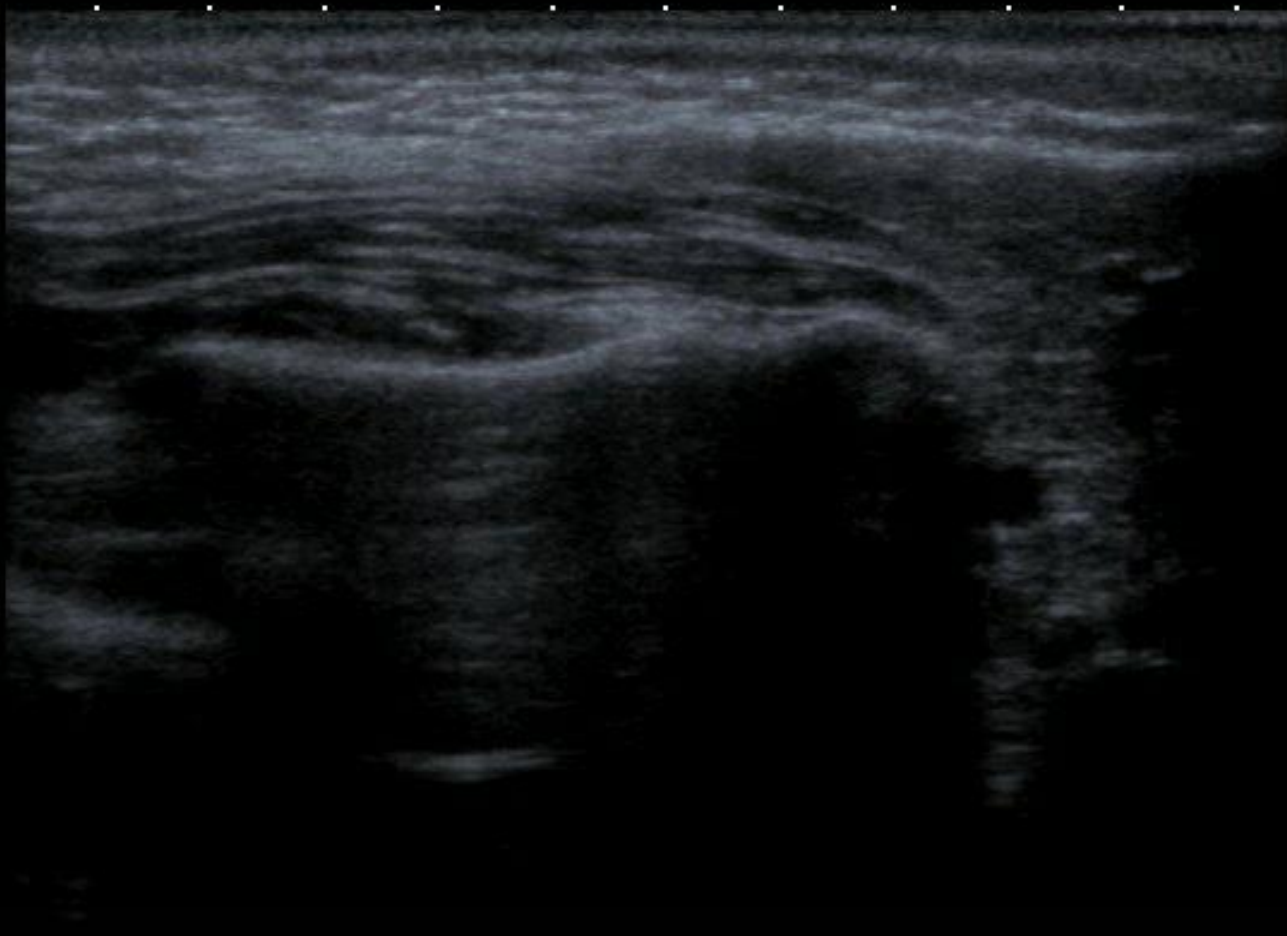




T  
0  
1  
2  
3  
4

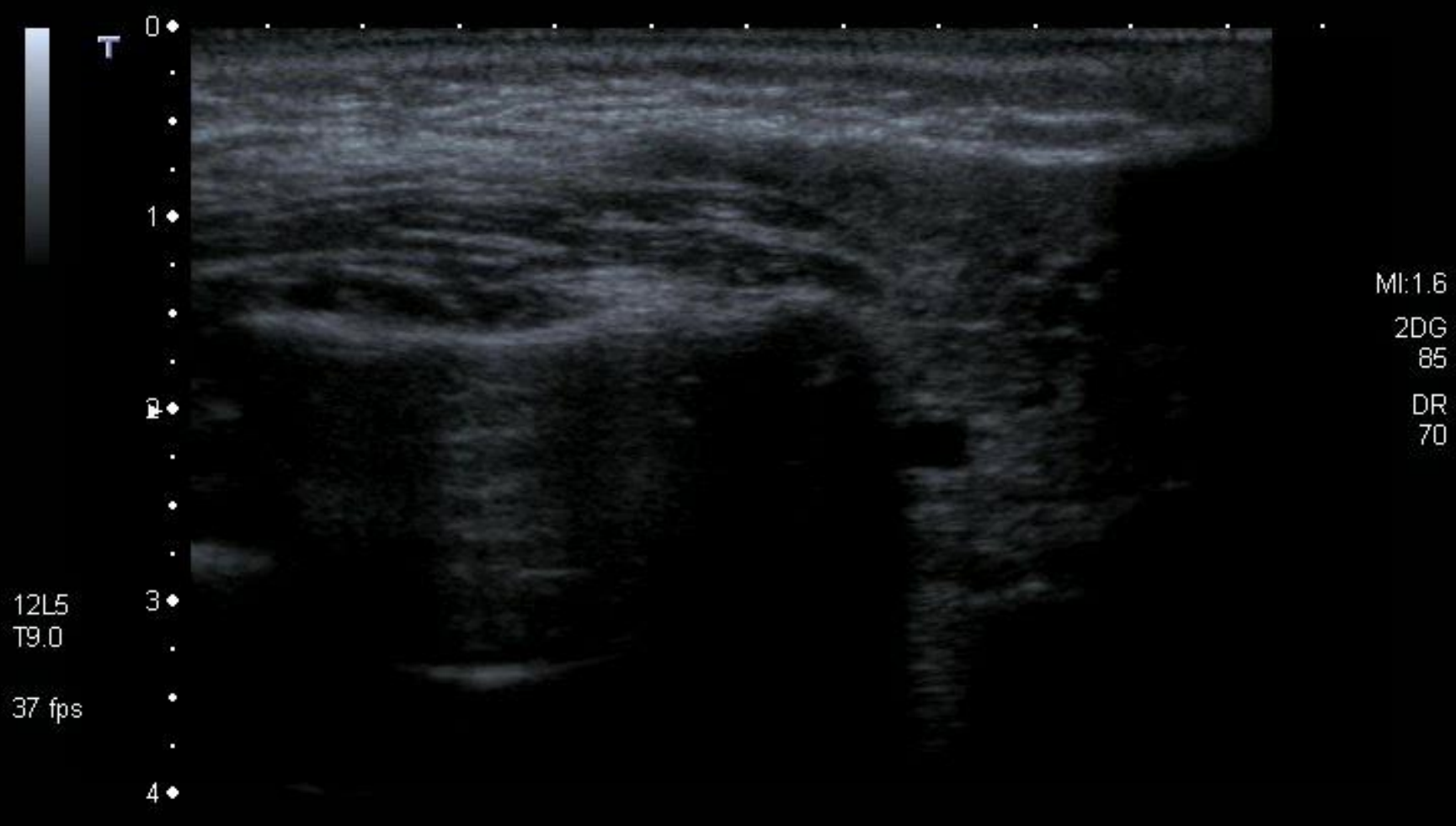
12L5  
T9.0

37 fps



MI: 1.6  
2DG  
85  
DR  
70

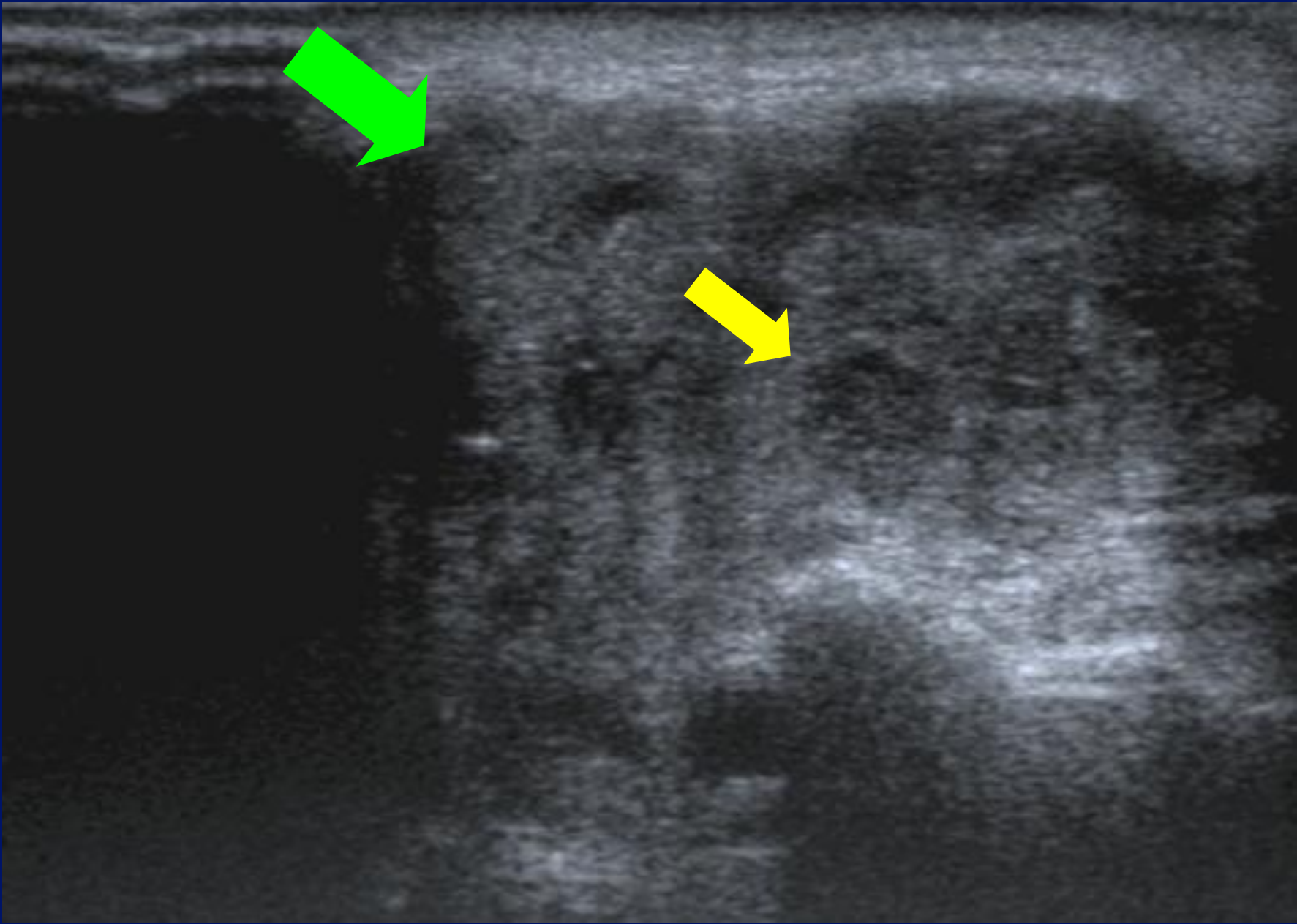


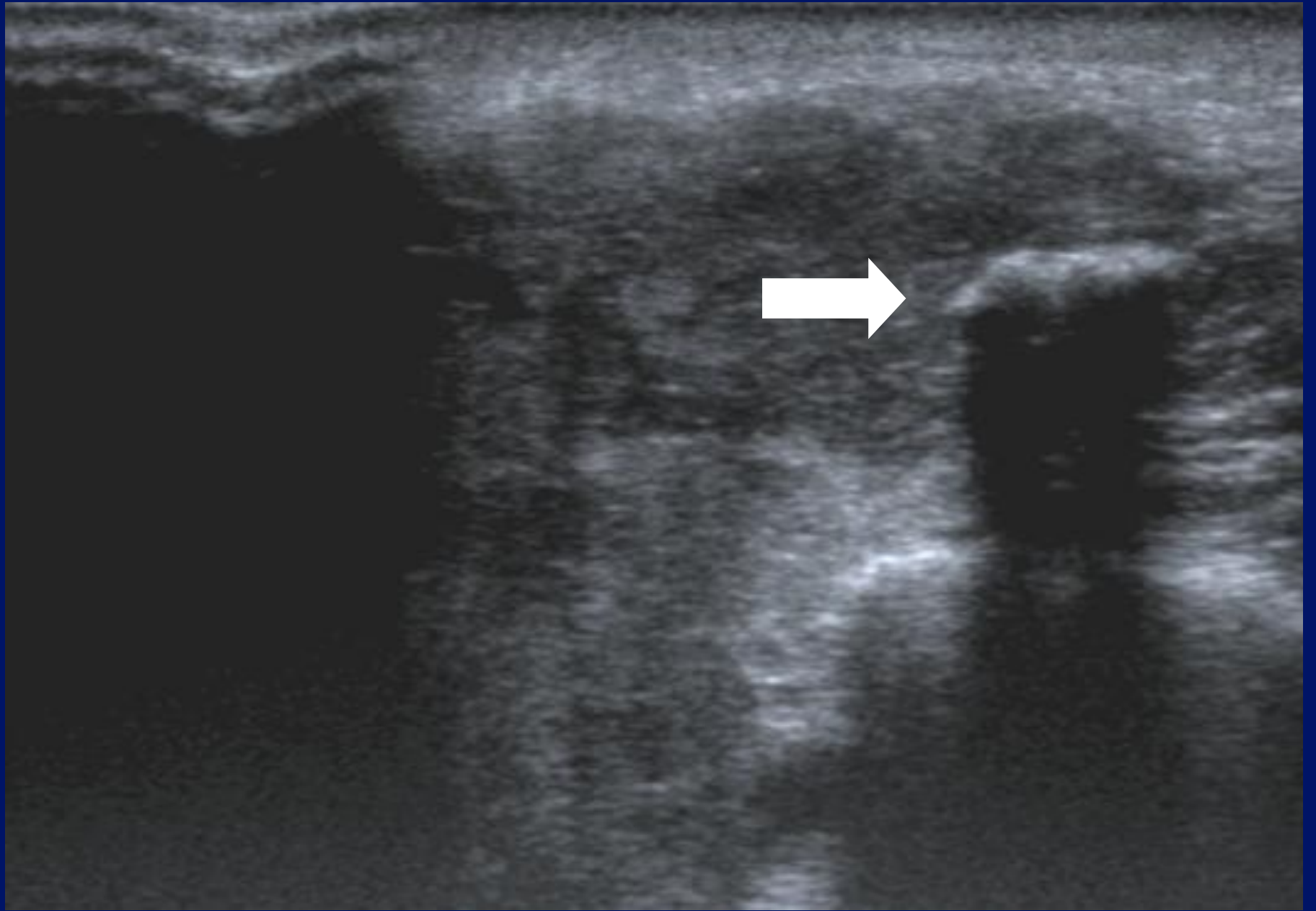


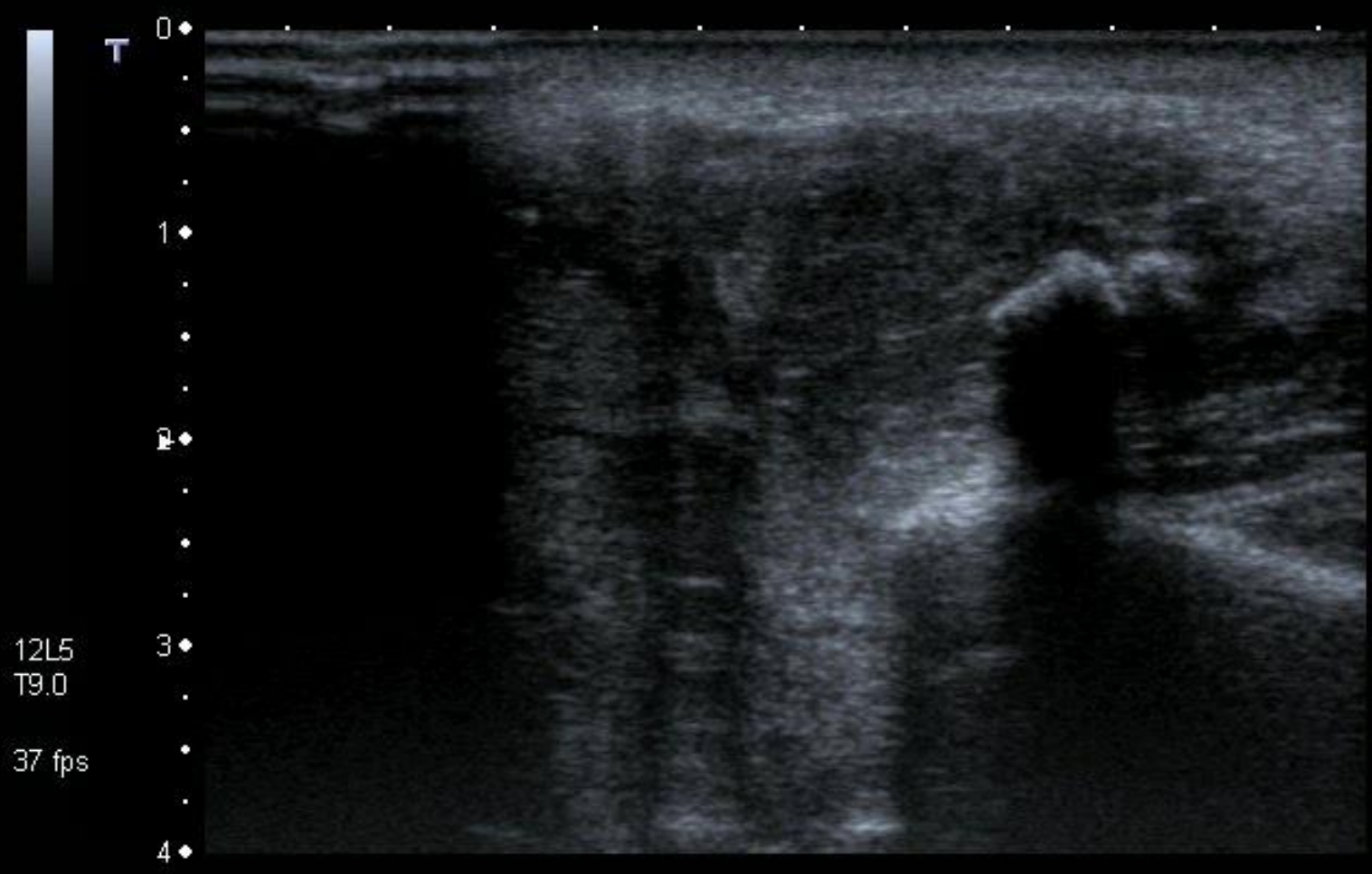
12L5  
T9.0  
37 fps

MI: 1.6  
2DG  
85  
DR  
70










MI: 1.6  
2DG  
85  
DR  
70

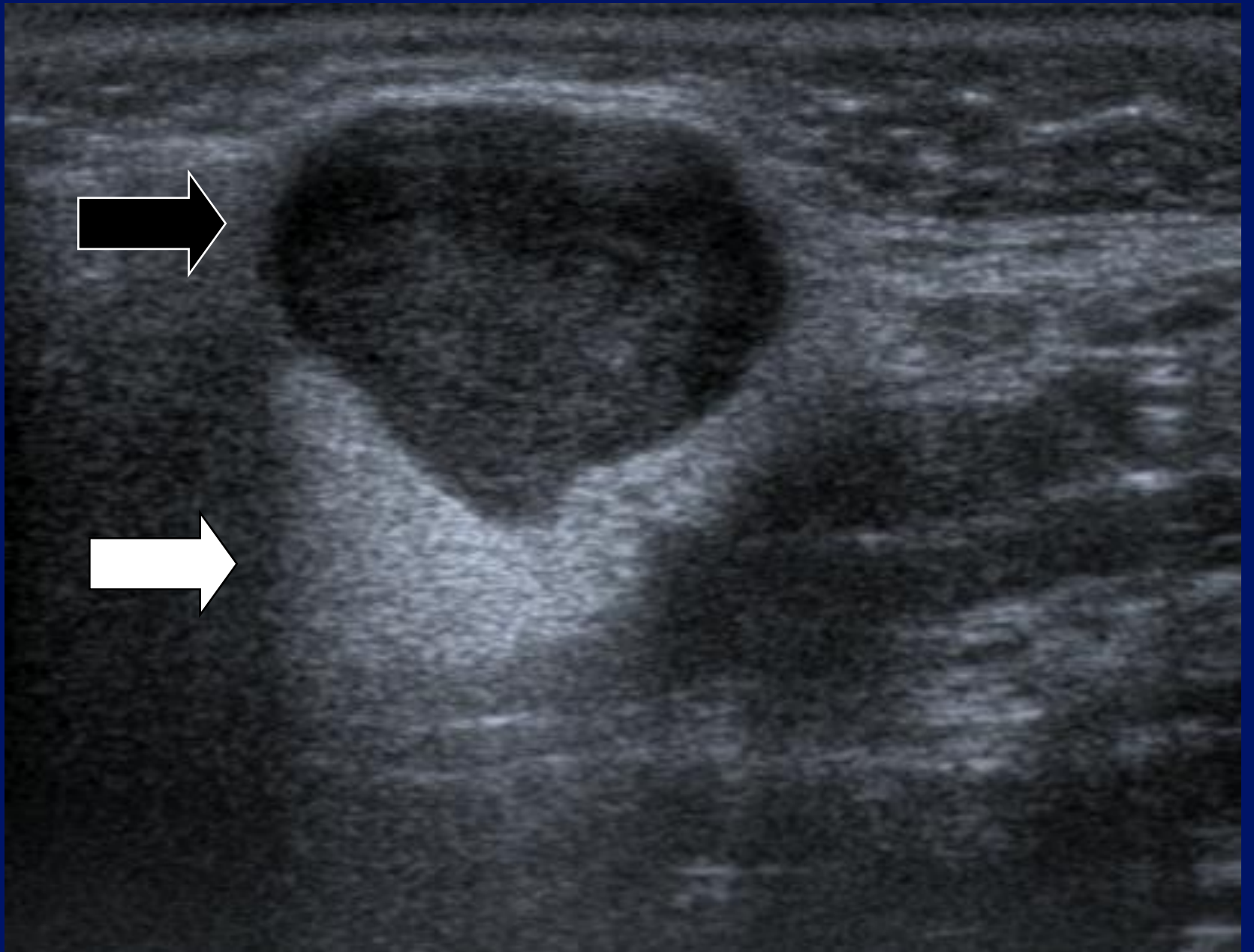
12L5  
T9.0  
37 fps

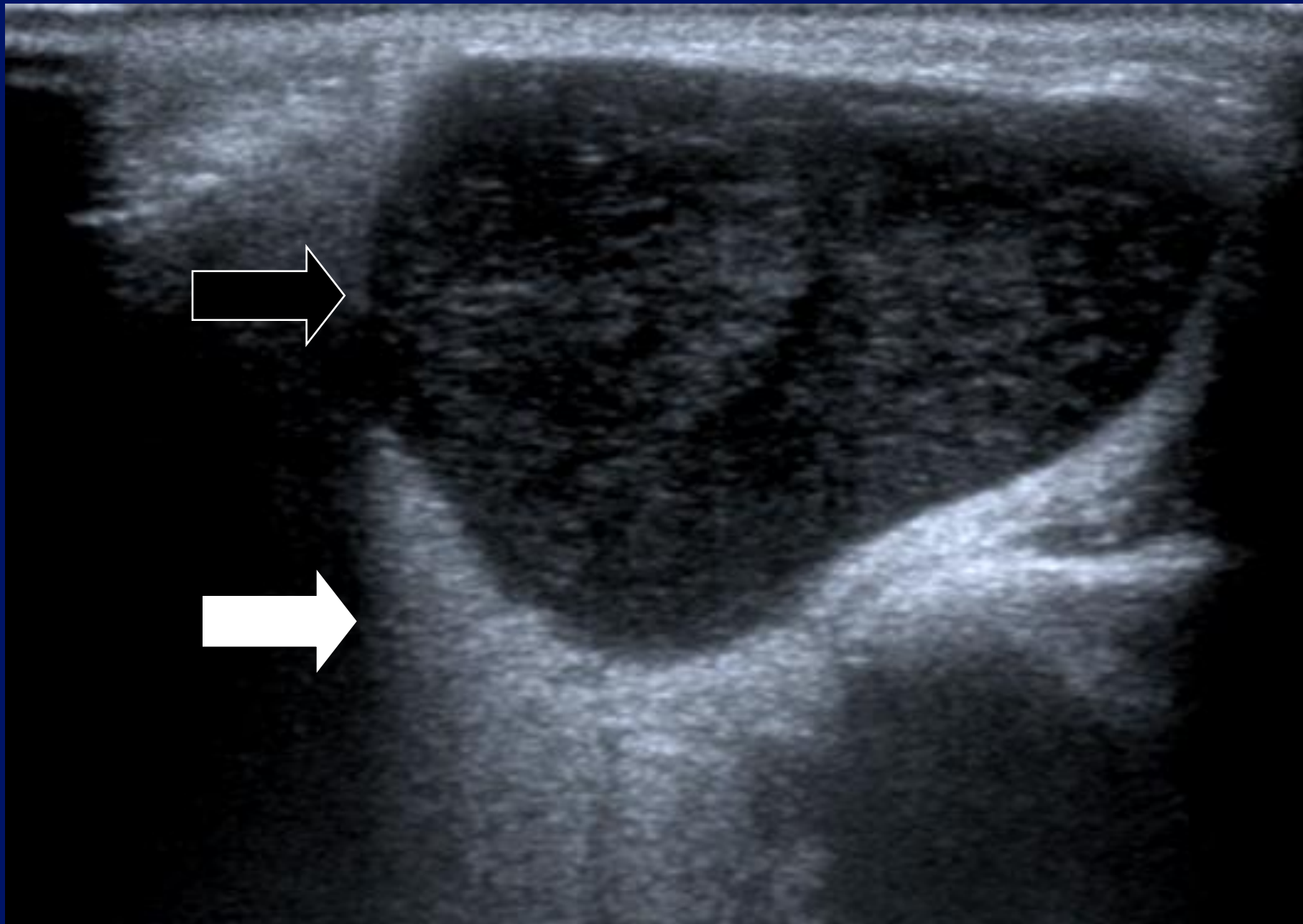


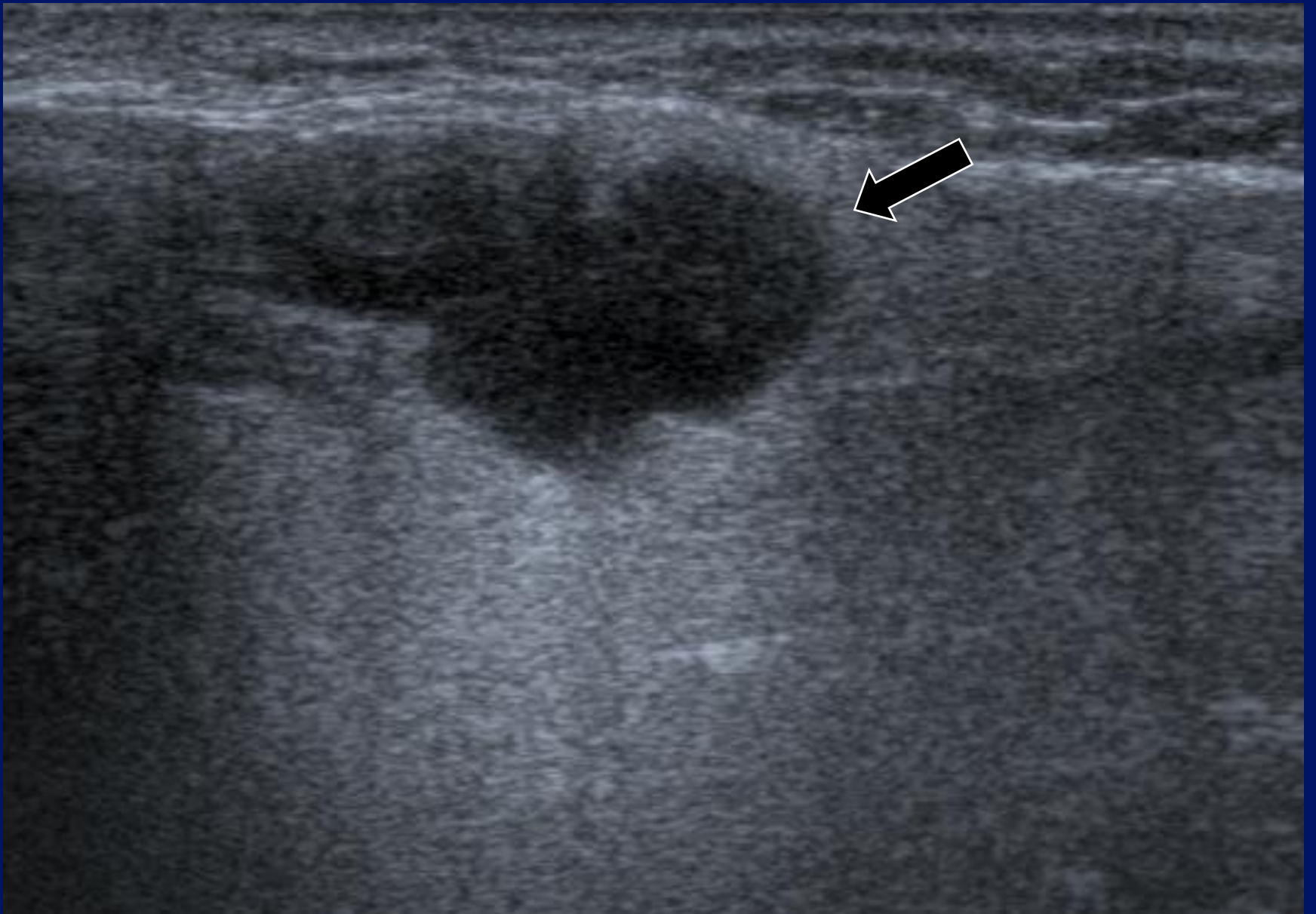# Parotid tumours.

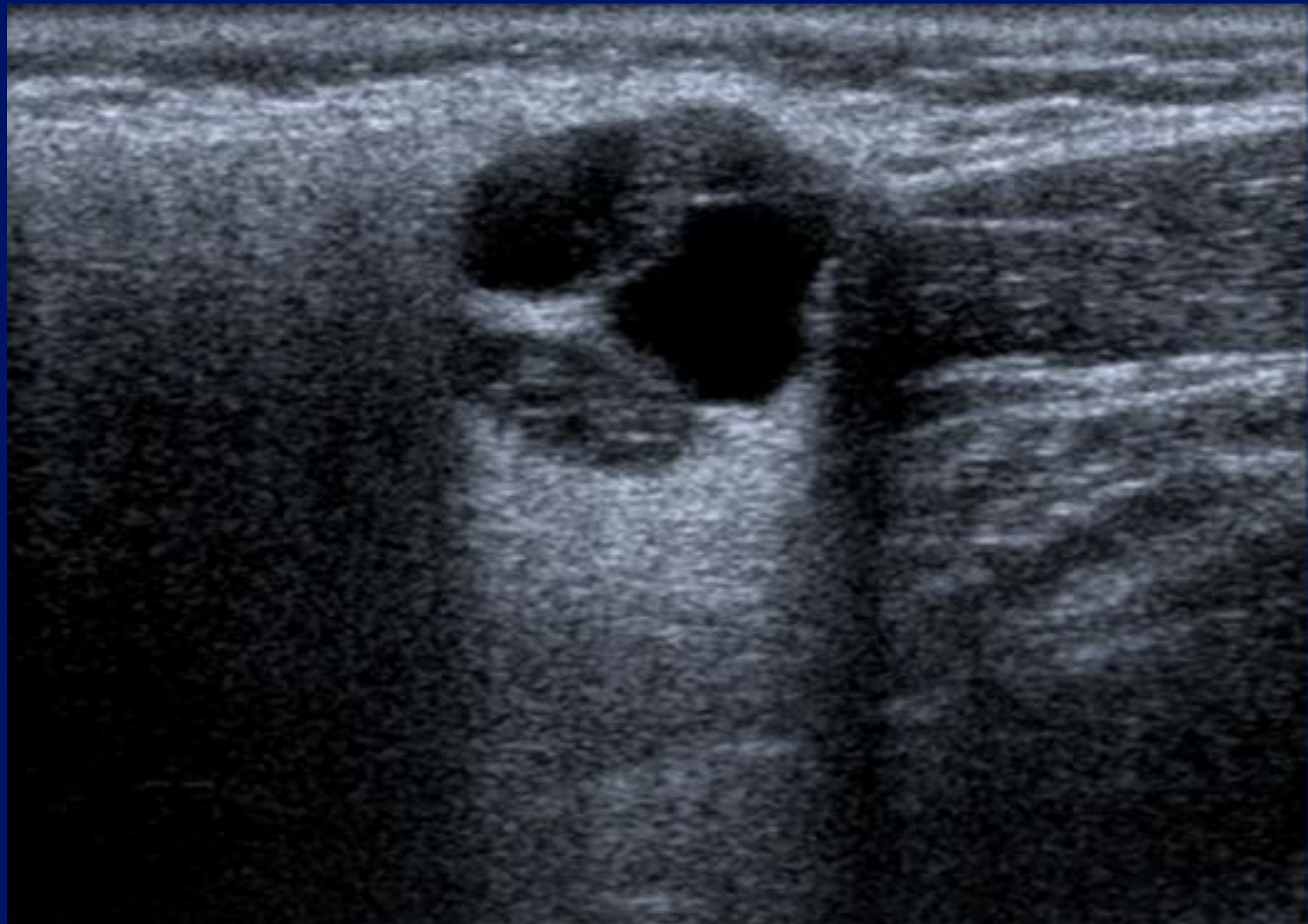
- 80% parotid in origin
- (20% extra-parotid)
- 80% superficial
- 80% benign
- 80% :pleomorphic adenoma

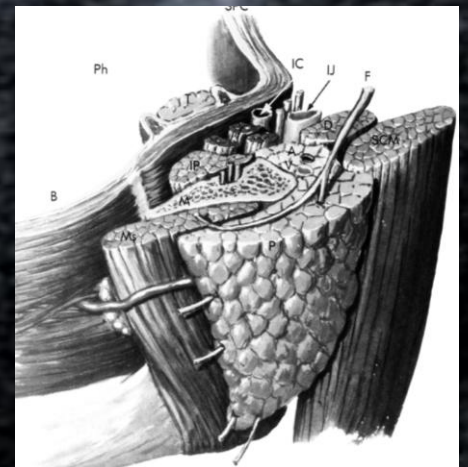
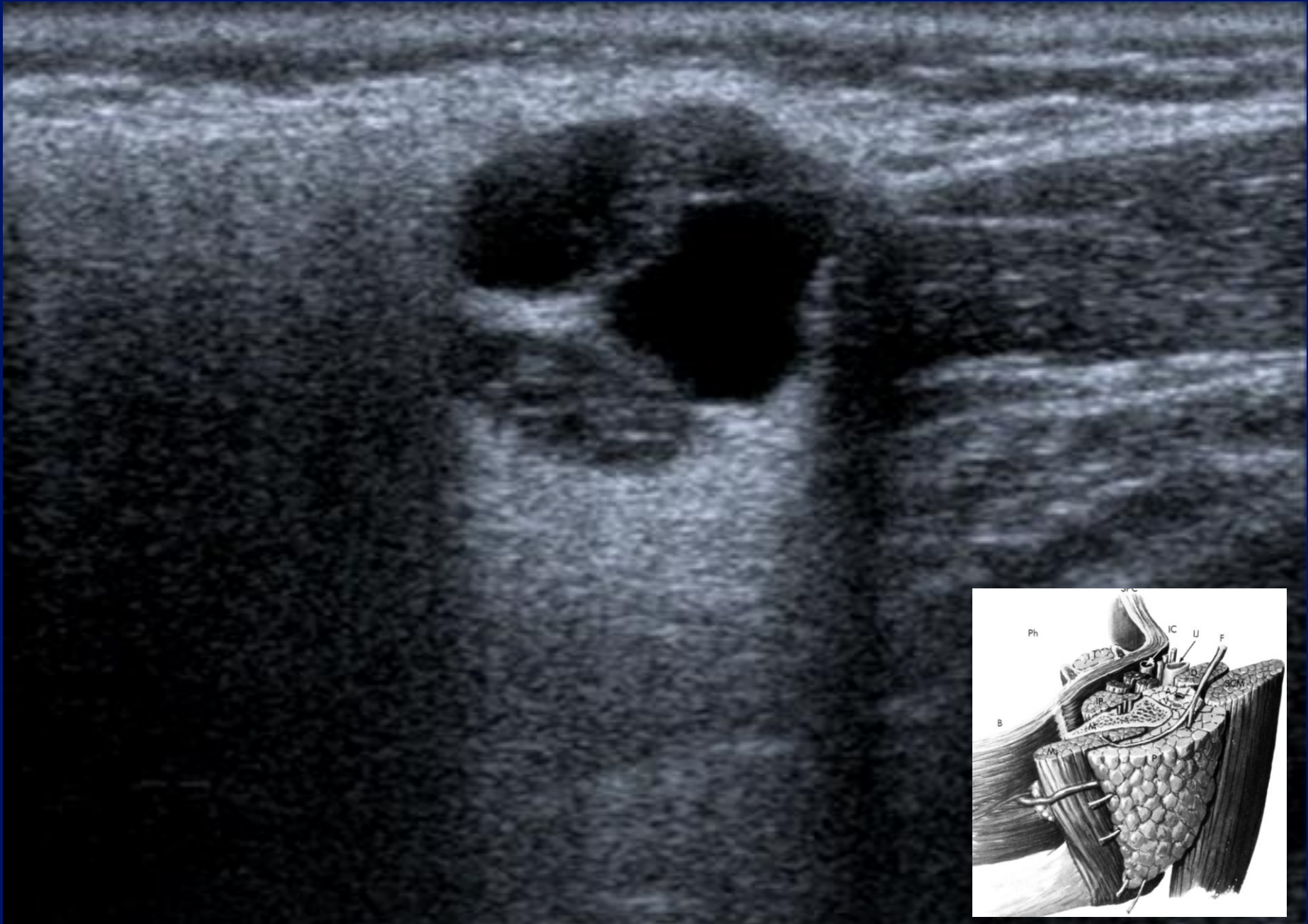


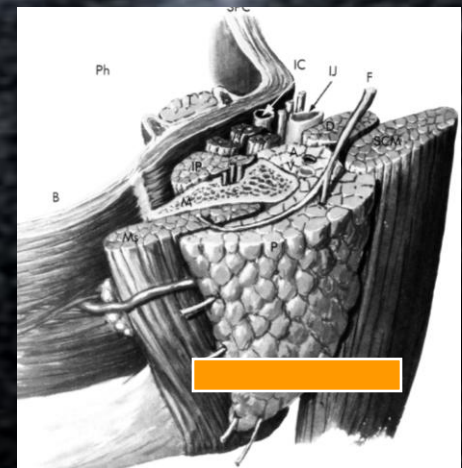
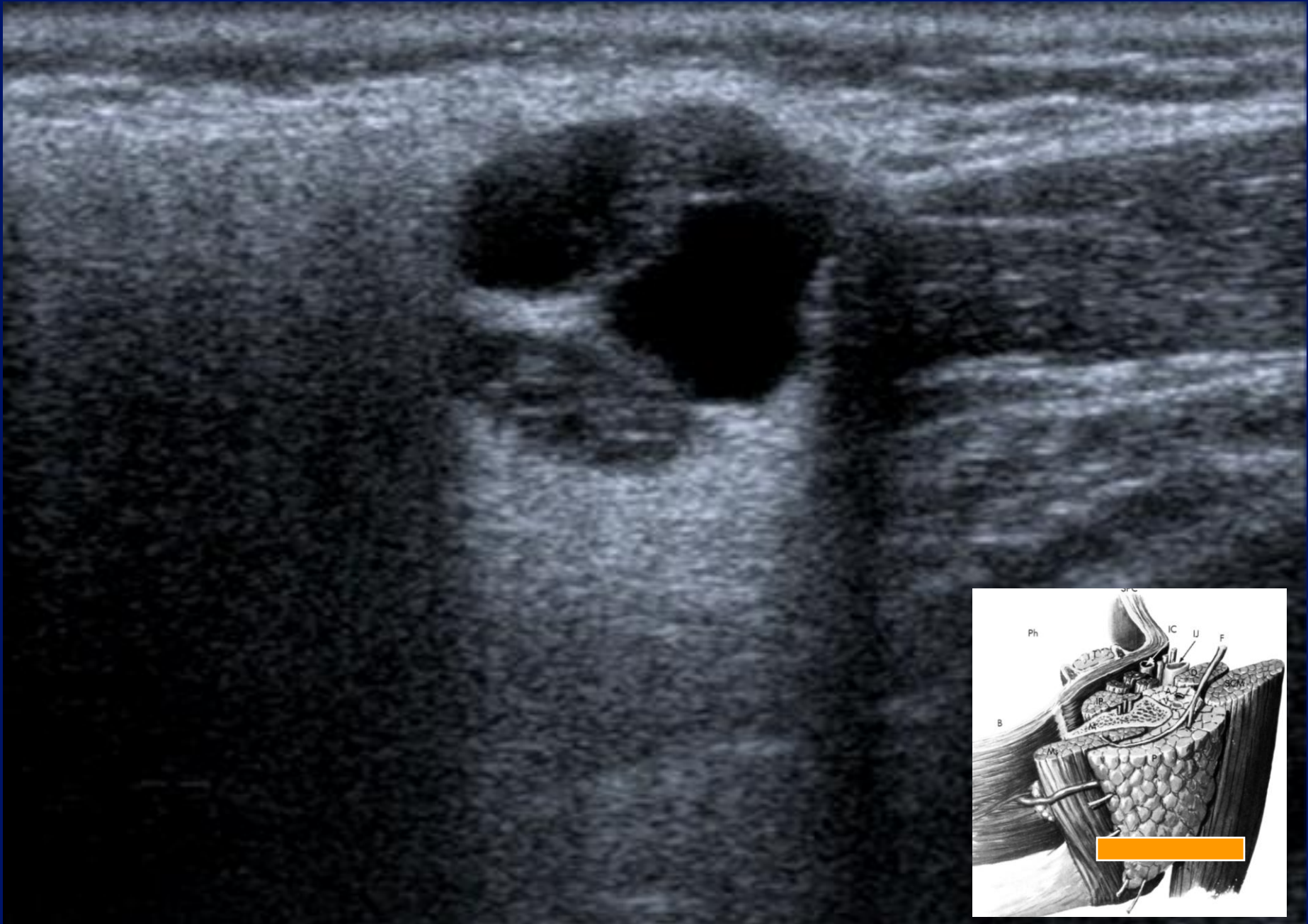


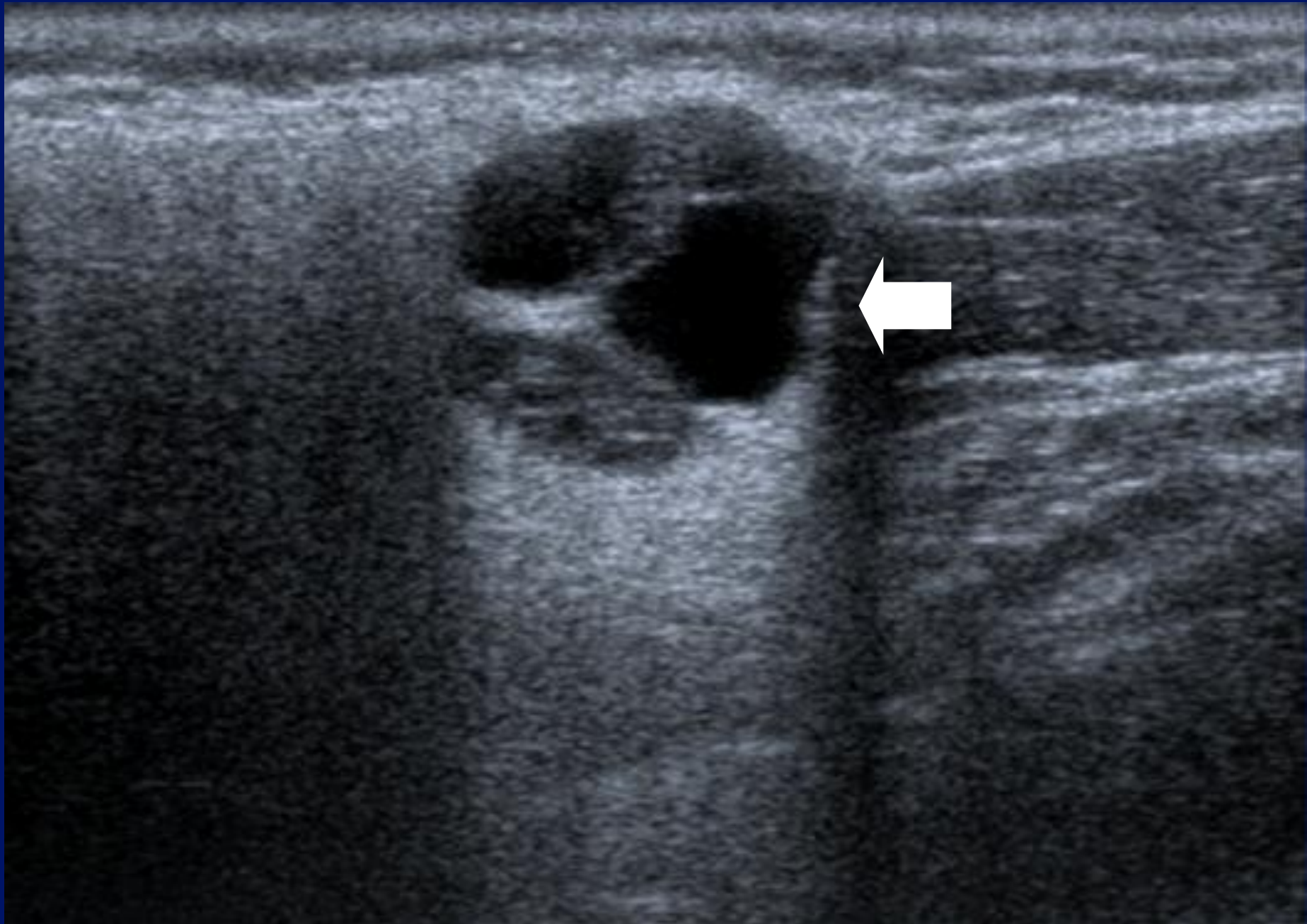


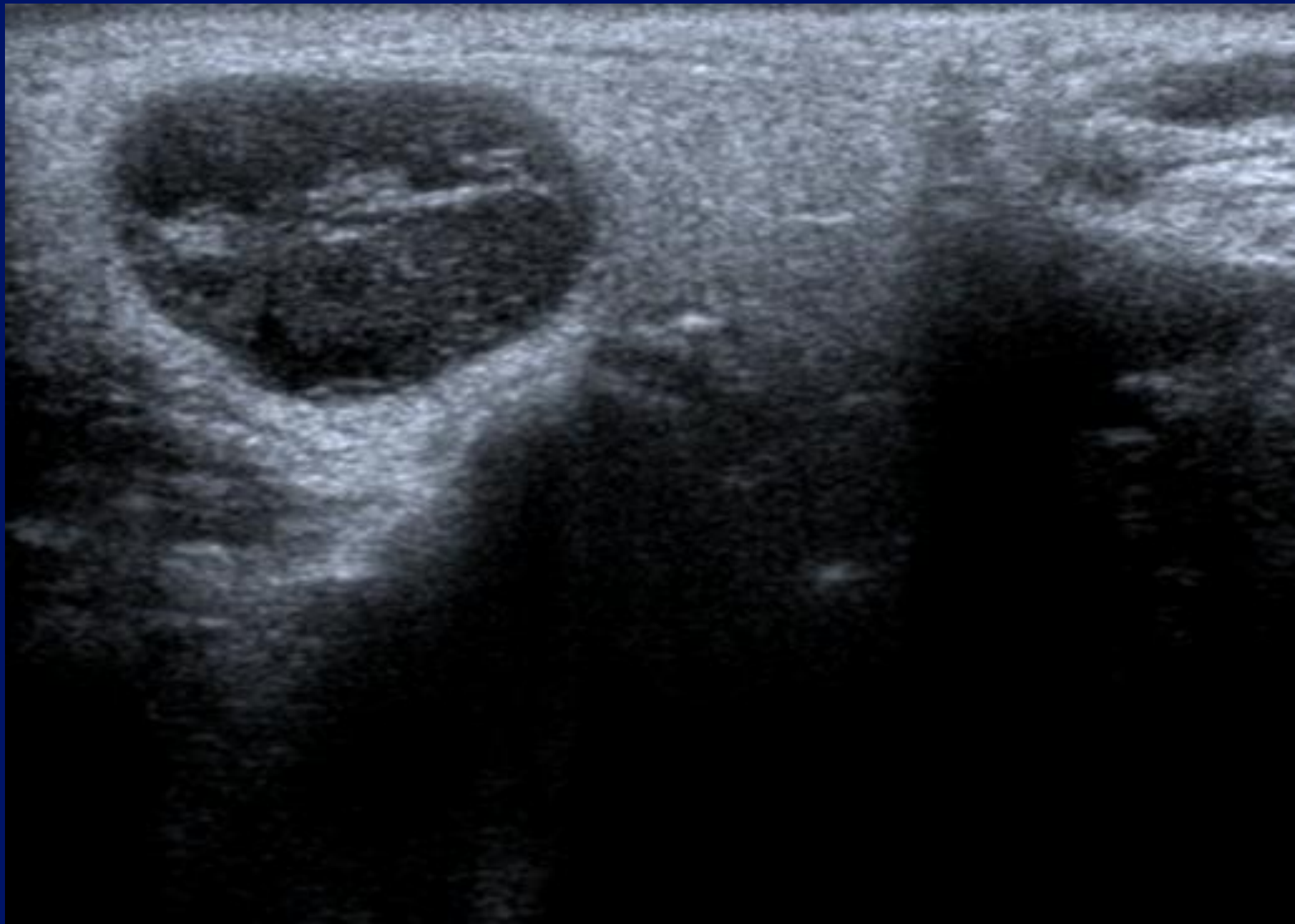


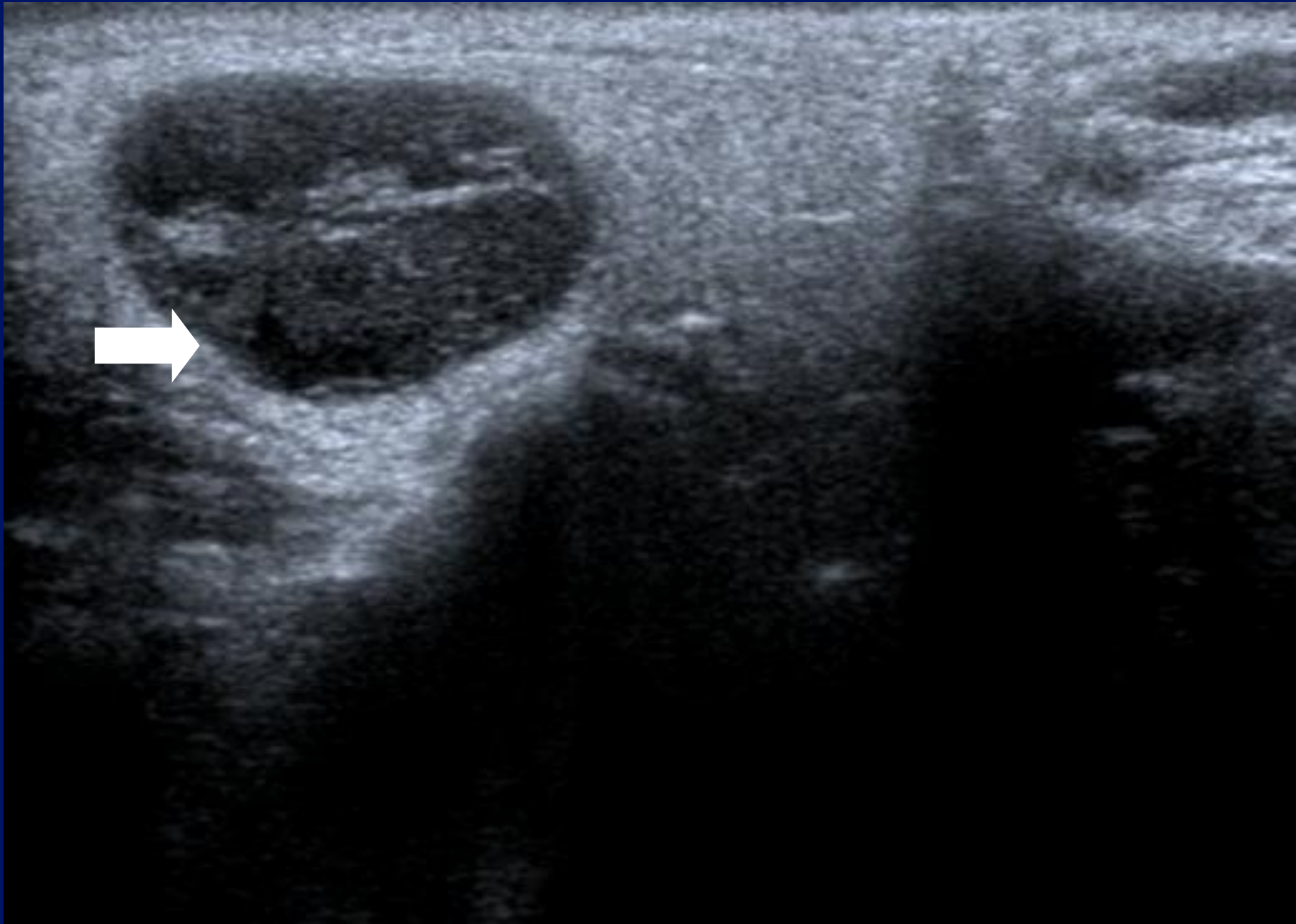




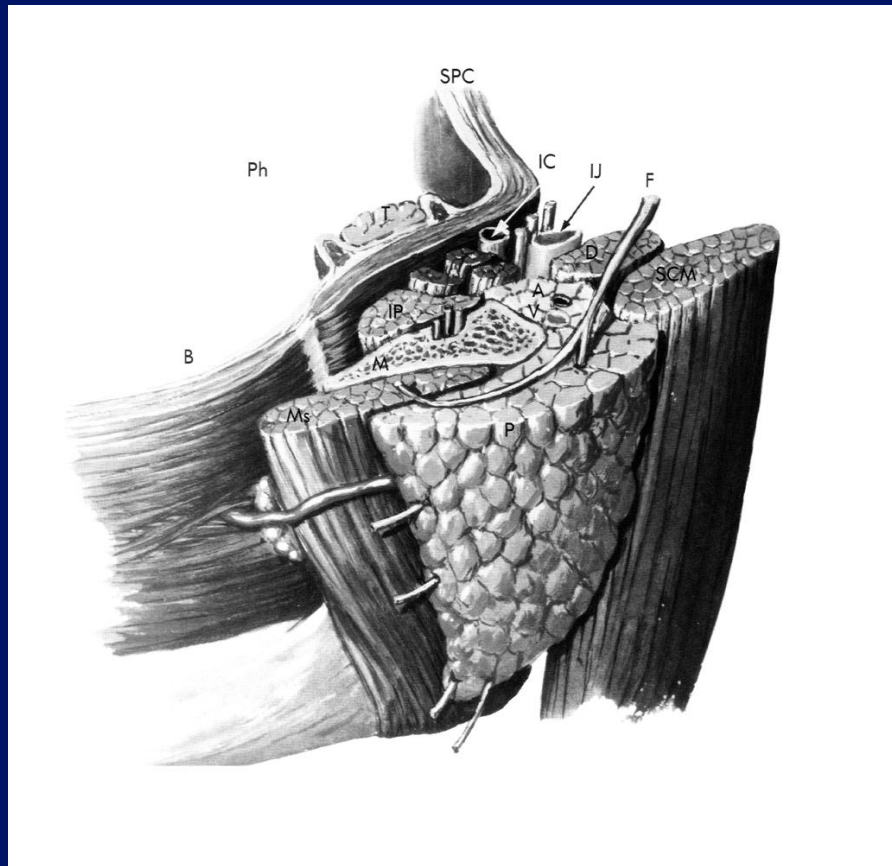


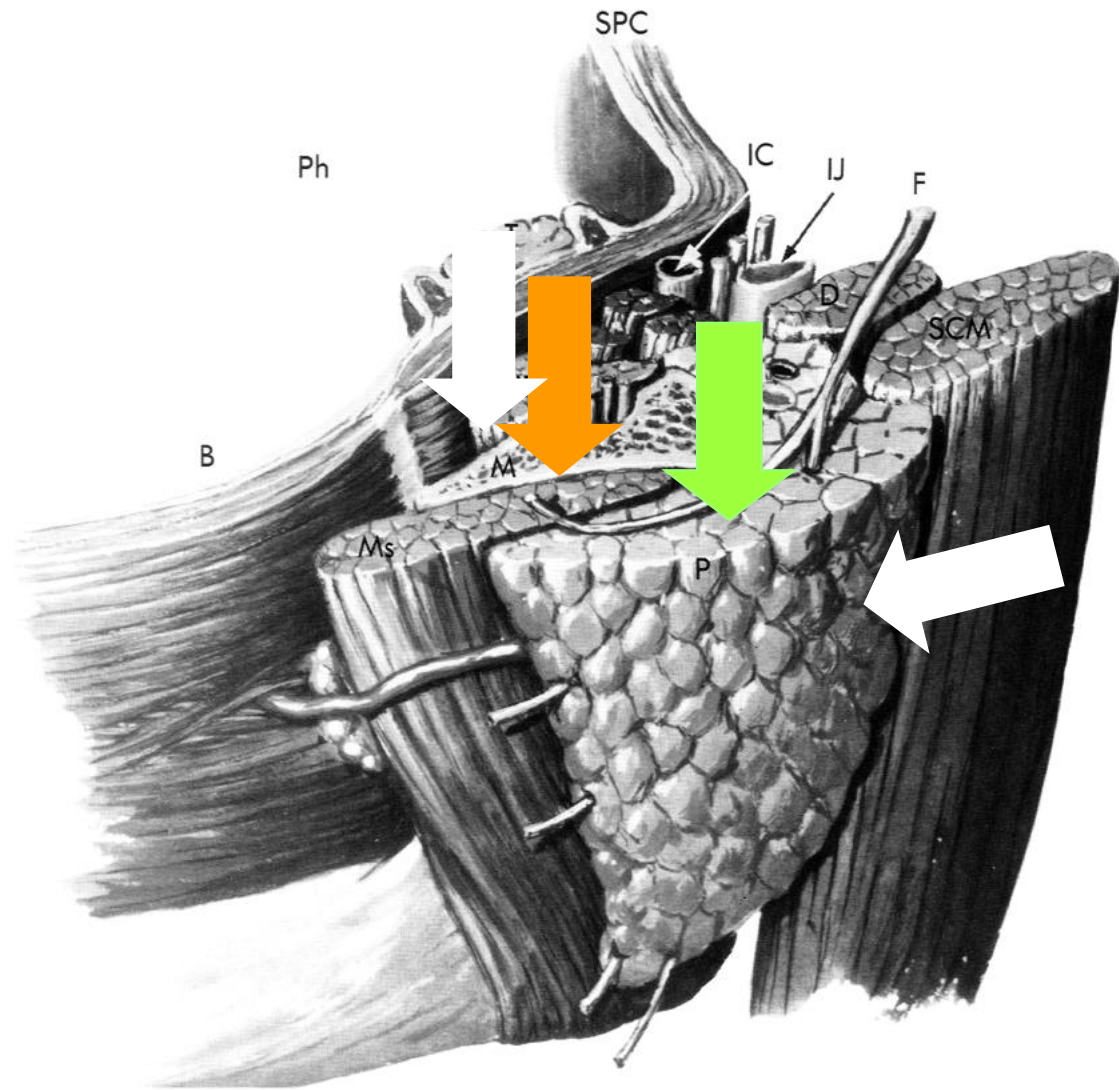


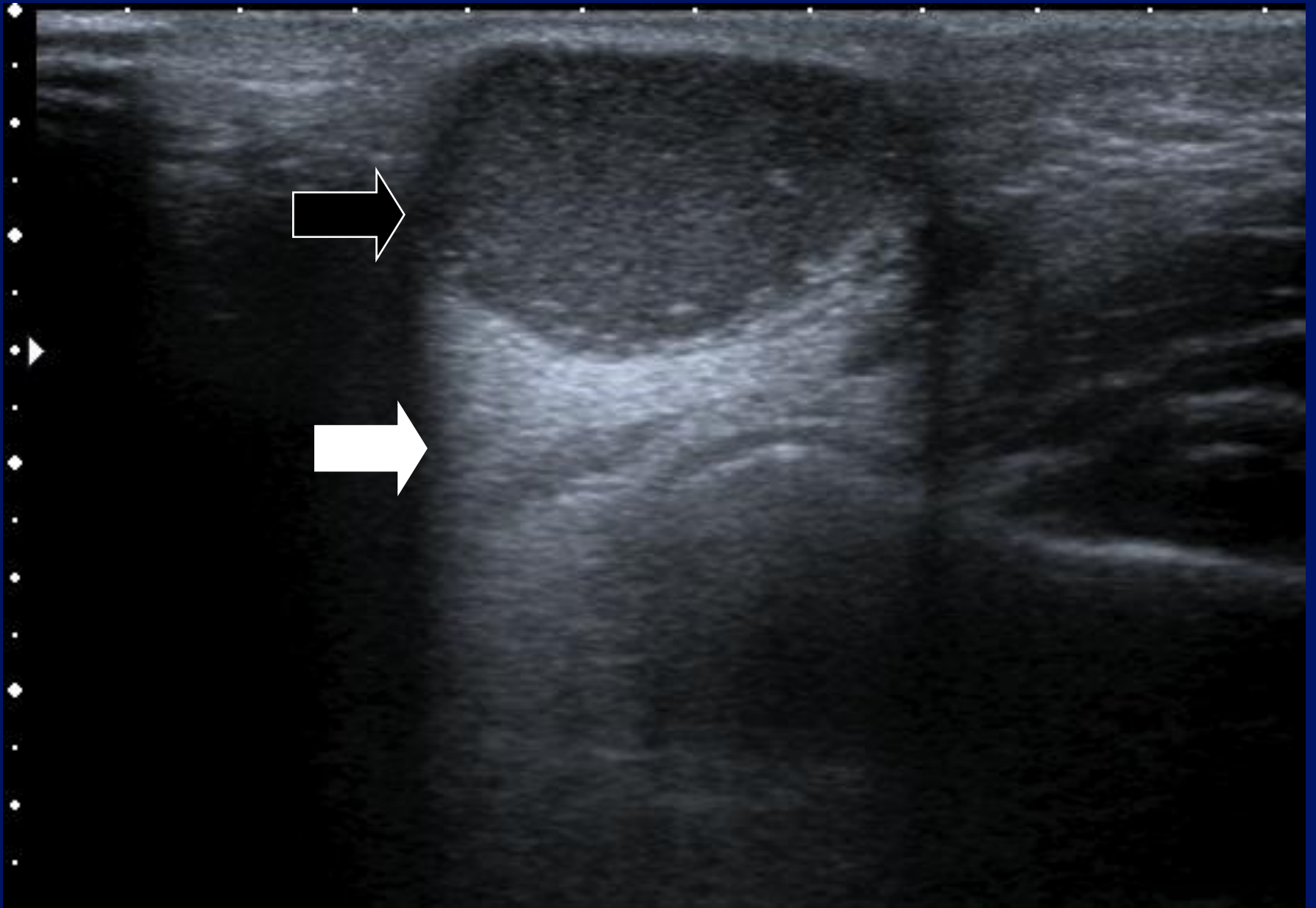


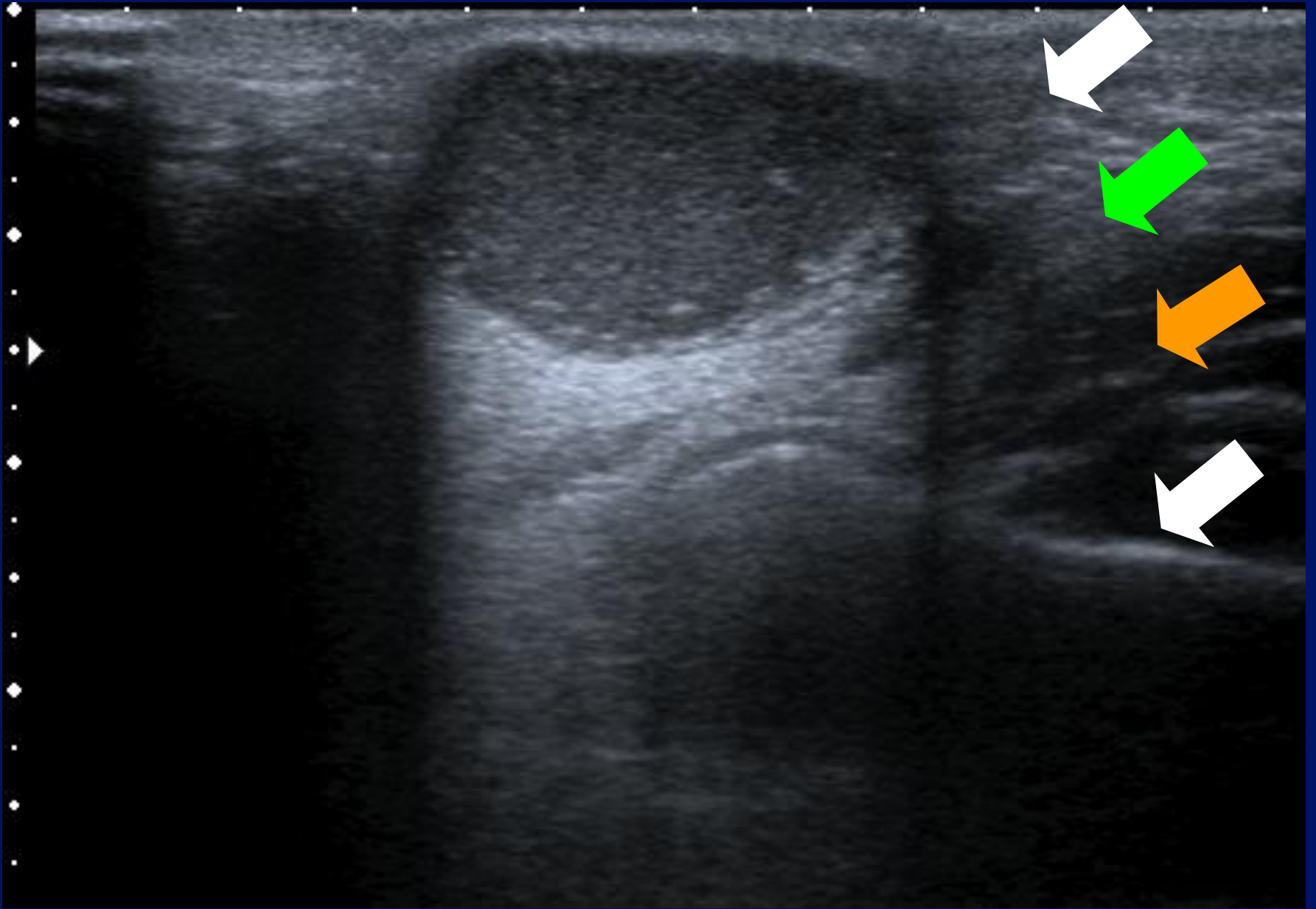


# Extra – parotid masses.



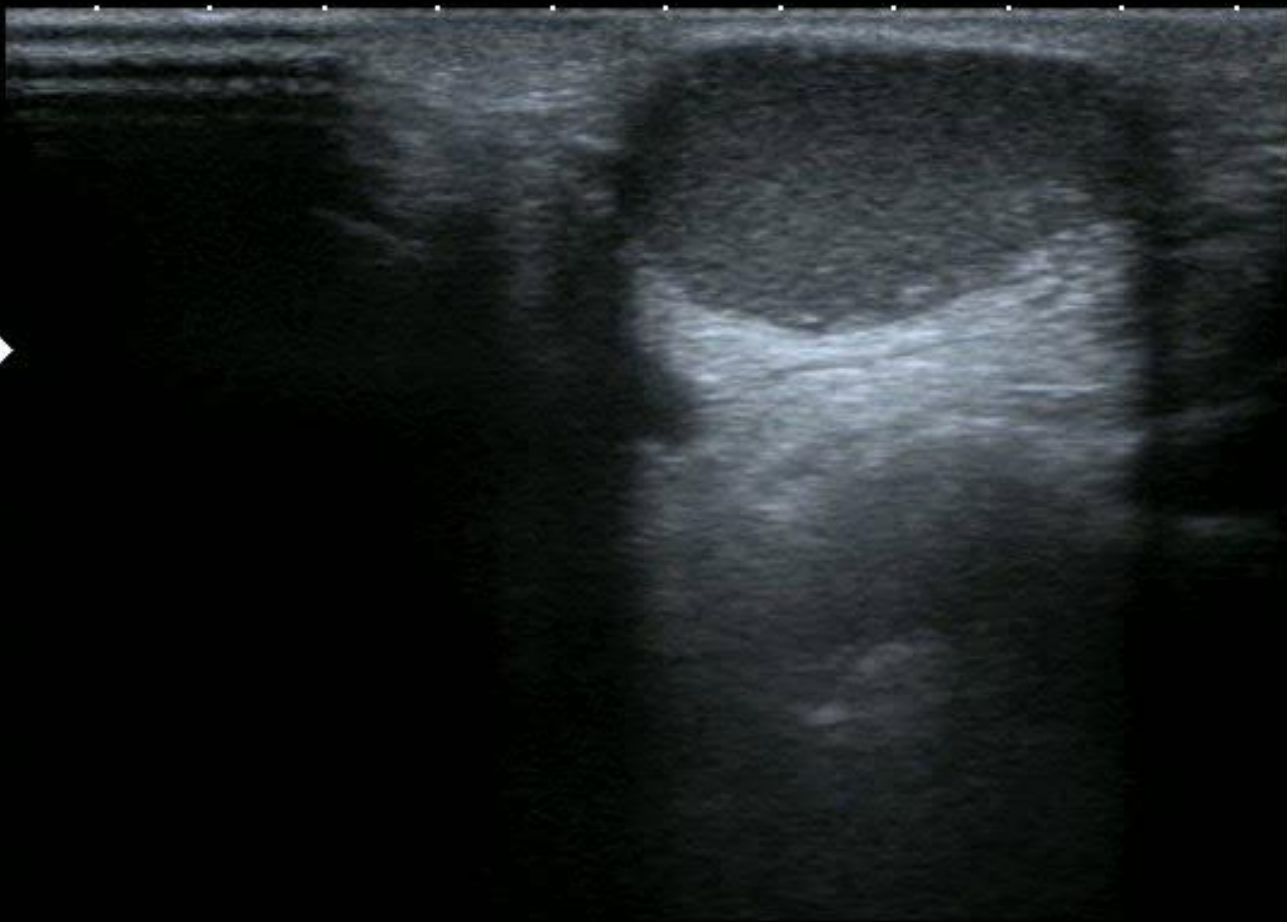







0 ◆  
.  
.  
1 ◆  
.  
.  
2 ◆  
.  
.  
3 ◆  
.  
.  
4 ◆



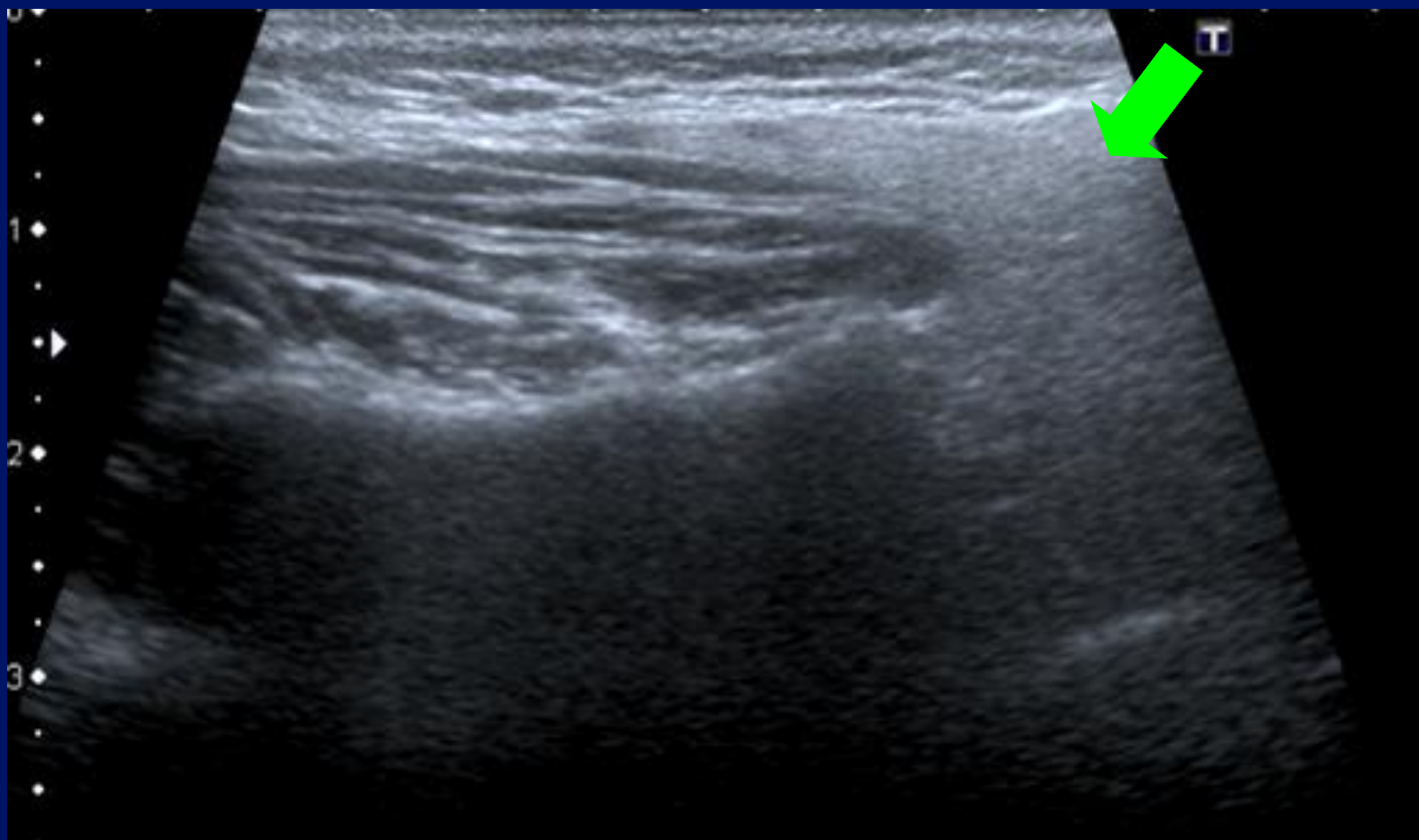
MI: 1.6  
2DG  
80  
DR  
65

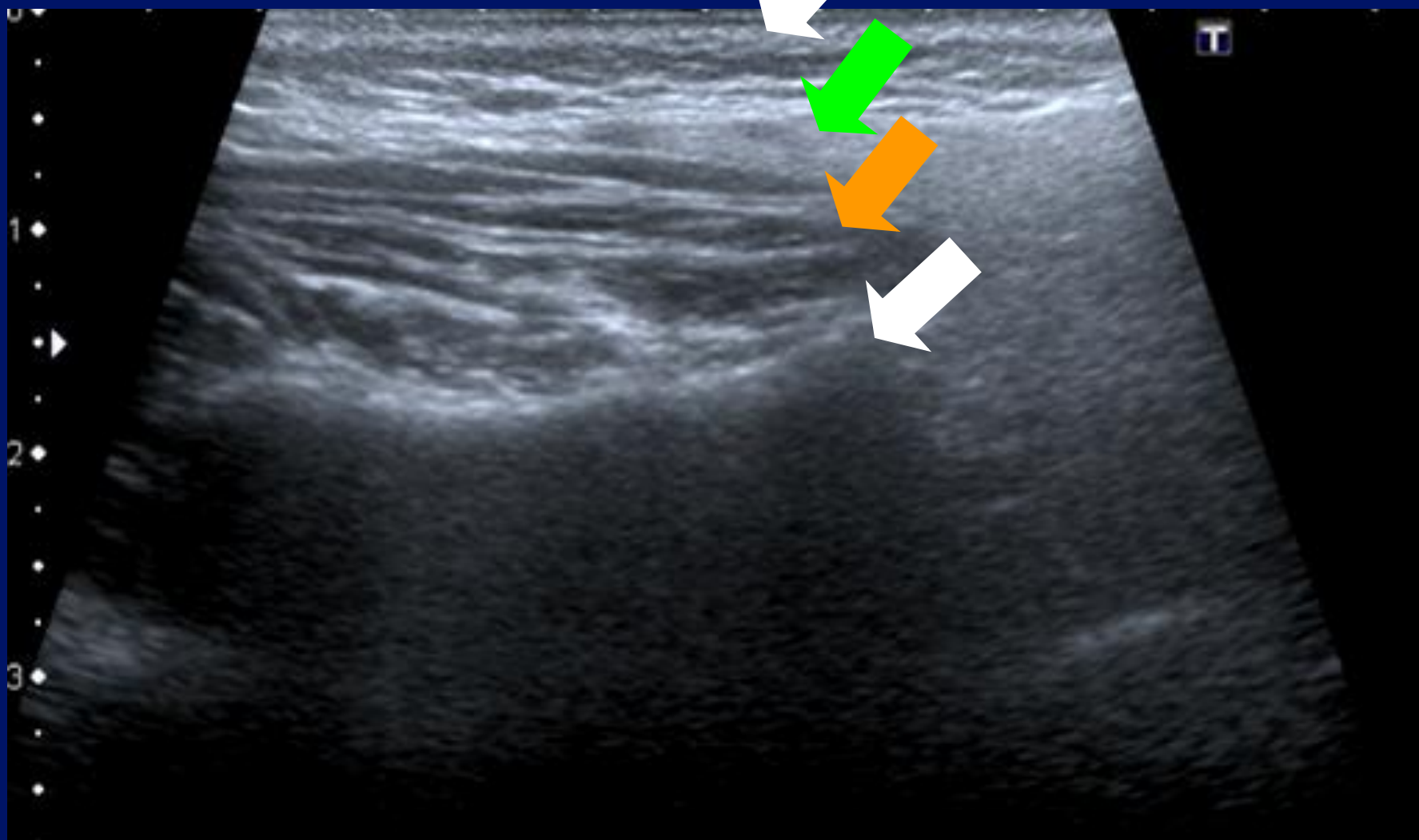
12L5  
diffT8.0

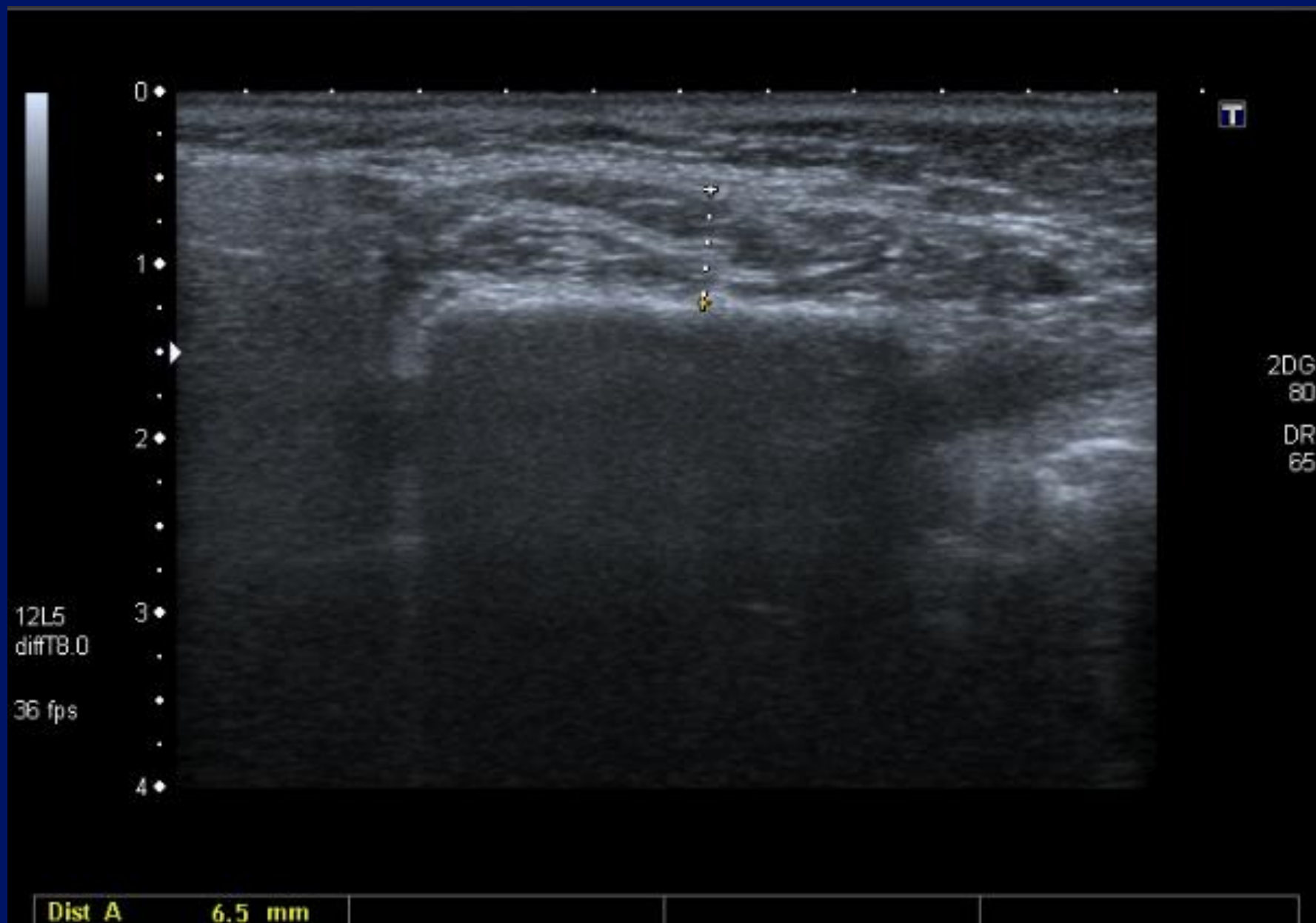
36 fps

A0 IP4







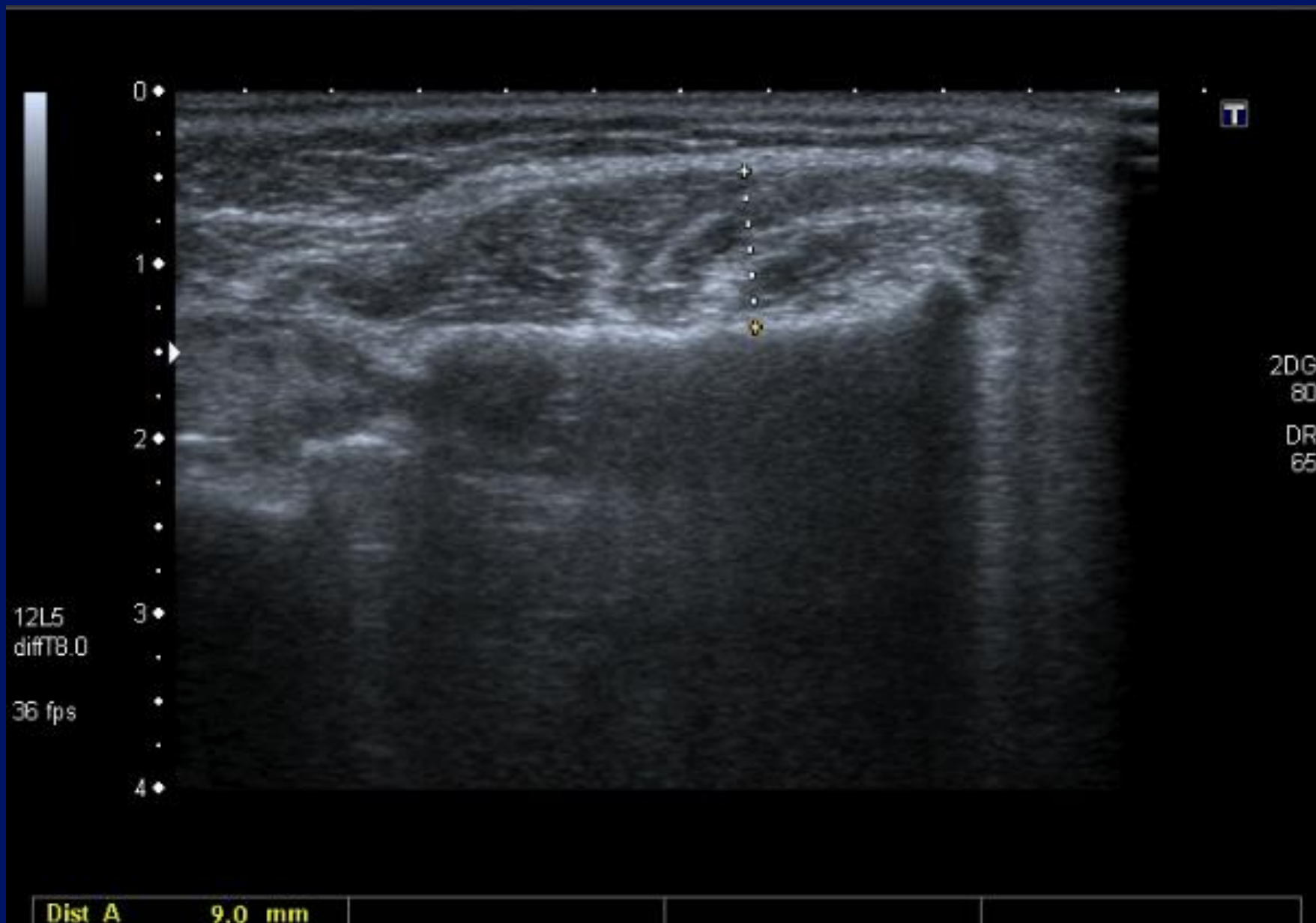


0  
1  
2  
3  
4

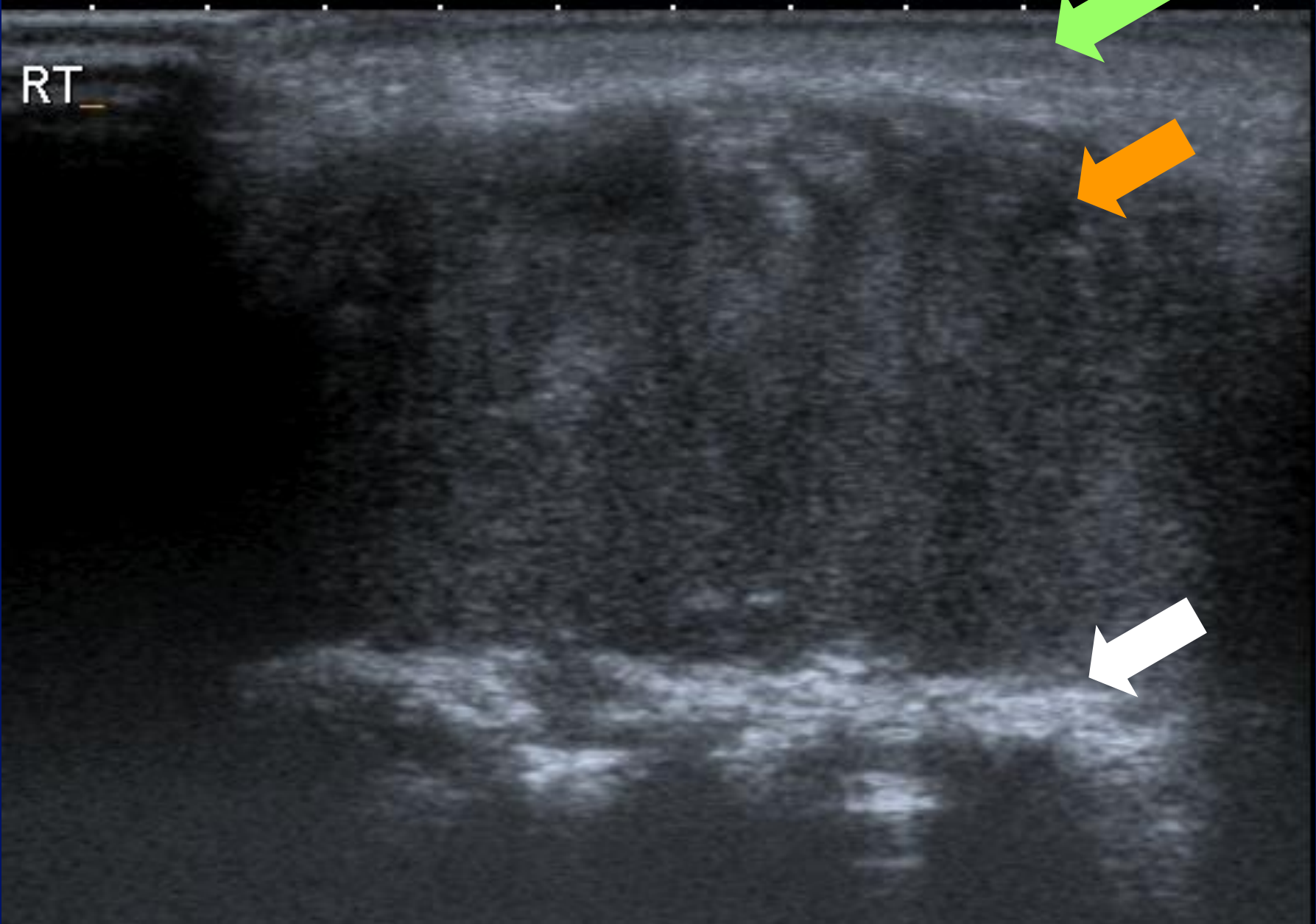
12L5  
diffT8.0  
36 fps

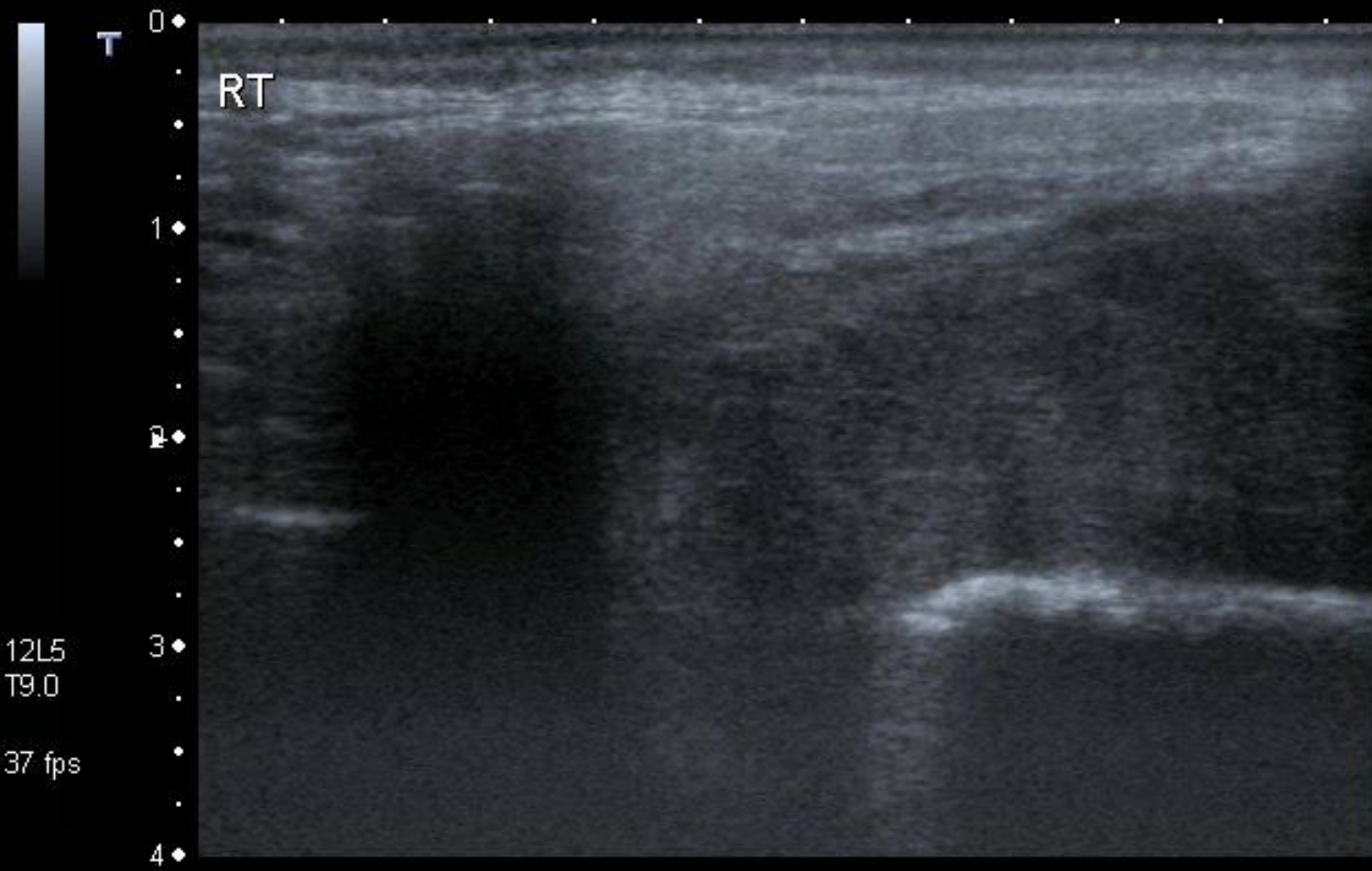
T

2DG  
80  
DR  
65



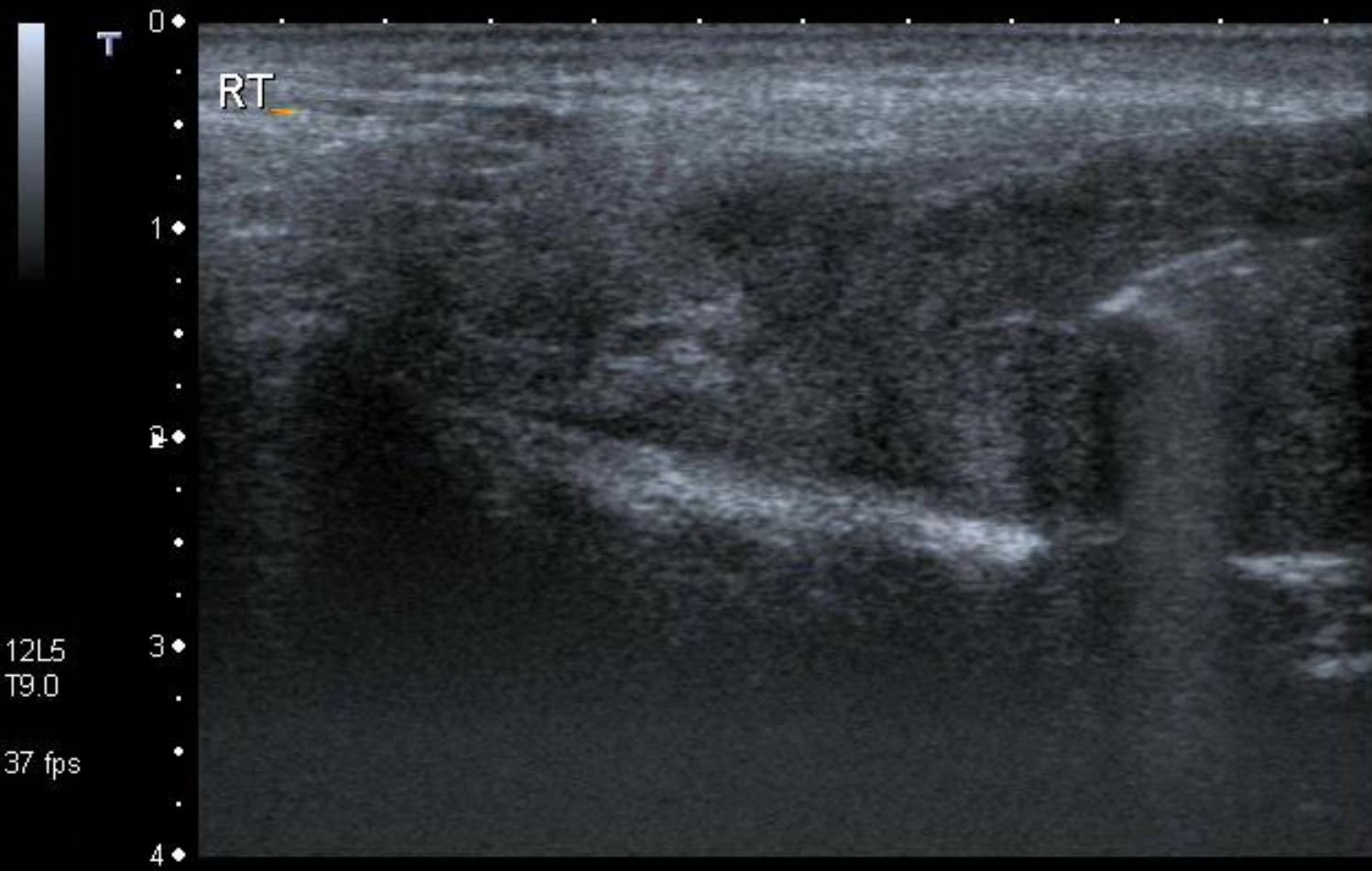
RT





MI: 1.6  
2DG  
85  
DR  
70

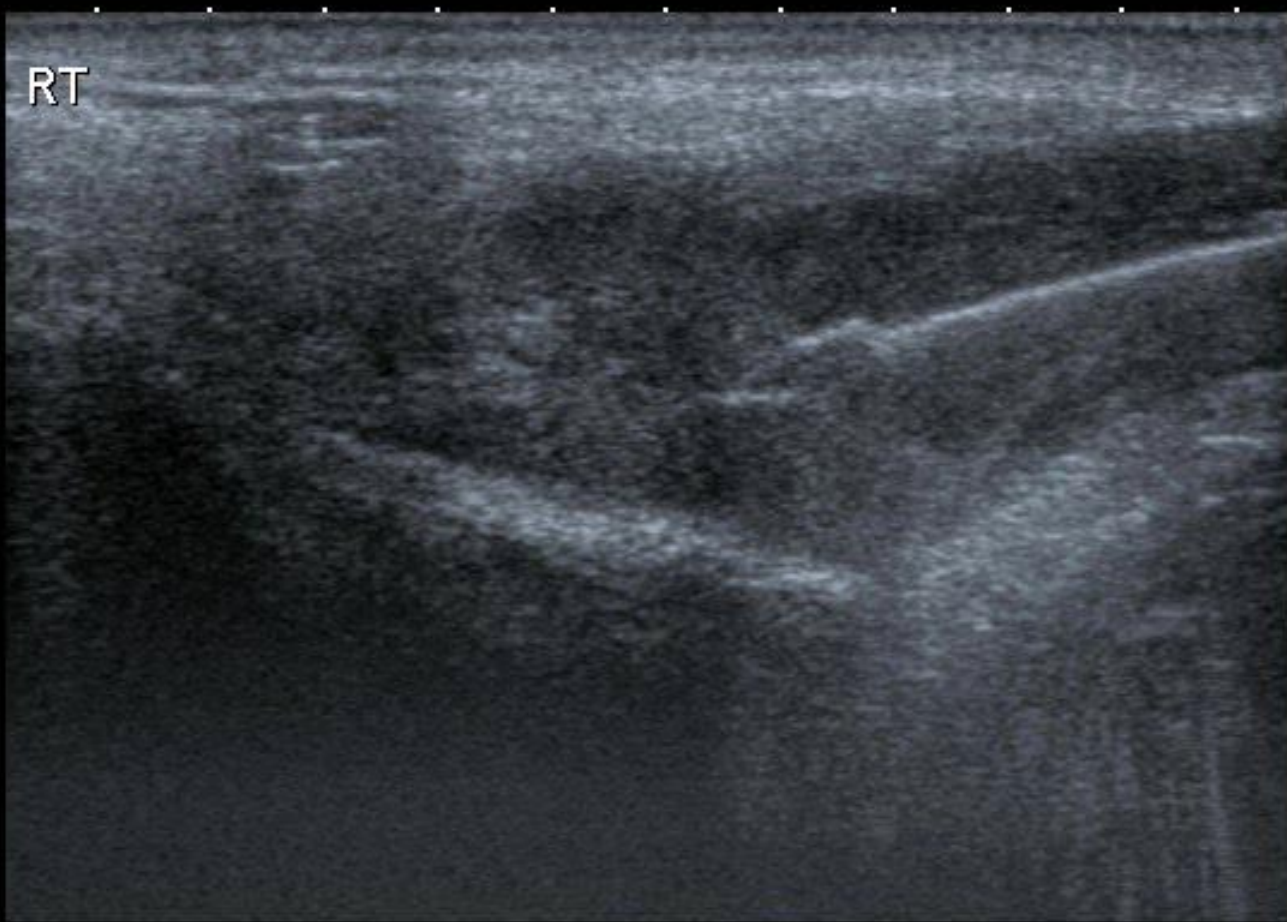






0  
1  
2  
3  
4

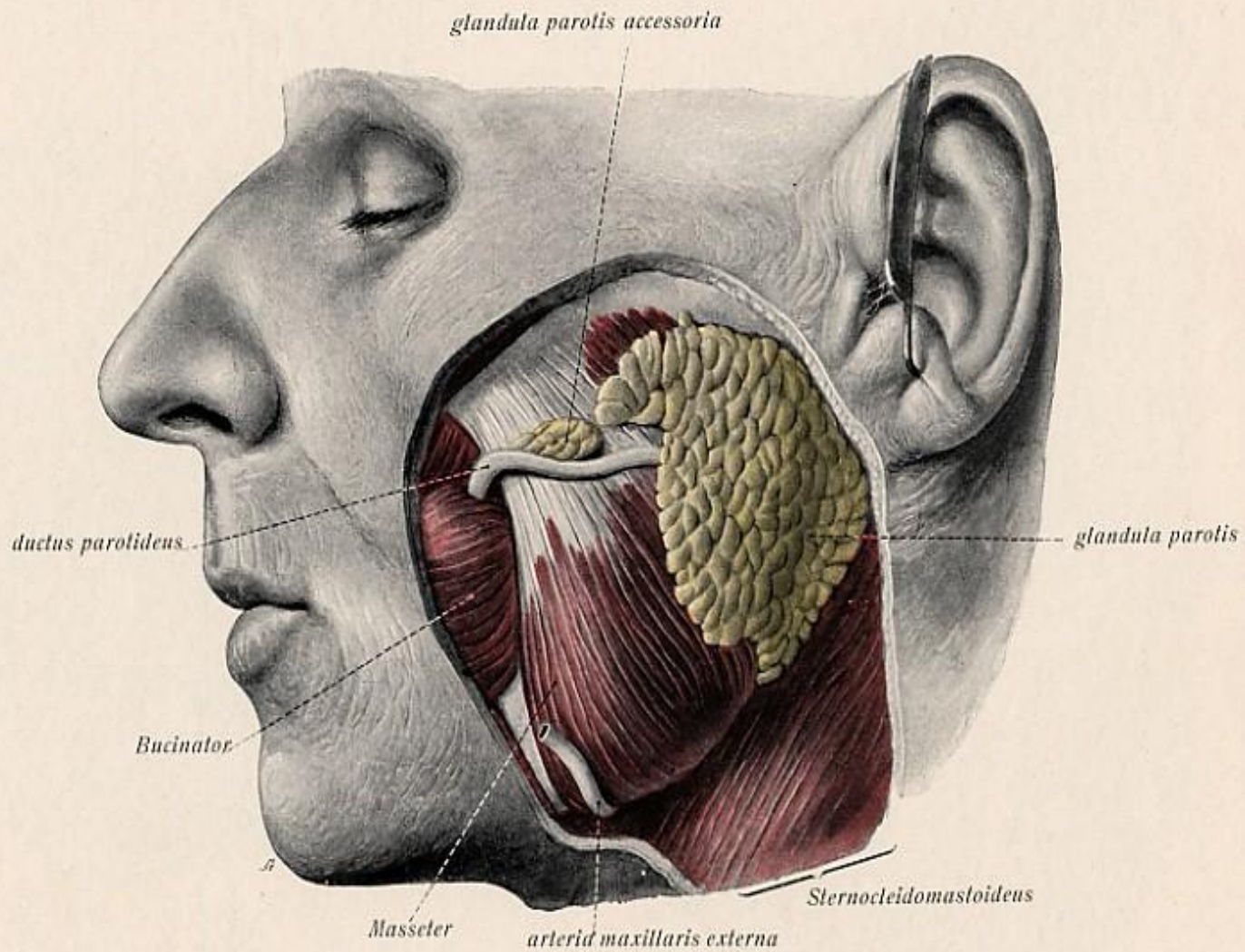
RT



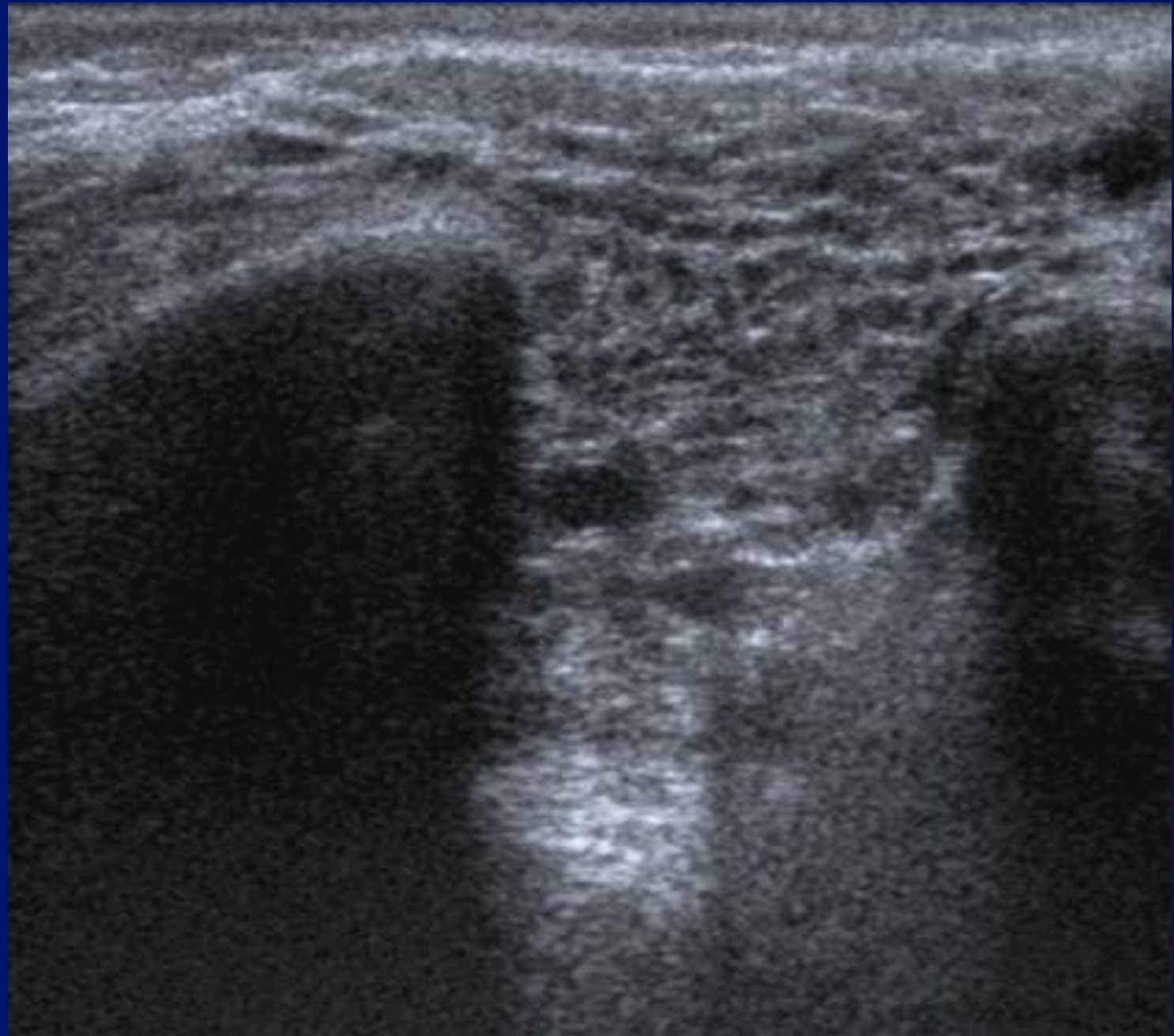
MI: 1.6  
2DG  
85  
DR  
70

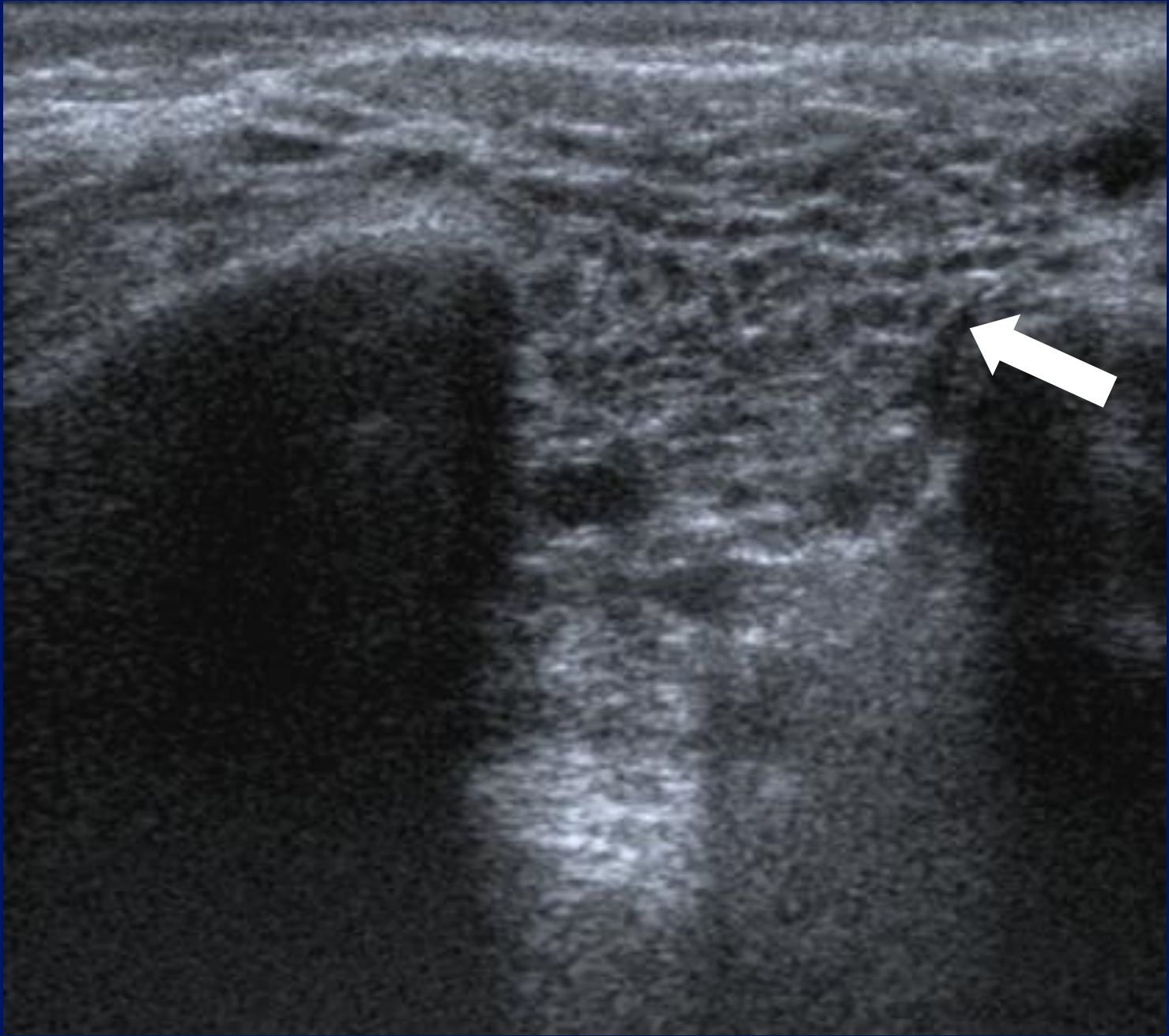
12L5  
T9.0  
37 fps





*Fig. 40.*

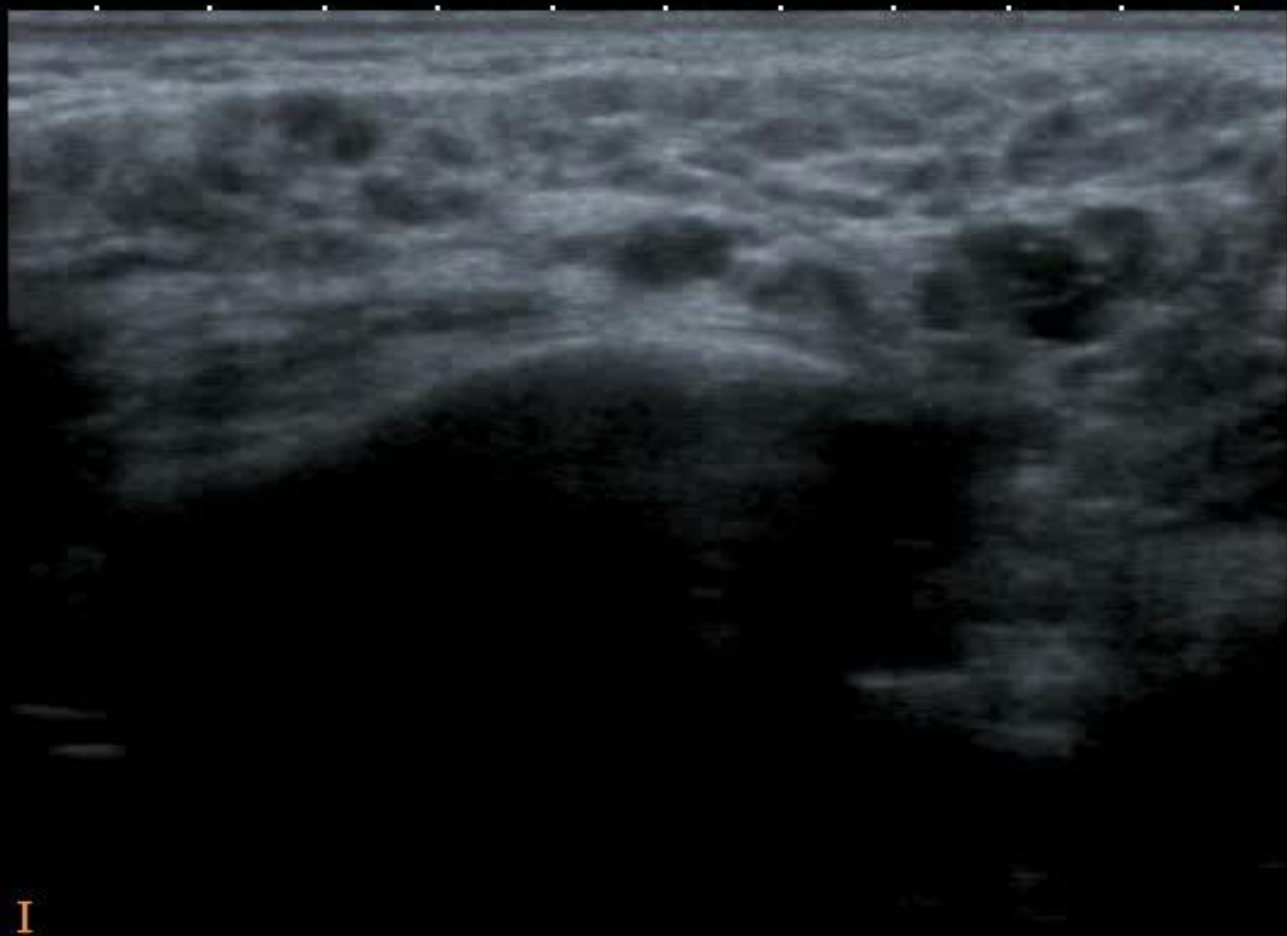




APure



0 ◆  
.  
.  
4 ◆  
.  
.  
2 ◆  
.  
.  
3 ◆  
.  
.  
4 ◆ I



MI: 1.6  
2DG  
88  
DR  
70

12L5  
T9.0

22 fps

# Salivary glands.

- Anatomy.
- Stones.
- Salivary tumours.
- Extra – salivary tumours.

